

Case Report



Terson's syndrome

Sharma R, Shrestha J K

B P Koirala Lion's Center for Ophthalmic Studies, IOM, Kathmandu

Abstract

Terson's syndrome is rarely encountered in ophthalmic practice. The ophthalmologists should be acquainted with the clinical features and methods of diagnosis of this syndrome. Here we report a middle-aged lady with altered sensorium, visual impairment and headache who was diagnosed as having Terson's syndrome after funduscopy and spinal tap. It was managed conservatively.

Key words: vitreous hemorrhage, subarachnoid hemorrhage

Introduction

More than 70 years ago, the French ophthalmologist Albert Terson described a vitreous hemorrhage that occurred as a direct consequence of spontaneous subarachnoid hemorrhage (Pfausler et al 1996). Both subarachnoid and subdural hemorrhages can cause substantial intracranial hypertension, which in turn may impede the venous outflow from the eye and lead to intraocular hemorrhage (Kuhn and Morris, 1998).

Case report

A 43-year-old lady attended the emergency with diffuse headache for 7 days associated with non-projectile vomiting, blurring of vision (left more than right) and altered sensorium for 7-8 hours. She did not report any flashes of light, floaters, colored halos or trauma. She was not a known diabetic or hypertensive and was not on any systemic or topical medication including hormonal contraceptives. She had no addiction to alcohol, cigarette smoking or drug use. The family history was non-contributory; her three children (youngest 19 years) were healthy and were born of normal pregnancies.

On examination at admission, Glasgow coma scale was E3V3M6 (12/15) with mild neck rigidity, although Kerning sign was absent. Her vital parameters were normal. Neuromuscular examination was normal with bilateral flexor plantar responses. Other systemic evaluations including that of the cardiovascular system were normal.

Her visual acuity in the right eye was 1/60 and that in the left eye was hand movements with no improvement on refraction. Extra-ocular movements were full in all gazes. Anterior segment evaluation revealed no abnormality. Pupils were 3 mm bilaterally, round, regular and reacting to both direct and consensual light reflexes. Vitreous in the right eye had 2 + haze while in the left eye, there was a dense vitreous hemorrhage. Fundus examination of the right eye showed a round pink optic disc with blurred margin, obliterated cup with mild venous tortuosity. There was around 2 DD sub-hyaloid hemorrhage around the macula with multiple superficial bleeding around major vascular arcades (Fig 1). Red fundal glow only was visible in the left eye (Fig 2). USG B scan showed minimal vitreous hemorrhage on the right side and dense vitreous hemorrhage in the left eye with flat retina bilaterally. Intraocular pressure (air puff Tonometer) was 14 and 16 mmHg respectively.

The CT scan of the head was normal. Subarachnoid

Received: 15.12.2008. Accepted: 27.12.2008
Correspondence and reprint requests to: Dr Ranjana Sharma
B P Koirala Lion's Center for Ophthalmic Studies
Email: ranjana_sharma22@yahoo.com
Tel: 00977-1-4720694

hemorrhage was diagnosed after lumbar puncture. Cerebral angiography revealed vasospasm in the basilar artery and no aneurysms or A-V malformation. Hematological investigation was normal.

The diagnosis of Terson syndrome with subarachnoid hemorrhage was made and conservative management with continuation of neurological management advised. The patient was discharged and was asked to follow up at the eye OPD after 3 weeks.

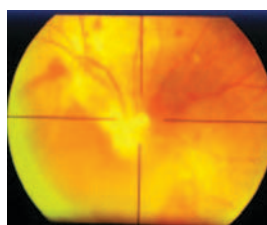


Fig 1. (Right Eye)

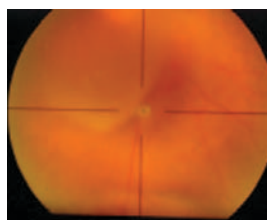


Fig 2. (Left Eye)

Discussion

The exact pathogenesis of this syndrome is still unknown; either type of intracranial bleed is followed by vitreous hemorrhage (Kuhn and Morris, 1998). Intraocular hemorrhage includes the development of subretinal, retinal, preretinal, subhyaloidal, or vitreal blood. Accumulation of blood at the macular area is a fairly common complication in Terson syndrome, further compromising visual recovery.

The classic presentation is in the subhyaloidal space. Reports have shown an incidence of 10-50% of intraocular hemorrhage with subarachnoid hemorrhage. This association is statistically associated with the severity of the subarachnoid hemorrhage based on the Hunt-Hess classification system of subarachnoid hemorrhages. The incidence of vitreous hemorrhage is much lower (3-13%). Papilloedema and unconsciousness are both positively correlated with Terson syndrome. Terson syndrome has been described most commonly in subarachnoid hemorrhages due to

ruptured cerebral aneurysm. Other reports include such causes as strangulation, trauma, tumor, and post surgical intracranial bleeding (Pfausler et al 1996; Richard, 2008).

The pathogenesis of Terson syndrome has been controversial. The earliest reports assumed that the intracerebral blood directly connected with the intraocular space through the lamina cribrosa. Electron microscopy of the optic nerve anatomy has not demonstrated a communication between the two spaces. In addition, pathological specimens have not shown any blood in the optic nerve sheath within 3 mm of the globe. Another mechanism suggests that a sudden rise in the venous pressure caused by the intracerebral bleeding is transmitted to the eye and results in intraocular bleeding. However, experimental studies have shown that the intravenous pressures are not high enough to create an intraocular hemorrhage. The sudden rise in intracranial pressure is probably the primary inciting event in Terson syndrome. Intracranial pressure is transmitted through the optic nerve sheath to the swollen optic nerve head, which occludes the retinal and choroidal anastomoses at the level of the lamina cribrosa. The elevated venous pressure generated in the retinal venous system is assumed to rupture the superficial retinal vessels, resulting in intraocular hemorrhages. The intraocular hemorrhage is usually bilateral and superficial to the retina. Intraretinal or subretinal hemorrhages have been reported but are less frequent. Preretinal hemorrhage can develop into vitreous hemorrhage weeks after the initial inciting event (Fahmy et al, 1973; Richard, 2008).

The intraocular hemorrhage may be difficult to diagnose immediately because the ophthalmologist is restricted from dilating the patient for neurologic monitoring. A decreased red reflex is helpful in evaluating a patient who is in coma, and B-scan ultrasound can further establish the extent of vitreous hemorrhage to rule out a retinal detachment if no view to the posterior pole is possible, particularly in the setting of trauma.

Bettina Pfausler et al (1996) prospectively studied sixty consecutive patients with spontaneous subarachnoid hemorrhage (SAH). Terson's syndrome was diagnosed in 10 (16.7%) of 60 patients and was associated with subarachnoid rebleeding in seven of 10. No correlation was found between anatomical localization of the

ruptured aneurysm and TS laterality (Pfausler et al 1996). Case fatality was nine (90%) of 10 in patients with TS compared to five (10%) of 50 in non-TS patients. It is concluded that TS is not infrequent (16.7%) in spontaneous SAH and has a poor prognosis, often heralding subarachnoid rebleeding (Pfausler et al 1996).

Spontaneously clearing vitreous hemorrhage or small intraocular hemorrhage is most common. Elevated head positioning with bed rest and avoidance of anticoagulation medications (eg, aspirin, nonsteroidal anti-inflammatory drugs [NSAIDs], warfarin) may be helpful. Resolution of symptoms may take months. One study demonstrated an average of 9 months for the clearance of such hemorrhages (Richard, 2008; Kuhn and Morris, 1998).

Three months appear to be a reasonable period of observation in adults to determine whether spontaneous vitreous clearing can be expected. Unless contraindicated because of the general condition, children should have even earlier surgery to possibly prevent amblyopia. In patients who elect not to undergo vitrectomy despite persisting vitreous opacities or who delay surgery, repeated visual testing and ultrasound examinations are recommended to detect developing retinal detachment. In a study of 30 patients with Terson syndrome, over 83% of patients achieved a long-term visual acuity better than 20/50 following observation (Garfinkle et al, 1992) or a vitrectomy. No statistical difference in final visual acuity was found between patients treated with observation or a vitrectomy (Weingeist et al, 1986; Richard, 2008).

Ophthalmic surgical intervention may be necessary to treat late complications (e.g., macular epiretinal membranes). Immediate vitrectomy for intraocular

hemorrhages is not recommended, except for patients with submacular hemorrhage, patients who are monocular with severe visual loss, or pediatric patients at risk for amblyopia (Kuhn and Morris, 1998; Richard, 2008; Racz et al, 1977).

Therefore, all patients with subarachnoid (and probably subdural) hemorrhage should undergo a dilated fundusoscopic examination, as the presence of vitreous hemorrhage has implication on the patient's general condition.

References

- Fahmy JA (1973). Fundal haemorrhages in ruptured intracranial aneurysms. II. Correlation with the clinical course. *Acta Ophthalmol (Copenh)* 51(3):299-304.
- Garfinkle AM, Danys IR, Nicole DA (1992). Terson's syndrome: a reversible cause of blindness following subarachnoid hemorrhage. *J Neurosurg* 76:766-771.
- Kuhn F, Morris R (1998). Results of Vitrectomy and the Significance of Vitreous hemorrhage in Patients with Subarachnoid Hemorrhage *Ophthalmology* 105:472-477.
- Pfausler B, Belcl R, Mohsenipour I, Schmutzhard E (1996). Terson's syndrome in spontaneous subarachnoid hemorrhage. *J Neurosurgery* 85:392-394.
- Racz P, Bobest M, Szilvássy (1977). Significance of fundal hemorrhage in predicting the state of the patient with ruptured intracranial aneurysm. *Ophthalmologica* 175:61-66.
- Richard J Ou (2008). Terson Syndrome; E medicine.
- Weingeist TA, Goldman EJ, Folk JC (1986). Terson's syndrome. *Clinicopathologic correlations. Ophthalmology* 11:1435-1442.