

Case Report

Post Traumatic calcinosis cutis of eyelid

Nidhi Sharma¹, Vinod Rana¹, Anjali Nagar¹

¹Department of Ophthalmology, Indira Gandhi ESI hospital, Jhilmil. New Delhi 110095

Introduction

Initially described by Virchow in 1855, Calcinosis cutis is an uncommon disorder characterized by an abnormal deposition of insoluble amorphous calcium salts under the epidermal layer of skin in various parts of body (Reiter N et al, 2011). This syndrome is divided into four types: dystrophic calcification, metastatic calcification, idiopathic calcification and iatrogenic calcification. The dystrophic type presents in damaged and devitalized tissue. Metastatic calcification presents in systemic diseases. Iatrogenic type is associated in many cases with intake of calcium containing medications. Idiopathic type occurs in absence of any detectable cause or tissue injury (Reiter N et al, 2011). Here we describe a rare case of post-traumatic calcinosis cutis of the eyelid.

Case

A 12 year old male child presented in the eye department of our hospital with complaint of a grayish mass on the lateral aspect of left upper eyelid for one year (Figure 1). A significant history of trauma one and a half year back with a pencil tip while playing with his friend was obtained. The trauma got neglected due to minor pain and no major treatment was undertaken at that time. There was no significant systemic or family history. On physical examination, child

was moderately built. No other masses were found in any other part of his body. There was no lymphadenopathy. On ocular examination, best corrected visual acuity was 6/6 for both eyes (Snellens chart). Anterior segment examination in right eye was within normal limits. In left eye, a grayish pigmentation was noted just below the eyebrow of around 4mm size which was not associated with redness or vascularisation. On palpation, a hard consistency was felt. The mass was non tender and non pulsatile. Rest of the examination of anterior and posterior segments was within normal limits. On the basis of history and examination, a provisional diagnosis of post traumatic left upper eyelid retained foreign body (most probably lead from pencil tip) was made. All routine haematological investigations including serum calcium and phosphorus were within normal limits. Excision of the mass was planned under local anaesthesia.

A superficial incision was made over the mass, but since it was deeper in the dermis so incision had to be extended (Figure 2). The nodule was removed en-masse. It was 7mm in size (Figure 3). The mass was sent for histopathological examination. Histopathological findings showed that the specimen was lined by stratified squamous epithelium. The underlying dermis showed a large area of calcification. The area was surrounded by fibrous tissue and few chronic inflammatory cells. All these features were suggestive of calcinosis cutis (Figure 4 a and b). There was no trace of any retained lead or pencil tip. It has been more than 6 months and no recurrence has been noted.

Financial Interest: Nil

Conflict of Interest: Nil

Received: 01.01.2019

Accepted: 10.05.2019

Corresponding author

Nidhi Sharma

E-mail: smilingnidhi6@gmail.com

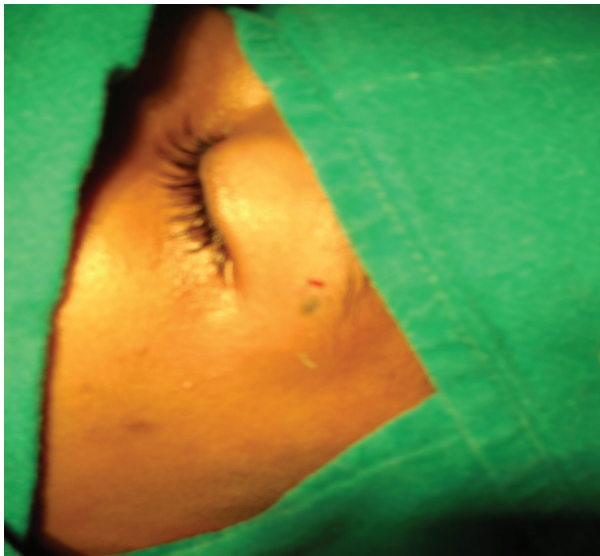


Figure 1: Per-op photo of the child. Arrow directed towards the mass.

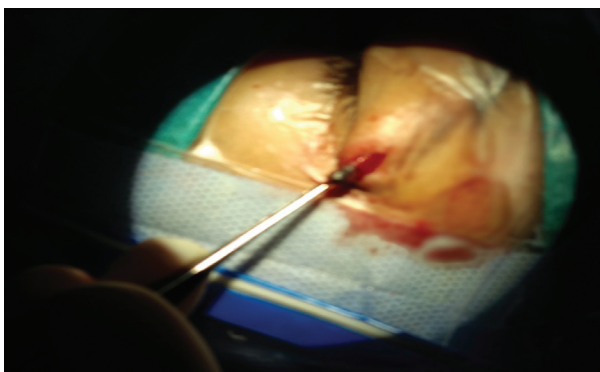


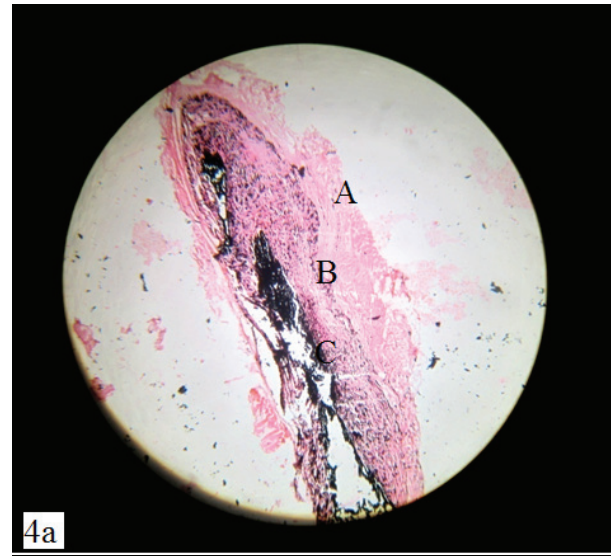
Figure 2: Intraoperative photograph showing that the mass was deep into the dermis.

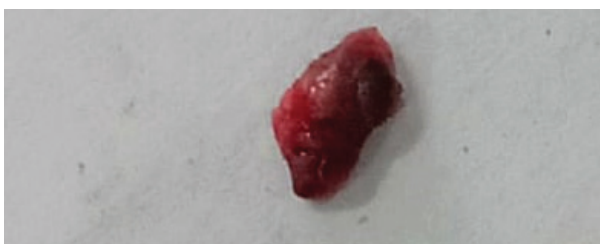

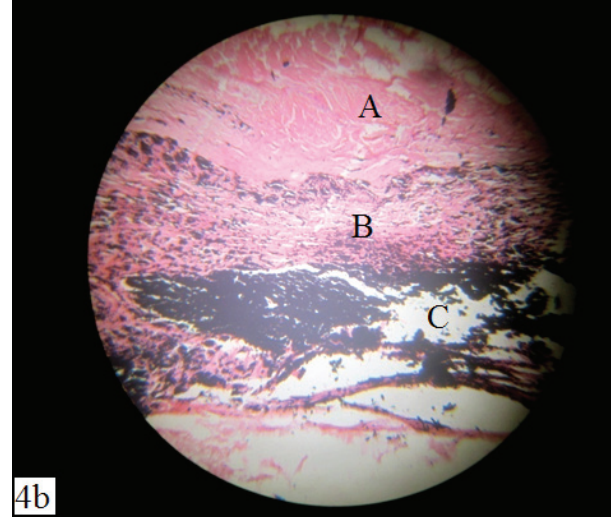
Figure 3: Mass as taken out en-masse (7 mm in size)

Discussion

To our knowledge and after thorough literature search, this is the first case report of a patient with post traumatic calcinosis cutis of the eyelid. Though there have been reports of



4a



4b

Figure 4 a and b: Histological findings show that the specimen is lined by stratified squamous epithelium (A). The underlying dermis shows a large area of calcification. The area is surrounded by fibrous tissue and few chronic inflammatory cells (B). Calcium deposits in the dermis can be seen (C). All these features are suggestive of calcinosis cutis.

idiopathic calcinosis cutis published previously in the literature. Samaka et al, 2015 reported a case of idiopathic calcinosis cutis in upper eyelid. Malik et al, 2011 reported a case with idiopathic bilateral subepidermal calcific

nodules in both eyelids. In idiopathic form it may mimic as molluscum (Nguyen J, 2008) or solitary verrucae nodule (Nico MM, 2001). Idiopathic calcinosis cutis of the tarsus of upper eyelid in a patient with Rheumatoid arthritis with normal serum calcium levels has been reported (Ikhyun Jun, 2011). It has been seen to have an association with disorders like dermatomyositis, systemic lupus erythematosus or systemic sclerosis (Boulman N, 2005). Eyelid, palpebral and bulbar calcifications also have been noted in patients with inflammation, systemic hyperparathyroidism and hyperphosphatemia (Ferry AP et al, 1990 and Ghanchi, F et al, 1996). In our case serum calcium and phosphate levels were within normal limits and no other cause could be found out except a clearly defined history of trauma at that exact point. Investigations should be done to exclude any underlying pathology especially in idiopathic cases.

Histological examination of the lesion reveals calcium deposits in the dermis in biopsy, which may or may not be surrounded by foreign body giant cell reaction. No standard treatment has been recommended for the removal or reduction of the lesion of calcinosis cutis (Boulman N et al, 2005 and Dutz J et al, 2005). Colchicine, warfarin, bisphosphonates, probenecid and diltiazem have been used with varying degree of success (Dutz J et al, 2005). Surgical excision is the treatment of choice (Ikhyun Jun et al, 2011).

Conclusion

This is the first case report of post-traumatic calcinosis cutis affecting the eyelid which is a rare site for involvement.

References

Boulman N, Slobodin G, Rozenbaum M et al (2005). Calcinosis in rheumatic diseases. *Semin Arthritis Rheum*; 34: 805–812. DOI: 10.1016/j.semarthrit.2005.01.016

Dutz J (2000). Treatment options for the cutaneous manifestations of systemic sclerosis. *Skin Therapy Lett*; 6: 3–5.

Ferry AP (1990). Subepidermal calcified nodules of the eyelid. *Am J Ophthalmol*; 109: 85–88. DOI: 10.1016/j.sjopt.2010.10.003

Ghanchi F, Ramsay A, Coupland S, et al (1996). Ocular tumoral calcinosis. A clinicopathologic study. *Arch Ophthalmol*; 114: 341–345. DOI:10.1001/archophth.1996.01100130337022

Ikhyun Jun, Sung Eun Kim, Sang Yeul Lee et al (2011). Calcinosis Cutis at the Tarsus of the Upper Eyelid. *KJO.*; 25 (6): 440–442. DOI: 10.3341/kjo.2011.25.6.440

Nguyen J, Jakobiec FA, Hanna E et al (2008). Subepidermal calcified nodule of the eyelid. *Ophthalmic Plast Reconstr Surg*: 494-5. DOI: 10.1016/j.sjopt.2010.10.003

Nico MM, Bergonese FN (2001). Subepidermal calcified nodule: report of two cases and review of the literature. *Paediatr Dermatol.*; 18 (3): 227-9. DOI: <https://doi.org/10.1046/j.1525-1470.2001.018003227.x>

Reiter N, El-Shabrawi L, Leinweber B et al (2011). Calcinosis cutis: Part I. Diagnostic pathway. *J Am Acad Dermatol*; 65: 1–14. DOI: <https://doi.org/10.1016/j.jaad.2010.08.038>

Salem Al Malik, Yasser H. Al Faky et al (2011). Bilateral subepidermal calcified nodules of the eyelid. *Saudi J Ophthalmology*; 25 (1): 81–83. <https://dx.doi.org/10.1016%2Fj.sjopt.2010.10.003>

Samaka RM, Al-Madhani A, Hussian SO (2015). Subepidermal calcified nodule in upper eyelid: A case report and review of the literature. *Oman J Ophthalmol*; 8: 56-58. DOI: 10.4103/0974-620X.14987