

Original Article

Management of Congenital Nasolacrimal Duct Obstruction with Probing. Experience in a Mexican Eye Center

Francisca Zuazo¹, Osiris Olvera-Morales¹, José L. Tovilla-Canales¹, Ángel Nava-Castañeda¹
¹Instituto de Oftalmología Fundación de Asistencia Privada Conde de Valenciana

Abstract

Objective: To describe the management, complications and prognosis of lacrimal probing in patients with congenital nasolacrimal duct obstruction (CNLDO).

Materials and Methods: Retrospective, observational and analytical study. We studied the prevalence, symptoms and signs, both before and after probing, in patients with CNLDO diagnosed between 2010 and 2017 at Instituto Fundación Conde de Valenciana.

Results: The prevalence at our hospital of congenital nasolacrimal duct obstruction in children less than 1 year of age was 16.1%. 71 eyes of 56 patients undergoing probing were analyzed. 61% of patients were male. The right eye was affected in 46.4%. The average age of diagnosis of CNLDO was 10.2±7.6 months. 84.5% consulted for excessive tearing and 73.2% because of eye discharge. On ophthalmological examination, 71.8% had increased tear meniscus and 45.1% had discharge from punctum when digital pressure was applied to the lacrimal sac. The average age at the time of probing was 14.1±8.4 months. Subsequent to the probing, only 21.1% reported presence of tearing and 5.6% reported ocular discharge, both with a statistically significant reduction ($p<0.05$ from pre-op). After probing, only 16.9% of eyes had increased tear meniscus and 11.3% presented discharge from punctum after pressure at the lacrimal sac. Both decreases were statistically significant ($p<0.05$). 2 eyes (2.82%) of 2 patients required a second probing to obtain full resolution.

Conclusion: Probing was successful in 76.1% of eyes. Success was observed even in patients over 2 years of age. There was a statistically significant decrease of both signs and symptoms of CNLDO with lacrimal probing.

Key words: probing; congenital nasolacrimal duct obstruction; dacryocystocele; dacryointubation; tear meniscus; tearing, prevalence.

Introduction

Symptomatic congenital nasolacrimal duct obstruction (CNLDO) is a common clinical

problem (Cakmak et al, 2010), which may occur in approximately 50% of newborns between week 1 and 12 (Hung et al, 2015). It is defined as a partial or complete occlusion of the nasolacrimal duct (González Pérez & Pérez, 2014). Symptoms and signs depend on the nature and anatomic level of obstruction. Commonly, the occlusion is distal, at the Hasner valve, between the nasolacrimal duct and nasal cavity (Mocan et al, 2015; González

Commercial interest: Nil

Financial interest: Nil

Received: 11.12.2018

Accepted: 10.03.2019

Corresponding author

Ángel Nava-Castañeda

Chimalpopoca #14 Colonia Obrera, México DF. CP 06800

Telephone: 52 + 5554421700

E-mail: angellusnc@hotmail.com

Pérez & Pérez, 2014; Cakmak et al, 2010).

It has been hypothesized that in most cases, the nasolacrimal duct is permeabilized during the first weeks of life, before tear production begins (Hung et al, 2015; Perveen et al, 2014). Symptomatic obstruction is characterized by the presence of epiphora and / or mucopurulent discharge during the first weeks of life (Hung et al, 2015) and varies from 1.75% to 20% in different countries (Macewen, 2006; Macewen & Young, 1991; Noda et al, 1991). The obstruction can occur in both eyes, but is usually unilateral (González Pérez & Pérez, 2014) due to occlusion at the Hasner valve. In these cases, the globe is usually not altered, although the presence of conjunctivitis can complicate the condition (Perveen et al, 2014).

Between 85-95% of children with uncomplicated congenital nasolacrimal duct obstruction, experience spontaneous resolution during their first year of life (Cakmak et al, 2010), or after massaging the lacrimal sac (Miller et al, 2014). Therefore, when to probe a CNLDO has remained controversial (Hung et al, 2015; Pediatric Eye Disease Investigator Group, 2008). Its high rate of spontaneous resolution before the first year of age would make early intervention unnecessary (Hung et al, 2015). However, an early probing can prevent complications such as acute dacryocystitis, periorbital cellulitis or possible inflammatory sequelae (Hung et al, 2015). On the other hand, a late intervention means keeping the child suffering symptoms for longer than necessary, increasing the risk of infection and subsequently needing more invasive procedures associated with a worse prognosis (Hung et al, 2015; Pediatric Eye Disease Investigator Group, 2008).

Another unresolved question is whether the probing is less successful if done late, probably due to prolonged inflammation of the lacrimal drainage system (Hung et al, 2015). In children under 18 months the reported success rates of

probing are around 77-97% (Casady et al, 2006; Robb, 1998; Stager et al, 1992). Some studies show decreasing success rates with increasing age of patients (Hung et al, 2015; Kashkouli et al, 2003; Mannor et al, 1999; Stager et al, 1992), while other studies do not show this phenomenon (Hung et al, 2015; Miller et al, 2014, Cha et al, 2010; Robb, 1998).

A possible explanation to this apparent decline of the success of probing may be due to the accumulation of more severe obstructions in older children, while the simplest resolve spontaneously. This may be a simple process of natural selection that leaves the most complex nasolacrimal duct obstruction to be treated later in life (Hung et al, 2015).

Most cases that remain symptomatic respond to a single probing. Only a small percentage of children require a repeat procedure or an intubation with silicon tubes (Cakmak et al, 2010). Whether to choose between probing or closed dacryointubation in patients with CNLDO remains a subject of debate, with no consensus on the choice of procedure given the high success rate of both techniques (Al-Faky et al, 2015). Some suggest the closed intubation with silicone tubes as the first procedure, although the lacrimal probing is easier to perform and with less complication (Al-Faky et al, 2012; Pediatric Eye Disease Investigator Group, 2008; Casady et al, 2006; Kashkouli, 2003; Mannor et al, 1999). That is why other authors pose lacrimal probing as the initial surgical management in congenital nasolacrimal duct obstruction (Mocan et al, 2015; Perveen et al, 2014), in which a metal probe is inserted to perforate Hasner valve and restore tear flow to the nasal cavity (Mocan et al, 2015). Thus, lacrimal intubation is reserved for cases where the probing fails or in patients with complicated lacrimal pathway as those with Down syndrome (Al-Faky et al, 2012).

The present study was conducted to describe the prevalence, management, complications

and prognosis of lacrimal probing, in patients with congenital nasolacrimal duct obstruction, between 2010 and 2017 at Instituto de Oftalmología, Fundación Conde de Valenciana.

Materials and Methods

Retrospective, analytical, observational and cross-sectional study. Records of patients diagnosed with congenital nasolacrimal duct obstruction were selected in the database, between 2010 and 2017.

Patients diagnosed CNLDO undergoing lacrimal probing of one or both eyes and who were refractory to conservative treatment with massage, were included. Patients with retaining lacrimal sac or congenital dacryocystocele, were also included.

We excluded patients with secondary tearing due to ocular surface disease, glaucoma or eyelid abnormality, patients with metabolic disorders or Down syndrome, craniofacial abnormalities, agenesis of puncta, and history of lacrimal system trauma or previous nasolacrimal surgery. Patients who had undergone previous probing, or with post operative follow up less than 3 months, or with incomplete files, were also excluded.

The diagnosis of congenital nasolacrimal duct obstruction was performed by clinical history of epiphora and / or secretion during the first 6 months of life and physical examination. Increased tear meniscus, purulent discharge, presence of a retaining lacrimal sac (diagnosed by tear or secretion reflux upon compression of the lacrimal sac) and delayed disappearance of fluorescein, were considered clinical signs of this disease.

Probing technique:

Patients underwent lacrimal probing, with informed consent of the parents, under general inhaled anesthesia, being monitored in the operating room. Dilation of upper and lower puncta (Figure 1A) and lacrimal

permeabilization were performed by passing a metal Bowman type probe (Figure 1B) in increasing diameters until nasal cavity was reached via upper and lower canaliculi. Lacrimal system was considered permeabilized by contacting the Bowman probe with a metal grooved director in the respective nasal cavity (Figure 2). After the procedure, topical antibiotic and corticosteroid were prescribed for 2 weeks in tapering doses, along with nasal vasoconstrictor for 5 days.

Statistical analysis

Descriptive statistics were performed for demographic variables. To compare previous and post probing signs and symptoms, the McNemar test was performed. A statistically significant difference was considered if $p < 0.05$ was obtained. SPSS program, version 22.0 software (Chicago, IL) was used.

Results

13,402 children aged 3 years or less, were examined between 2010 and 2017 at our Institution. Of these, 1,454 patients had diagnosis of congenital nasolacrimal duct obstruction during the study period, yielding a prevalence of 10.8%. Considering only children under one year of age, the prevalence of CNLDO was 16.1% at our Hospital.

Of patients with congenital nasolacrimal duct obstruction, 71 eyes of 56 patients underwent lacrimal probing, 85% of the eyes with CNLDO were found in patients of less than 24 months of age (Graph 1). Sixteen patients had bilateral disease.

Male predominance was observed, with 61% of patients.

In affected patients, 46.4% were of the right eye.

The average age of diagnosis of congenital nasolacrimal duct obstruction was 10.2 ± 7.6 months, ranging between 10 days old and 3 years old.

The average age at the time of probing was 14.1 ± 8.4 months, ranging from 15 days old to 3 years and 3 months old.

Symptoms: Prior to probing, 84.5% presented with tearing and 73.2% with ocular discharge. After probing, 21.1% reported presence of tearing and only 5.6% reported ocular discharge. Both symptoms showed a statistically significant ($p < 0.05$) post-probing decreases (Table 1).

Signs: On physical examination, 71.8% had increased tear meniscus and 45.1% had a retaining lacrimal sac prior to probing. Following the procedure, 16.9% of eyes had increased tear meniscus and 11.3% had a retaining lacrimal sac. Both signs showed a statistically significant reduction ($p < 0.05$) after the probing (Table 2).

Two eyes of 2 patients had persistent disease post probing that did not resolved with further massage and were submitted to a second probing, obtaining full resolution of signs and symptoms after the second intervention.

Given persistent symptoms after the probing, 5 eyes underwent closed lacrimal intubation with silicone tubes for 5-6 months. All patients had clinical resolution after the intubation.

Nine eyes had a dacryocystocele, eight of which were successfully resolved after lacrimal probing. Only one eye with dacryocystocele required a second probing to obtain resolution.

In patients undergoing probing, 11 eyes belonged to patients older than 24 months, ranging between 24 and 39 months. Of these, only 2 eyes (18%) did not obtain resolution of clinical signs or symptoms after lacrimal probing, requiring intubation with silicone tubes

Of the 16 patients with bilateral congenital nasolacrimal duct obstruction, 9 eyes (28%) of 7 patients had persistent symptoms after a single lacrimal probing, requiring intubation with silicone tube.

Of the 71 eyes with CNLDO diagnosis, 71.6% had resolution of symptoms with a single lacrimal probing.

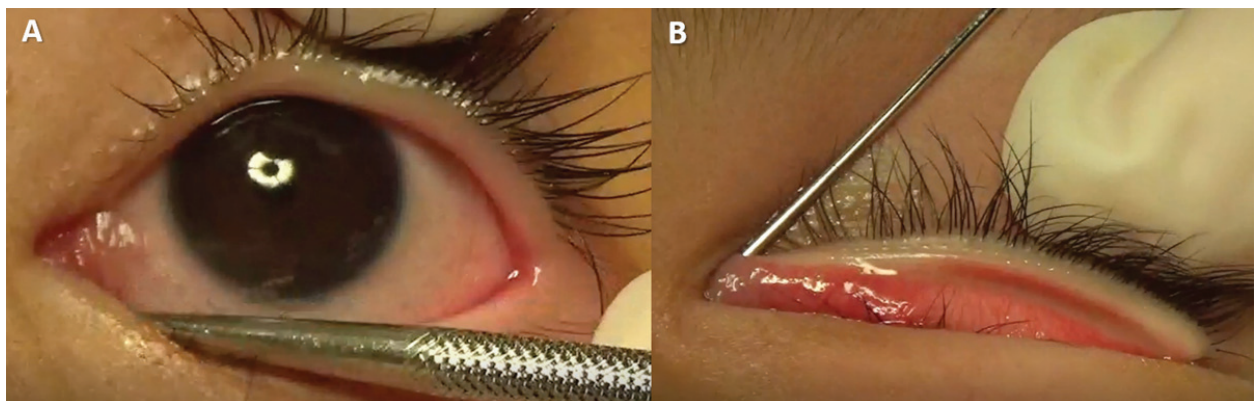


Figure 1: A: Lacrimal punctum dilation with patient in the operating room under general inhaled anesthesia. **B:** Permeabilization of the lacrimal system with a Bowman metal probe.

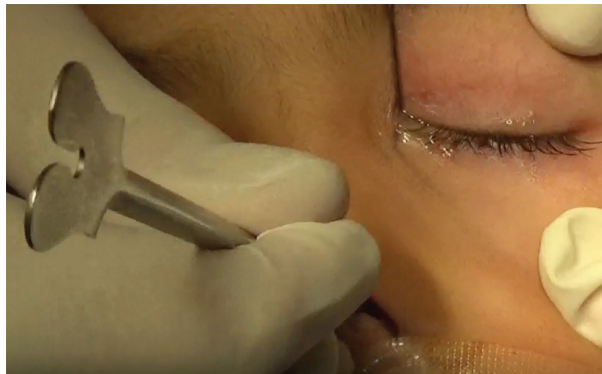

Figure 2: Lacrimal probing with Bowman probe. Permeability is checked by contacting it with grooved director introduced in nasal cavity.

Table 1: Symptoms

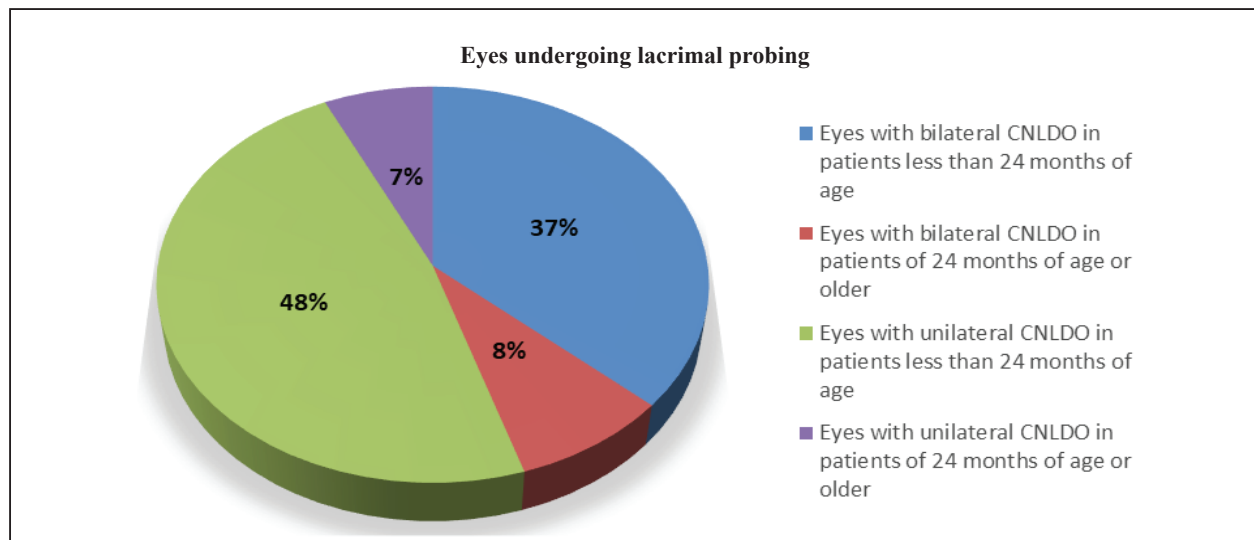
	Pre Probing	Post Probing
Tearing	84.5 %	21.1 %
Secretion	73.2 %	5.6 %

p < 0.05

Table 2: Physical Exam

	Pre Probing	Post Probing
Increased tear meniscus	71.8 %	16.9 %
Retaining sac	45.1 %	11.3 %

p < 0.05



Discussion

In our series, we obtained a prevalence of congenital nasolacrimal duct obstruction in children under 1 year of 16.1%, similar to that reported in other studies (Macewen, 2006; Noda et al, 1991; Macewen & Young, 1991).

Most patients diagnosed with CNLDO were male, as seen in other study. (Dhiman et al, 2017).

Lacrimal probing was successful in 76.1% of eyes. This success rate is comparable with other publications that found 76.2% of success (Serin et al, 2013). It is also comparable to the 75% (Miller et al, 2014) and is less than

the 82% (Cha et al, 2010) success of lacrimal probing performed under topical anesthesia in the office. While probing in the office is effective, despite the topical anesthetic, it is associated with increased parental concern for the inconvenience suffered by the child and potential psychological side effects that could result from the use of restraint (Miller et al 2014).

In our study, all patients underwent lacrimal probing under inhalation sedation in the operating room. In this way, we try to reduce the potential risk of trauma to the lacrimal structures and try to reduce the apprehension of both parents and the patient.

Success rates of lacrimal probing reported under general anesthesia, are greater than those found in doing the procedure under topical anesthesia in the office (Pediatric Eye Disease Investigator Group, 2008). Perhaps, it is because in the office is a procedure with less chance of repetition, for example, the probe only passes once. Studies show success rates of probes under general anesthesia 76.2% (Serin et al, 2013), 84.8% (Mocan et al, 2015), 80% (Pediatric Eye Disease Investigator Group, 2008).

Procedure success was evidenced by the improvement of symptoms such as tearing and eye discharge, and the improvement of clinical signs, such as increased tear meniscus and decreased presence of retaining lacrimal sac. Both symptoms and signs presented a statistically significant decrease after the probing, which has also been similarly shown by other studies (González Pérez & Pérez Pérez, 2014).

Despite the success of this procedure, in older patients it is a matter of debate. However, multiple studies have reported good rates of success of the probing and irrigation procedure independent of the patient's age (Al-Faky et al, 2015; González Pérez & Pérez Pérez, 2014; Pediatric Eye Disease Investigator Group, 2008; Robb, 1998; Kushner, 1998).

In our study we found no decrease in the percentage of success in probing patients over 2 years of age. In patients less than 24 months undergoing lacrimal probing, the success rate was 75%. In patients probed from 24 months of age, the success was 82%, this being greater than some studies which report a 79% success (Pediatric Eye Disease Investigator Group, 2008) and slightly lower than the 84.5% (Pediatric Eye Disease Investigator Group, 2008; Kashkouli et al, 2002) and 89% (Pediatric Eye Disease Investigator Group, 2008; Kashkouli, et al, 2003) reported by other studies. Probably the increased success rate of

probing we found in patients with 24 months of age or older, is due to the small number of patients treated with probing from 24 months of age.

We found a slightly lower success rate (72%) in the probing of patients with bilateral congenital nasolacrimal duct obstruction. This may be because the bilateral involvement could be a marker of more significant anatomical or physiological variations in nasolacrimal duct or tear pump mechanism, which can be more difficult to solve with probing (Al-Faky et al, 2015; Pediatric Eye Disease Investigator Group, 2008). Similarly, these patients may have allergic rhinitis, a condition that is not resolved with this procedure (Pediatric Eye Disease Investigator Group, 2008).

One limitation of this study is its retrospective design. The indication for probing or lacrimal intubation with silicone tubes was not randomized, but chosen at the discretion of the treating physician. On the other hand, only 11 eyes correspond to patients with 24 or more months of age, which is a small number for a meaningful comparison. However, this study shows a high success rate of lacrimal probing in patients with congenital nasolacrimal duct obstruction. Since this is a procedure without the need of general intravenous anesthesia, and is surgically easier and with fewer complications than lacrimal intubation, it should be considered as the primary interventional procedure for patients with CNLDO refractory to conservative treatment.

Conclusions

Lacrimal system probing is presented as an effective alternative, with excellent success rates in patients diagnosed with congenital nasolacrimal duct obstruction refractory to conservative treatment.

References

Al-Faky YH, Al-Sobaie N, Mousa A, Al-Odan H, Al-Huthail R, Osman E,

Al-Mosallam AR (2012). Evaluation of treatment modalities and prognostic factors in children with congenital nasolacrimal duct obstruction. *Journal of the American Association for Pediatric Ophthalmology and Strabismus*;16(1):53-7. DOI: <https://doi.org/10.1016/j.jaapos.2011.07.020>

Al-Faky YH, Mousa A, Kalantan H, Al-Otaibi A, Alodan H, Alsuhaibani AH (2015). A prospective, randomized comparison of probing versus bicanalicular silastic intubation for congenital nasolacrimal duct obstruction. *British Journal of Ophthalmology*;99(2):246-50. DOI: <http://dx.doi.org/10.1136/bjophthalmol-2014-305376>

Cakmak SS, Yildirim M, Sakalar YB, Keklikci U, Alakus F (2010). Is it necessary to accompany probing with endoscopy in cases of congenital nasolacrimal canal obstruction? *International Journal of Pediatric Otorhinolaryngology*;74(9):1013-5. DOI: <https://doi.org/10.1016/j.ijporl.2010.05.028>

Casady DR, Meyer DR, Simon JW, Stasior GO, Zabal-Ratner JL (2006). Stepwise treatment paradigm for congenital nasolacrimal duct obstruction. *Ophthalmic Plastic & Reconstructive Surgery*; 22:243-7. DOI: [10.1097/01.iop.0000225750.25592.7f](https://doi.org/10.1097/01.iop.0000225750.25592.7f)

Cha DS, Lee H, Park MS, Lee JM, Baek SH (2010). Clinical outcomes of initial and repeated nasolacrimal duct office-based probing for congenital nasolacrimal duct obstruction. *Korean Journal of Ophthalmology*; 24:261-6. DOI: <https://doi.org/10.3341/kjo.2010.24.5.261>

Dhiman R, Chawla B, Chandra M, Bajaj MS, Pushker N (2017). Clinical profile of the patients with pediatric epiphora in a tertiary eye care center. *Indian Journal of Ophthalmology*; 65(1):2-6. DOI: [10.4103/0301-4738.202306](https://doi.org/10.4103/0301-4738.202306)

González Pérez JV, Pérez JF (2014). Sondaje de vía lagrimal después

del año de edad para el tratamiento de la dacriostenosis congénita. *Revista Mexicana de Oftalmología*;88(2):61-6. DOI: <https://doi.org/10.1016/j.mexoft.2013.10.003>

Hung CH, Chen YC, Lin SL, Chen WL (2015). Nasolacrimal duct probing under topical anesthesia for congenital nasolacrimal duct obstruction in Taiwan. *Pediatrics and Neonatology*;56(6):402-7. DOI: <https://doi.org/10.1016/j.pedneo.2015.04.001>

Kashkouli MB, Kassae A, Tabatabaee Z (2002). Initial nasolacrimal duct probing in children under age 5: cure rate and factors affecting success. *Journal of the American Association for Pediatric Ophthalmology and Strabismus*; 6:360-3. DOI: <https://doi.org/10.1067/mpa.2002.129041>

Kashkouli MB, Beigi B, Parvaresh MM, Kassae A, Tabatabaee Z (2003). Late and very late initial probing for congenital nasolacrimal duct obstruction: what is the cause of failure? *British Journal of Ophthalmology*; 87:1151-3. Available at: <https://www.ncbi.nlm.nih.gov/pubmed/12928286>

Kushner BJ (1998). The management of nasolacrimal duct obstruction in children between 18 months and 4 years old. *Journal of the American Association for Pediatric Ophthalmology and Strabismus*; 2:57-60. Available at: <https://www.ncbi.nlm.nih.gov/pubmed/?term=10532369>

Macewen CJ, Young JD (1991). Epiphora during the first year of life. *Eye*; 5:596-600. DOI: <https://doi.org/10.1038/eye.1991.103>

Macewen CJ (2006). Congenital nasolacrimal duct obstruction. *Comprehensive Ophthalmology Update*;7(2):79-87. Available at: <https://www.ncbi.nlm.nih.gov/pubmed/16709344>

Mannor GE, Rose GE, Frimpong-Ansah K, Ezra E (1999). Factors affecting the success of nasolacrimal duct probing for



congenital nasolacrimal duct obstruction. *American Journal of Ophthalmology*; 127:616-7. Available at: <https://www.ncbi.nlm.nih.gov/pubmed/10334364>

Miller AM, Chandler DL, Repka MX, Hoover DL, Lee KA, Melia M, et al (2014). Pediatric Eye Disease Investigator Group. Office probing for treatment of nasolacrimal duct obstruction in infants. *Journal of the American Association for Pediatric Ophthalmology and Strabismus*; 18(1):26-30. DOI: <https://doi.org/10.1016/j.jaapos.2013.10.016>

Mocan MC, GulmezSevim D, Kocabeyoglu S, Irkec M (2015). Prognostic value of metal-metal contact during nasolacrimal duct probing. *Canadian Journal of Ophthalmology*; 50(4):314-7. DOI: <https://doi.org/10.1016/j.jcjo.2015.04.009>

Noda S, Hayasaka S, Setogawa T (1991). Congenital nasolacrimal duct obstruction in Japanese infants: its incidence and treatment with massage. *Journal of Pediatric Ophthalmology and Strabismus*; 28(1):20-2. Available at: <https://www.ncbi.nlm.nih.gov/pubmed/2019953>

Pediatric Eye Disease Investigator Group, Repka MX, Chandler DL, Beck RW,

Crouch ER 3rd, Donahue S, Holmes JM, et al (2008). Primary treatment of nasolacrimal duct obstruction with probing in children less than four years old. *Ophthalmology*; 115(3):577-84. DOI: <https://doi.org/10.1016/j.ophtha.2007.07.030>

Perveen S, Sufi AR, Rashid S, Khan A (2014). Success rate of probing for congenital nasolacrimal duct obstruction at various ages. *Journal of Ophthalmic & Vision Research*; 9(1):60-9. Available at: <https://www.ncbi.nlm.nih.gov/pmc/articles/PMC4074476/>

Robb RM (1998). Success rates of nasolacrimal duct probing at time intervals after 1 year of age. *Ophthalmology*; 105:1307-10. DOI: [https://doi.org/10.1016/S0161-6420\(98\)97038-5](https://doi.org/10.1016/S0161-6420(98)97038-5)

Serin D, Buttanri IB, Sevim MS, Buttanri B (2013). Primary probing for congenital nasolacrimal duct obstruction with manually curved Bowman probes. *Clinical Ophthalmology*; 7:109-12. DOI: <https://doi.org/10.2147/OPHTH.S39926>

Stager D, Baker JD, Frey T, Weakley Jr DR, Birch EE (1992). Office probing of congenital nasolacrimal duct obstruction. *Ophthalmic Surgery*; 23:482-4. Available at: <https://www.ncbi.nlm.nih.gov/pubmed/1407947>