

Case Report

Schnyder Corneal Dystrophy: A Rare Case Report

Bengi Ece Kurtul¹, Ahmet Elbeyli¹, Deniz Ozarslan Ozcan¹, Sait Coskun Ozcan¹,
Abdulkerim Karaaslan¹

¹Department of Ophthalmology, Mustafa Kemal University Tayfur Ata Sökmen Faculty of
Medicine, Hatay, Turkey

Abstract

Introduction: Schnyder corneal dystrophy (SCD) is a rare, autosomal dominant, anterior stromal dystrophy described as progressive bilateral corneal opacification due to abnormal accumulation of cholesterol and phospholipids in the cornea. The clinical signs can change as the patient ages. SCD with different presentations may actually be misdiagnosed. Early diagnosis would help to rule out other potentially sight threatening or treatable conditions like infectious keratitis or drug toxicity.

Case: We present a case of a 34-year-old Syrian male patient, came to our clinic for bilateral decreased visual acuity for 5 years. His visual acuity was 0.15 in both eyes. Slitlamp examination revealed corneal arcus or disk-like lesion and polychromatic crystalline depositions in both eyes in subepithelial and the anterior 1/3 of the stroma. The mild onset of arcus lipoides was also seen. Central corneal thickness results were 507 μm in the right eye and 503 μm in the left eye. A diagnosis of Schnyder corneal dystrophy was thought based on clinical presentation and coexistence dyslipidemia of the patient.

Conclusion: Ophthalmologists should keep in mind SCD and its associated systemic findings that need to be evaluated and managed properly.

Key words: Anterior stroma, Cornea, Dyslipidemia, Schnyder dystrophy.

Introduction

Schnyder corneal dystrophy (SCD) is a rare corneal dystrophy described as abnormally increased deposition of cholesterol and phospholipids in the cornea gives rise to clouding and progressive impaired vision.

(Weiss JS and Khemichian AJ, 2011; Köksal M et al, 2004; Rittenbach TL, 2013; Weiss JS, 2009; Zemba M et al, 2018; Evans CJ et al, 2018) SCD is inherited as an autosomal dominant affecting both sexes with equal probability. Van Went and Wibaut first described crystalline dystrophy in the Dutch literature in 1924, and it was delineated further by Schnyder in the Swiss literature in 1929. (Weiss JS, 2009)

It has varied appearances and may actually be diagnosed incorrectly. The clinical findings alter as the patient ages leading a decrease in vision, which may necessitate referral for phototherapeutic keratectomy, penetrating keratoplasty or deep anterior lamellar

Financial Interest: Nil

Conflict of Interest: Nil

Received: 28.10.2019

Accepted: 29.12.2019

Corresponding author

Bengi Ece Kurtul, MD

Mustafa Kemal University Tayfur Ata Sökmen Faculty of

Medicine, Hatay, Turkey

Phone: 00905062358670

Fax: 903262213320

E-mail: becekurtul@yahoo.com

keratoplasty. The patient's systemic signs that correlate with the dystrophy need to be considered and managed correctly.

Case Report

A case of a 34-year-old Syrian male patient, came to our clinic for bilateral decreased visual acuity for 5 years. His visual acuity was 0.15 in both eyes. Slit lamp examination revealed arcus or disk-like lesion and polychromatic crystalline depositions in both eyes in the subepithelium and the anterior 1/3 of the stroma. The beginning of arcus lipoides was seen. The corneal epithelium was intact, fluorescein staining showed no lesion. There was no family history. Anterior segments fotos of the patient were taken (Figure 1: A- B). Dynamic corneal response analysis (Oculus Corvis ST) was also performed to the patient. Central corneal thickness results were 507 μm in the right eye and 503 μm in the left eye. Corrected intraocular pressure values were 16.9 mmHg and 16.2 mmHg in right and left eye respectively. Average corneal densitometry levels were 45.4 and 37.4 in right and left eye respectively (Figure 2: A- B). Kmax levels were and 54.9 D in right eye and 52.0 D in left eye measured with a Pentacam - Oculus-Germany (Figure 3: A-B). Corneal sensitivity was mildly reduced in both eyes. Fundus examination was within normal limits. Our

patient had no history of infection, trauma, using fluoroquinolones or a systemic disorder. But we found hypertriglyceridemia in his lipid profile. Informed consent was taken from the patient to report this case.

A diagnosis of SCD was thought based on clinical presentation and coexistence dyslipidemia of the patient. Confocal microscopy to support our diagnosis and genetic testing for the UBIAD1 mutation as known in this disease were not performed because we have not this device in our clinic and this genetic test was not performed in our hospital.

The patient was new to the hospital, so there was no history of laboratory work previously performed. A lipid panel was ordered and showed total cholesterol of 159 mg/dL (normal <200 mg/dL) and triglycerides of 262 mg/dL (normal <150 mg/dL). The level of high-density lipoprotein was 28 mg/dL (normal 35-55 mg/dL) and low-density lipoprotein was 100 mg/dL (normal <100 mg/dL). We found hypertriglyceridemia in this panel. At this time we offered him for a cardiological examination to control lipids.

The patient was made aware that a corneal transplant might be required in the upcoming period to improve best-corrected visual acuity and overall quality of vision. We advised to use of lubrication drops as needed for comfort.




Figure 1-A: Central and paracentral subepithelial and stromal, arcus or disc like lesions in patient's right eye. **B:** Central and paracentral subepithelial and stromal crystals in patient's left eye.

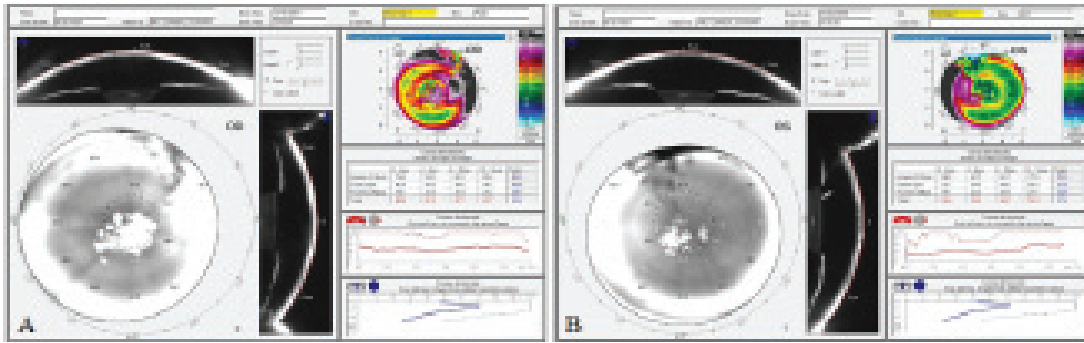


Figure 2: Dynamic corneal response analysis (A: Corneal densitometry of right eye. B: Corneal densitometry of left eye).

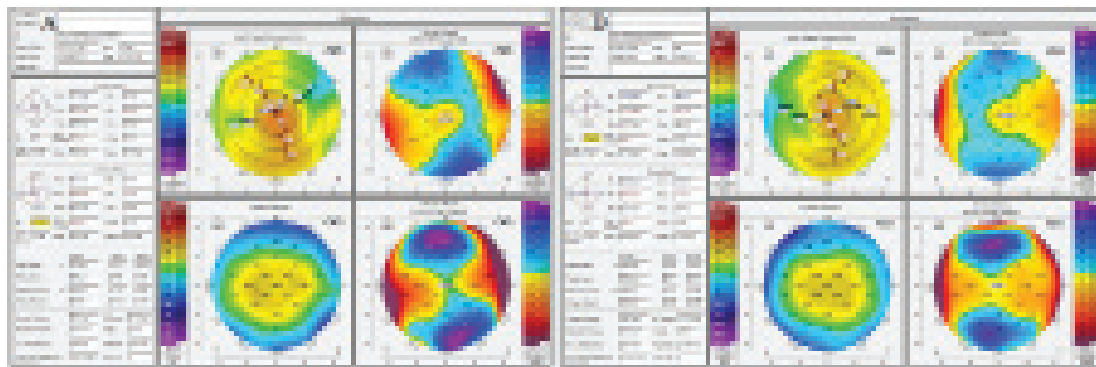


Figure 3- A: Corneal map of the right eye. B: Corneal map of the left eye.

Discussion

SCD is a rare, progressive, typically symmetric corneal disorder characterized by bilateral opacification of the cornea and corneal crystals in the Bowman layer and adjacent anterior stroma. (Weiss JS and Khemichian AJ, 2011; Köksal M et al, 2004; Rittenbach TL, 2013; Weiss JS, 2009; Zemba M et al, 2018; Evans CJ et al, 2018) SCD is indicating less than 20,000 cases and can be appeared in the first decade of life. (Rittenbach TL, 2013; Huda Al-Ghadeer et al, 2011) The signs found in this dystrophy result from lipid accumulation in the cornea and the patient needs to evaluate for systemic lipid problems. To be able to make a correct and early diagnosis of SCD, one must note that not all patients will have the crystalline configuration of the dystrophy. Most patients with an advanced appearance of this dystrophy will require some type of therapeutic

treatment usually with surgery for the cornea and cholesterol lowering medication.

The inheritance pattern is autosomal dominant with high penetrance, and the causative gene is found to be UbiA prenyltransferase domain-containing 1 (UBIAD1). Mutations in the UBIAD1 gene on chromosome 1p36 were recently shown to be the main cause of SCD of cholesterol and phospholipids in the corneal epithelium and stroma. (Rittenbach TL, 2013; Evans CJ et al, 2018) In this study we could not report the phenotype and genotype analysis of the patient.

SCD has previously been a poorly understood disease because of its infrequency and spectrum of clinical signs. The ophthalmologist must be aware of the fact that despite individual variations, there are expected variations in the corneal opacification presentation. The

characteristic crystals may develop with aging and may not always be seen on examination. Approximately 50-54 % of individuals have crystalline deposits. (Rittenbach TL, 2013) In our patient, we determined the crystalline deposits especially in his left eye. Patients who are younger than 23 years may have only a central corneal opacity, which may involve the entire stroma with or without central subepithelial cholesterol crystals. Central corneal mosaic opacities have been declared.

Familial hypercholesterolemia is the most common lipoprotein abnormality in patients with SCD up to two thirds with the disorder. We detected hypertriglyceridemia in our patient. Early arcus lipoides can also accompany with this dystrophy, we determined mild onset of arcus lipoides in our patient as well.

The largest population may be of Swedish and Finnish ethnicity, but the dystrophy has been found in African Americans, Asians, and Arabian populations. (Rittenbach TL, 2013) Our patient was a Syrian young man.

Differential diagnoses due to crystal deposition in the cornea include side effects from fluoroquinolones or other drugs such as gold in chrysiasis, chlorpromazine, chloroquine, and clofazamine, Bietti crystalline dystrophy, cystinosis, infectious crystalline keratopathy, and lymphoproliferative diseases such as monoclonal gammopathy and multiple myeloma. Our patient had no history of using fluoroquinolones or any other drug, infection or a systemic disease.

No treatment is available to stop disease progression. However, phototherapeutic keratectomy especially to remove the superficially located crystals, and penetrating keratoplasty (PKP) or deep anterior lamellar keratoplasty (DALK) can be performed. The short and medium term prognosis

of keratoplasty was good. The long-term prognosis may be deteriorated by the relapse of the dystrophy in the donor cornea. The rejection rate for DALK and that of PKP is 0-10% and 4-31%, respectively. (Rittenbach TL, 2013)

The ophthalmologists should be aware of the signs of SCD early on and order a lipid panel for those patients suspected of having SCD. Co-management with the cardiologist for any cholesterol issues is important for long-term cardiovascular health.

References

Evans CJ, Dudakova L, Skalicka P et al (2018). Schnyder corneal dystrophy and associated phenotypes caused by novel and recurrent mutations in the UBIAD1 gene. *BMC Ophthalmol*; 18: 250.

Huda A, Jawahir YM, Khan AO (2011). Schnyder Corneal Dystrophy in a Saudi Arabian Family with Heterozygous UBIAD1 Mutation (p.L121F). *Middle East Afr J Ophthalmol*; 18: 61-4.

Köksal M, Kargi S, Gürelik G, Akata F (2004). Phototherapeutic keratectomy in Schnyder crystalline corneal dystrophy. *Cornea*; 23: 311-3.

Rittenbach TL (2013). A case of Schnyder corneal dystrophy with crystals. *Optom Vis Sci*; 90: e301-4.

Weiss JS, Khemichian AJ (2011). Differential diagnosis of Schnyder corneal dystrophy. *Dev Ophthalmol*; 48: 67-96.

Weiss JS. Schnyder corneal dystrophy (2009). *Curr Opin Ophthalmol*; 20: 292-8.

Zemba M, Neacsu R, Cucu BI (2018). Stromal corneal dystrophy (possible Schnyder's dystrophy) with peripheral corneal degeneration - diagnostic and therapeutic challenges. *Rom J Ophthalmol*; 62: 175-80.