

Case Report

Macular edema secondary to malignant Hypertension managed with Intravitreal Bevacizumab

Abhinav Dhami¹, Latha Vichu¹, Parveen Sen¹

¹Shri Bhagwan Mahavir Vitreoretinal Services
Sankara Nethralaya, India.

Abstract

Introduction: Intravitreal anti VEGF agents are used in a variety of retinal pathologies to decrease the VEGF levels resulting due to breakdown of the blood retinal barrier hence decrease the exudation from vessels which causes macular edema (ME).

Case: A 61year old patient presented with sudden decrease in vision in both eyes with a history of systemic malignant hypertension leading to macular edema as documented on optical Coherence Tomography (OCT) in both eyes. The foveal thickness (FT) of 536 and 328 microns (μ) were observed in the right and left eye each. He was advised intravitreal anti vascular endothelial growth factor (VEGF) in both eyes and advised complete systemic evaluation with the physician. Following one month post intravitreal bevacizumab (IVB) injection in right eye, marked visual improvement was noted with concomitant significant reduction in macular edema in both eyes.

Observation: Single Bevacizumab injection with control of hypertension in our patient resulted in rapid resolution of the macular edema and early visual recovery.

Intravitreal anti VEGF is an effective treatment option in eyes due to hypertensive maculopathy especially to gain speedy visual recovery.

Conclusion: The case gives a unique outlook to the course of ME in the single patient with malignant HTN with or without IVB injection. We believe that anti VEGF injections may result in rapid recovery in vision and minimize the risk of permanent vision loss in eyes with malignant hypertension.

Key words: Malignant hypertensive maculopathy, intravitreal anti VEGF, Bevacizumab

Introduction:

Intravitreal anti VEGF agents are used in a variety of retinal pathologies where the

basic pathogenic mechanism is increased permeability of retinal vessels with exudation, Browning et al (2001). Hypertensive (HTN) retinopathy is also characterized by breakdown of the blood retinal barrier leading to macular edema (ME), Kim et al (2012). We describe a case of a recently diagnosed malignant HTN, presenting with sudden diminution of vision in both eyes due to ME, which responded to intravitreal bevacizumab (IVB) injection and aided in early visual recovery.

Financial Interest: Nil

Conflict of Interest: Nil

Received: 02.01.2018

Accepted: 05.06.2018

Corresponding author

Dr Parveen Sen

Senior consultant, Shri Bhagwan Mahavir Vitreoretinal Services
Sankara Nethralaya, No18, College Road, Nungambakkam,
Chennai – 600 006, India.

Mobile No: +91 – 9884327629;

Phone: +91-44-28271616; Fax: +91-44-28254180

E-mail: parveensen@gmail.com

Case Report:

A 61-year old male, presented with complaints of diminution of vision in both eyes since five days. The anterior segment examination was unremarkable. Best corrected visual acuity (BCVA) in both eyes for distance and near was 6/18(0.50) and 6/12 (0.30) each. Fundus examination of both eyes revealed optic disc swelling, multiple splinter shaped hemorrhages with cotton wool spots in peripapillary area with hard exudates forming macular star in the right eye (Fig: 1A- F). He was diagnosed recently with systemic HTN with blood pressure of 210/120 mm Hg. Fundus fluorescein angiography was performed after physician clearance, showed no evidence of neovascularization of disc or elsewhere. Both eyes optical coherence tomography showed ME with foveal thickness of 536 μ and 328 μ in right and left eye respectively (Figure 2A and 6B) A diagnosis of malignant HTN related maculopathy was established. Patient was advised complete systemic evaluation and managed with anti hypertensive medication by the internist. He was advised intravitreal bevacizumab (IVB) in both eyes. Due to financial constraints patient took IVB injection only for the right eye. The complications related to intravitreal injection were explained to the patient. The left eye was managed conservatively with Nepafenac eye drops (0.1%).

At 1 month follow up patient was symptomatically better with BCVA improving to 6/9 (0.20) N6 in both eyes. Both eyes OCT (Fig 3A and B) showed decrease in subretinal fluid in right eye more than left eye.

Discussion

Systemic hypertension affects retinal circulation to a great extent. Visual prognosis depends upon blood pressure at presentation, visual acuity at presentation and duration of symptoms, Browning et al (2001). In malignant

HTN retinopathy there is disruption of the blood retinal barrier resulting in exudation of blood and lipids in the subretinal space causing permanent visual impairment.

Single IVB injection in our patient resulted in rapid resolution of the ME and similar efficacy of Bevacizumab in reducing ME secondary to malignant HTN has been noted in few case reports in literature by Kim et al (2012). Remarkably the non-injected eye also showed improvement in vision and decrease in ME. This can be attributed to either spontaneous regression following good control of the systemic condition or the result of IVB in the fellow eye. Similar findings in relation to bilateral diabetic ME have been noted by Hanhart et al (2014).

Our case presents with a unique opportunity to study the course of ME in patients with malignant HTN with or without IVB injection in the same individual. We believe that anti VEGF injections may result in rapid recovery in vision and minimize the risk of permanent vision loss in eyes with malignant hypertension. Though some improvement may be expected even without this injection, it maybe slower.

To conclude prompt treatment with intravitreal anti VEGF is a useful adjunct to prevent permanent damage in eyes with HTN retinopathy with subretinal hard exudates while control of systemic HTN should be highly emphasized.

Abbreviations:

OCT- optical Coherence Tomography

ME- Macular edema

μ -microns

VEGF-vascular endothelial growth factor

Hypertension-HTN

BCVA- Best corrected visual acuity

IVB- intravitreal bevacizumab

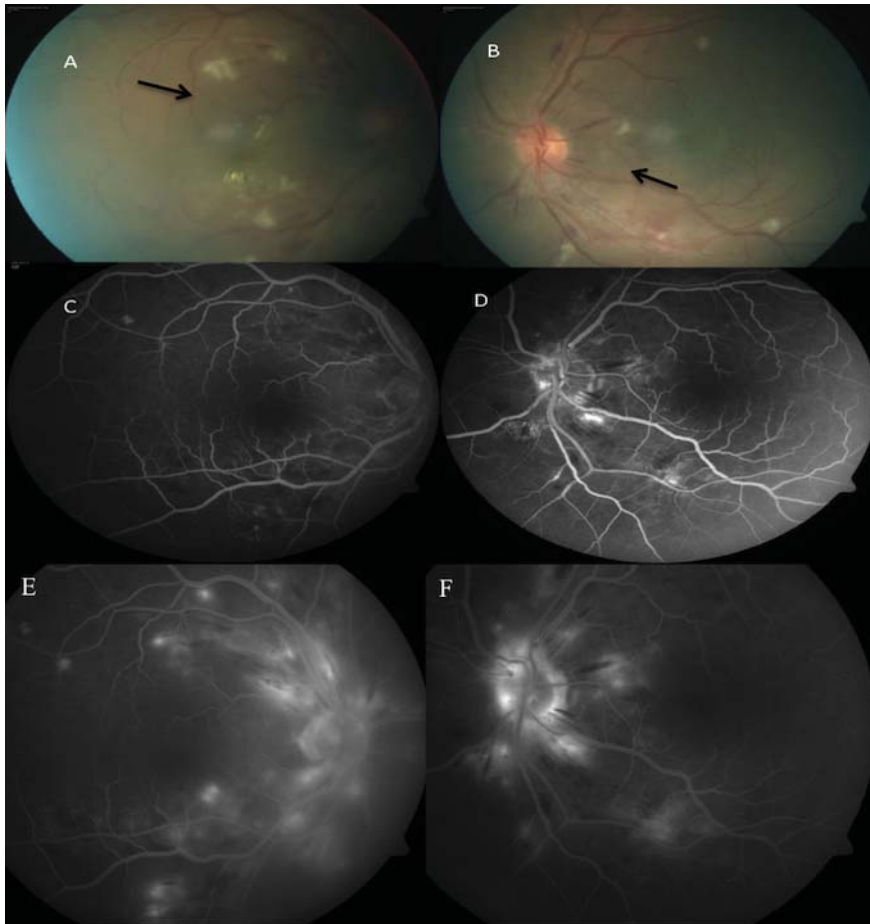


Figure 1 A and B shows right and left eye respectively with the presence of disc edema, peripapillary cotton wool spots and splinter hemorrhages(black arrow) and almost a complete macular star formation because of the subretinal exudates in the right eye typical of macular edema due to malignant hypertension. The figure C and D shows the early arterio-venous phase of angiography of the right and left eye with blocked fluorescence due to peripapillary splinter hemorrhages; figure E and F reveal presence of disc leakage in the late arterio-venous phase.

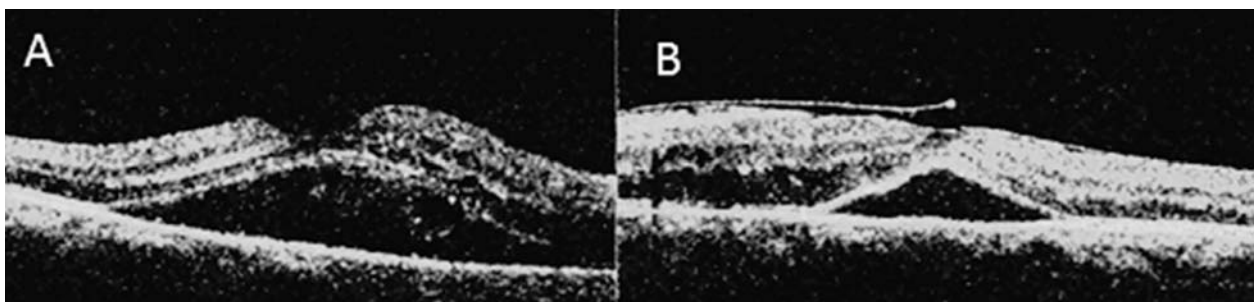


Figure 2 A and B shows the presence of sub retinal fluid at the macula in the right and left eye with a foveal thickness of 536 μ and 328 μ in each respectively on OCT.

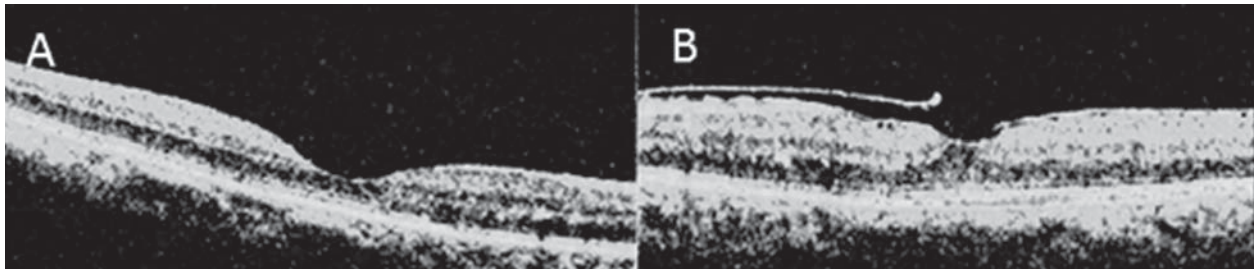


Figure 3 A and B shows complete resolution of sub retinal fluid post 1 month intravitreal injection of bevacizumab in right eye. The foveal thickness noted was 150 μ and 240 μ in the right and left eye.

References

Browning, A.C., Mengher, L.S., Gregson, R.M. and Amoaku, W.M (2001). Visual outcome of malignant hypertension in young people. *Archives of disease in childhood*; 85(5): 401-403.

Hanhart, J., Tiosano, L., Averbukh, E., Banin, E., Hemo, I. and Chowers, I. (2014).

Fellow eye effect of unilateral intravitreal bevacizumab injection in eyes with diabetic macular edema. *Eye*; 28(6): 646-653.

Kim, E.Y., Lew, H.M. and Song, J.H (2012). Effect of Intravitreal Bevacizumab (Avastin®) Therapy in Malignant Hypertensive Retinopathy: A Report of Two Cases. *Journal of Ocular Pharmacology and Therapeutics*; 28(3): 318-322.