

## Case Report

# A Case Report of An Iris Epithelial Cyst Masquerading As Iris Cysticercosis

Abhishek Hoshing<sup>1</sup>, Rita Dhamankar<sup>1</sup>, Shabnam Tanwar<sup>1</sup>, Deepak Bhat<sup>2</sup>

<sup>1</sup>Laxmi Eye Institute, Uran Road, Panvel, Maharashtra, India

<sup>2</sup> UBM Institute, Dadar East, Mumbai, Maharashtra, India

## Abstract

**Introduction:** Iris cysts can be primary or secondary. It is common to mistake a parasitic cyst for a benign pigment epithelial cyst. However, we report a case where a benign cyst was mistaken for a parasitic cyst.

**Case:** A 50-year-old gentleman was seen in our OPD with gradual, progressive, painless diminution of vision in the right eye over past 5 Months. He was found to have a cystic lesion in the iris encroaching upon the pupil.

**Observations:** Ultrasound biomicroscopy showed features characteristic of cysticercosis. In-toto excision of the cyst was done and was sent for histopathological examination. Histopathology failed to reveal features consistent with cysticercosis and instead showed characteristics of epithelial cyst of the iris.

**Conclusion:** Histopathological examination should be done for all cystic lesions of the iris to confirm diagnosis.

**Key words:** Anterior segment optical coherence tomography, Epithelial cyst, Histopathology, Iris cysticercosis, Ultrasound biomicroscopy.

## Introduction

Iris cysts can be primary or secondary. Primary cysts arise either from the iris pigmented or non pigmented epithelium or from iris stroma (Rao et al, 2011; Shields, 1981). Secondary cysts are classified according to the underlying cause as implantation cysts (which include traumatic cysts), drug-induced, uveitic, tumor-induced, parasitic, or as cysts associated with systemic disorders

(Rao et al, 2011; Shields, 1981). In this report we present a case of a benign epithelial cyst of the iris which mimicked an iris cysticercosis on ocular imaging.

## Case

A 50-year-old male presented with gradual, progressive, painless diminution of vision and a shadow appearing in right eye (OD) since 5 months. The shadow was progressively increasing in size. There was no history of redness, ocular trauma or any past ocular surgeries. There were no known systemic illnesses.

On ocular examination, best corrected visual acuity (BCVA) was 6/24, N18 (-2.50 D Cyl @ 180) in OD and 6/9 N6 (Near Add +2.50 D Sph) in left eye (OS). Slit lamp evaluation showed normal adnexa and ocular surface OU. In OD, a

**Financial Interest:** Nil

**Conflict of Interest:** Nil

Received: 13.12.2018

Accepted: 13.06.2019

## Corresponding author

Abhishek Hoshing

Laxmi Eye Institute, Uran Road,  
Panvel, Maharashtra, India.

Ph. No.: 022-27452228/ 27453147

Mobile No.: +91 9619998834

E-mail: abhishekhoshing@gmail.com

6 x 5 x 3 mm cystic lesion was noted within the iris tissue extending from 11 o'clock-2 o'clock position and partially encroaching upon the pupil

Anteriorly, it touched the endothelium as was also evident on Anterior segment OCT (AS OCT) (Figure 2). The cyst was filled with clear fluid and did not exhibit intrinsic motility. Nuclear sclerosis cataract grade II was noted in OU. Rest of the anterior and posterior segment findings were normal in OU.

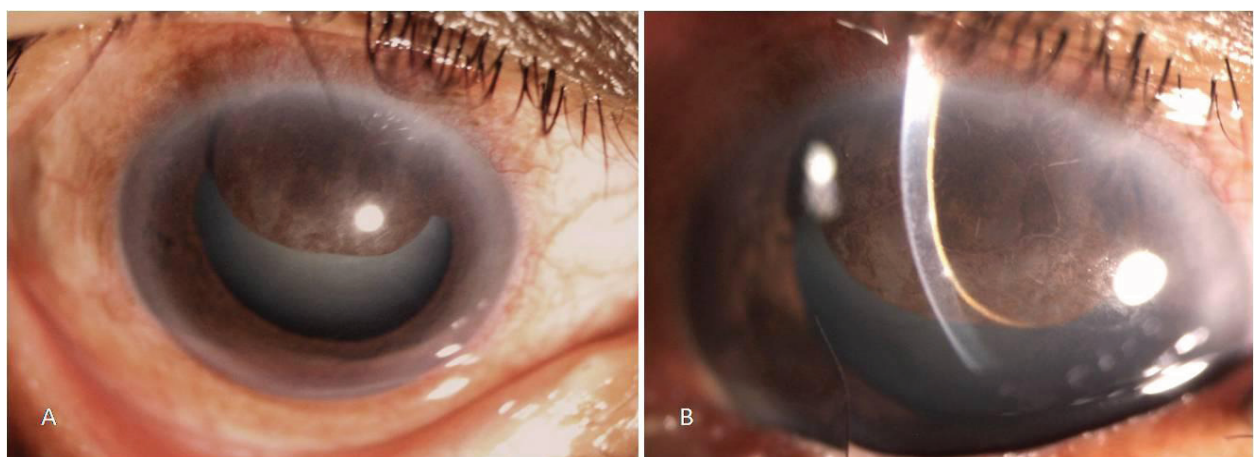
A provisional diagnosis of epithelial cyst of iris was made and an Ultrasound biomicroscopy (UBM) was requested to assess the extent and mass effect of the cyst.

UBM done using 50 MHz ophthalmic probe showed an iris cyst measuring 6.4 x 4.5 x 3.6 mm. A dense echogenic spot was also seen along the cyst wall which was thought to be a scolex. The lens and iris were pushed posteriorly (Figure 3). Based on this the diagnosis of iris cysticercosis was made. MRI of brain, orbit and paranasal sinus did not reveal any other active or healed cystic lesion

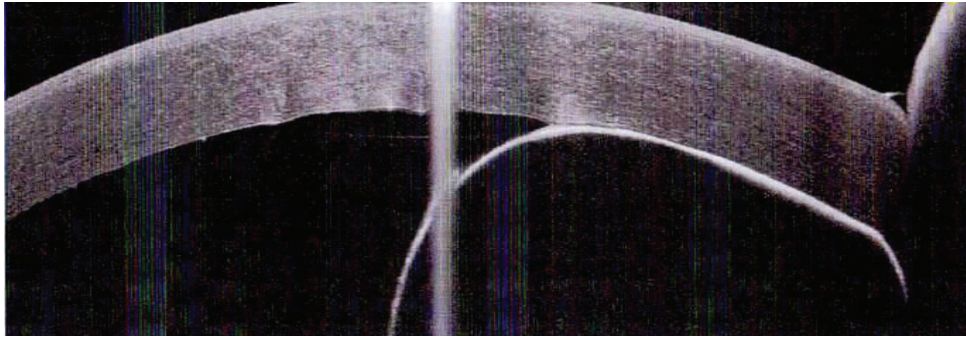
Sectoral iridectomy was done from 10 to 3 o'clock for in-toto cyst excision after aspirating the fluid from the cyst with a 26 g needle passed from a temporal paracenteses. The iris

tissue was radially incised along the temporal and nasal edges of the cyst with intra-ocular micro-scissors from nasal and temporal limbal paracenteses. Iris was cut along the limbal edge of the cyst using curved micro-scissors. The tissue along with the collapsed cyst was delivered out of the anterior chamber from a three step 2.8 mm incision superior limbal incision and was sent for histopathological examination. It revealed a cyst lined by non-keratinizing squamous epithelium. No degeneration, granulomas, inflammatory cells or parasitic structures were seen along the cyst wall giving an impression of benign epithelial cyst of iris.

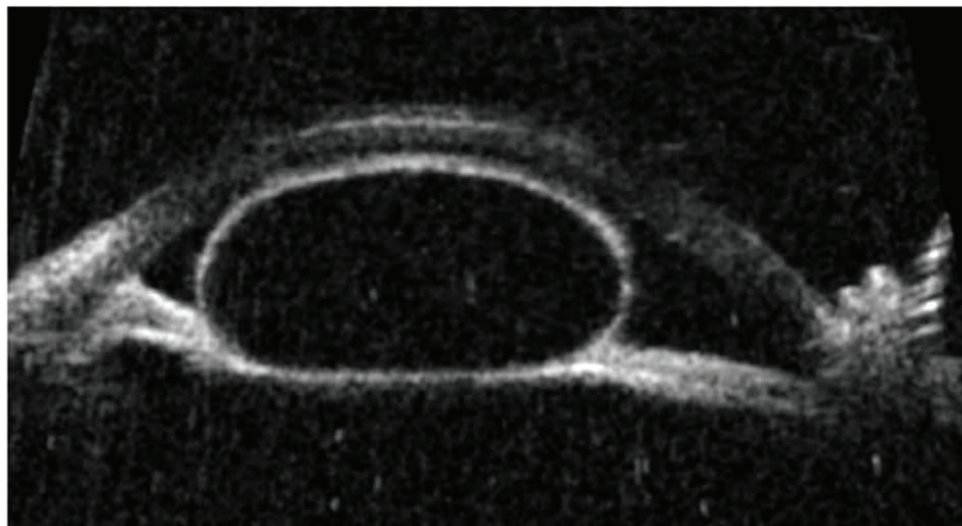
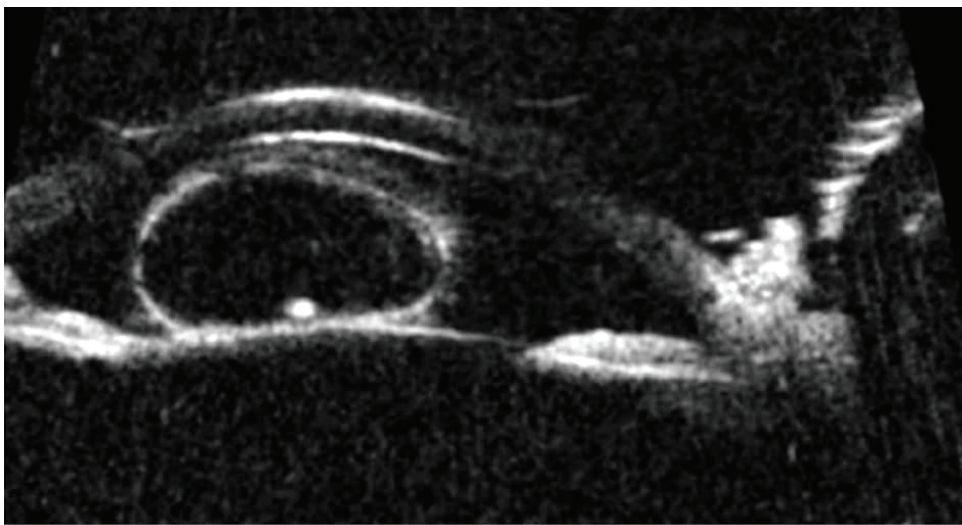
Topical steroids, started at six times a day and in tapering doses, topical antibiotics and cycloplegic eye drops were prescribed post operatively. Systemic anti-helminthic therapy was withheld till the availability of histopathology report which was available after 3 days. Patient was reviewed after one day, one week and one month. The eye was quiet on the last visit and no residual/recurrence of cyst was seen on slit lamp or AS OCT. The patient did not have significant glare because the eyelid covered the area of iridectomy. The patient's BCVA improved to 6/12p N18 with -1.25 D cyl @ 55. The residual vision loss was attributed to the nuclear sclerosis grade 2 cataract.



**Figure 1:** Diffuse light (A) and Slit illumination (B) image showing the extent of the cystic lesion of the iris of the right eye.



**Figure 2:** Anterior Segment OCT (ASOCT) of the lesion showing anterior adhesion to the endothelium and clear space within the cyst.



**Figure 3:** Ultrasound biomicroscopy of the lesion showing cyst with well defined walls, hypoechoic contents with a single hyperechoic spot near the wall. The iris is seen pushed backwards



## Discussion

Anterior segment cysticercosis, especially involving the iris, is a rare phenomenon (Dhiman et al, 2017). In a study reported by Kruger-Leite (1985), 35% of the cysts were found in the subretinal space, 22% in the vitreous, 22% in the subconjunctival space, 5% in the anterior segment (rarely presents as iris cyst) and only 1% in the orbit.

Laboratory studies are not of much value in intraocular cysticercosis and they lack sensitivity. (Dhiman et al, 2017; Wadhva et al, 2006). Therefore, imaging studies become more useful in diagnosing intraocular cysticercosis (Bodh et al, 2012).

The classic ultrasonography B-scan findings are a well defined cystic lesion with hypoechoic (clear) contents with a hyperechoic area suggestive of a scolex (Honavar and Sekhar, 1998). These exact same characteristics were seen in our patient thus prompting the radiological diagnosis. On ultrasound A-scan the scolex may also show high reflectivity spikes due the presence of calcareous corpuscles (Honavar and Sekhar, 1998). However, the A-scan data was not available to us. On UBM, iris epithelial cysts have a smooth wall with high reflectivity. There are no internal reflections in these cysts (Conway et al, 2005).

Histopathological diagnosis is considered to be the most definitive diagnosis of any lesion. The cyst wall of intraocular cysticercosis is characterised by hyaline degeneration and inflammatory cell infiltration (Li et al, 2013). Sesame seed like structures which are scolices may also be attached to the inner layer of the wall. None of these findings were present in our patient.

The histological findings in our patient were consistent with those of iris epithelial cyst (Paridaens et al, 1992). Hence it is the definitive histopathological diagnosis in our patient.

Absence of anterior chamber inflammation at presentation and very minimal post-operative reaction also supports this diagnosis.

However, the hyperechoic lesion seen in the UBM remains unexplained. We presume it was a clump of cellular debris or pigment sequestered within the cyst cavity which presented as a hyperechoic spot on UBM.

## Conclusion

In conclusion, a high index of suspicion may arise for the diagnosis of ocular cysticercosis because of the endemic nature of this infestation. Ultrasonography biocmicroscopy helps to establish the diagnosis but sometimes may be misleading and thus should be confirmed with histopathological examination.

## Acknowledgements

We acknowledge Dr Rahil Pande for processing, examining and reporting the histopathology specimen provided during the management of this patient.

## References

- Bodh SA, Kamal S, Kumar S, Goel R, Nagpal S, Aditya K (2012). Orbital Cysticercosis. *DJO*; 23: 99-103. DOI: <http://dx.doi.org/10.7869/djo.2012.50>. url: <http://www.djo.in/articles/23/2/orbital-cysticercosis.html>
- Conway RM, Chew T, Golchet P, Desai K, Lin S, O'Brien J (2005). Ultrasound biomicroscopy: Role in diagnosis and management in 130 consecutive patients evaluated for anterior segment tumours. *Br J Ophthalmol*; 89: 950–5. url: <https://bjo.bmj.com/content/89/8/950.long>
- Dhiman R, Devi S, Duraipandi K et al (2017). Cysticercosis of the eye. *Int J Ophthalmol*; 10(8): 1319-24. DOI: <https://doi.org/10.18240/ijo.2017.08.21.eCollection2017>. url: <https://www.ncbi.nlm.nih.gov/pmc/articles/PMC5554854/>



Honavar SG, Sekhar CG (1998). Ultrasonological characteristics of extraocular cysticercosis. *Orbit* ; 17(4): 271-84.

Kruger-Leite E, Jalkh AE, Quiroz H, Schepens CL (1985). Intraocular cysticercosis. *Am J Ophthalmol*; 99(3): 252-7. url: [https://www.ajo.com/article/0002-9394\(85\)90352-6/pdf](https://www.ajo.com/article/0002-9394(85)90352-6/pdf)

Li JJ, Zhang LW, Li H, Hu ZL (2013). Clinical and pathological characteristics of intraocular cysticercosis. *Korean J Parasitol*; 51(2): 223-9. DOI: <https://doi.org/10.3347/kjp.2013.51.2.223>. url: <http://parasitol.kr/journal/view.php?id=10.3347/kjp.2013.51.2.223>

Paridaens AD, Deuble K, McCartney AC (1992). Spontaneous congenital non-pigmented epithelial cysts of the iris stroma.

*Br J Ophthalmol*; 76(1): 39–42. url: <https://bjournals.bmj.com/content/76/1/39.long>

Rao A, Gupta V, Bhadange Y, Sharma R, Shields JA (2011). Iris cysts: a review. *Semin Ophthalmol*; 26(1): 11-22. DOI: <https://doi.org/10.3109/08820538.2010.541319>. url: <https://www.tandfonline.com/doi/full/10.3109/08820538.2010.541319>

Shields JA (1981). Primary cyst of the Iris. *Trans Am Ophthalmol Soc*; 79: 771-809. url: <https://www.ncbi.nlm.nih.gov/pmc/articles/PMC1312203/>

Wadhwa V, Kharbanda P, Rai S (2006). How reliable are serological tests in diagnosis of cysticercosis? *Indian J Med Microbiol*; 24(1): 78-79. url: <http://www.ijmm.org/article.asp?issn=0255-0857;year=2006;volume=24;issue=1;spage=78;epage=79;aulast=Wadhwa>