

Brief Communication

A typical manifestation of conjunctival epithelial inclusion cyst

Jitender Jinagal¹; Parul Chawla Gupta¹; Nandita Kakkar²; Jagat Ram¹

¹Department of Ophthalmology and ²Department of Histopathology,
Post Graduate Institute of Medical Education and Research, Chandigarh-160012, India

Abstract

Purpose: To report a case of conjunctival epithelial inclusion cyst with atypical manifestation. **Methods:** A 26-year-old male presented with a blackish-brown, subconjunctival mass located in palpebral conjunctiva of the upper eyelid. En bloc excision of the mass was performed and evaluated on histopathological examination. **Results:** The excised mass was well defined, dark brown in colour and simulated a solid foreign body. On histopathological examination, the mass was lined by stratified squamous epithelium with florid hyperkeratosis and haemorrhage inside it, consistent with atypical conjunctival epithelial inclusion cyst. **Conclusion:** A careful clinical examination and histopathological study is essential for the differential diagnosis of subconjunctival mass as rarely they may present with atypical manifestations.

Keywords: Conjunctival epithelial inclusion cyst; atypical manifestation; subconjunctival mass

Introduction

Conjunctival epithelial inclusion cysts comprise approximately 6–13% of all conjunctival lesions. They may be congenital or acquired (Shields et al, 2004). Acquired conjunctival cysts are more common. They may occur after trauma or surgical intervention due to subconjunctival implantation of epithelial cells or may occur after inflammatory diseases like vernal keratoconjunctivitis and Steven Johnson Syndrome. Most inclusion cysts present as a subconjunctival cystic mass filled with clear fluid and are easily diagnosed by clinical examination. However, few reports have demonstrated atypical manifestations of cysts masquerading as a subconjunctival abscess,

melanoma or hematoma and none till date mimicking a foreign body (Khan et al, 2007; Jeanniton et al, 2013; Kim et al, 2008).

Case

Twenty six year old male patient, labourer by profession, presented to us with complaints of right eye foreign body sensation, watering and pain on blinking. On ocular examination there was blackish-brown pigmented raised lesion protruding from the palpebral conjunctiva of the right upper eyelid (Figure 1A). The surrounding conjunctiva was hyperemic and congested. There was presence of small epithelial defect on cornea in its superior half corresponding to the area of lesion in the palpebral conjunctiva. There was no definitive history of trauma, surgery or foreign body falling in the eye. En bloc surgical excision of the mass was performed. On gross inspection, it was a blackish, firm, gritty mass approximately 3x2.5 mm in size, simulating

Corresponding author

Dr. Jagat Ram
M.S Ophthalmology, FAMS
Professor
Advanced Eye Center, Sector 12
Post Graduate Institute of Medical Education and Research,
Chandigarh, India
E-mail: drjagatram@gmail.com

a solid foreign body. Histopathology revealed stratified squamous epithelium with florid hyperkeratosis (Figure 1B). Superficial layer of keratin showed presence of ghost cells. Haemorrhage was noted inside the mass. There was no evidence of granuloma, dysplasia or malignancy. Histopathological features were suggestive of epidermal inclusion cyst of the conjunctiva.

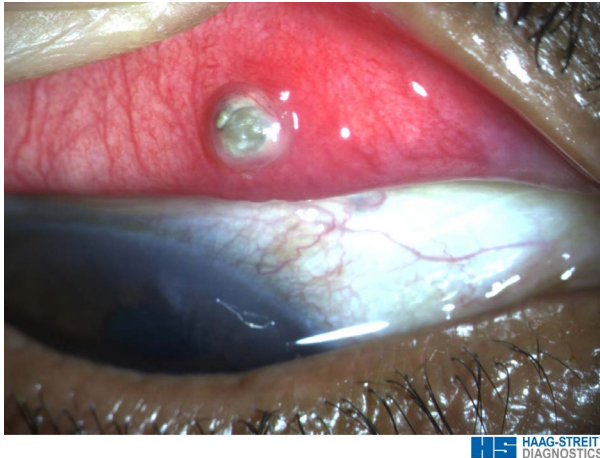

Figure 1 A: Clinical picture of the lesion on right upper lid palpebral conjunctiva showing blackish-brown mass protruding out and surrounded by hyperaemia.

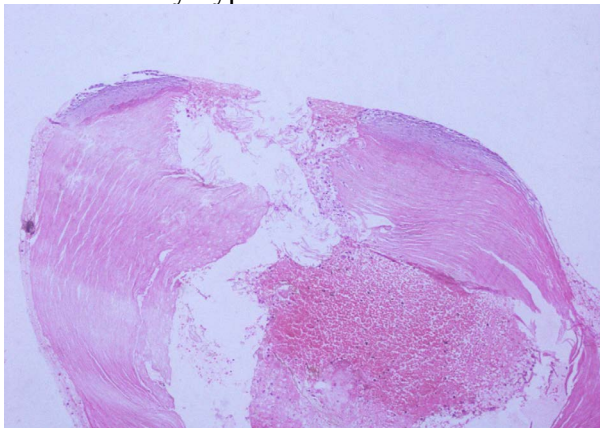


Figure 1 B: Histopathological section of the mass showing florid hyperkeratosis on walls

Discussion

Inclusion cysts are benign cysts filled with clear serous fluid containing shed epithelial cells or gelatinous mucous material (Thatte et al, 2015). Cyst wall consists of several

layers of non-keratinising lining epithelium and connective tissue. Majority, over 80% of the entire cystic lesions of conjunctiva are inclusion cysts (Thatte et al, 2015) They may be primary or secondary. Primary cysts are congenital, which remain hidden in the fornix and gradually increase with age. Secondary cysts can be parasitic, implantation due to trauma and degenerative (Nath et al, 1983). Our patient presented with a solid blackish-brown lesion, simulating a foreign body. Histopathology revealed epidermal inclusion cyst of conjunctiva with florid hyperkeratosis. The uncommon clinical presentation and absence of trauma makes it an atypical manifestation of conjunctival inclusion cyst.

References

- Jeanniton C, Finger PT, Leung E, McCormick SA, Chin K, Milman T (2013). Infected epithelial inclusion cyst simulating conjunctival melanoma. *Ophthal Plast Reconstr Surg*; 29: 131–e134.
- Khan AO, Al-Katan H, Al-Baharna I, Al-Wadani F (2007). Infected epithelial inclusion cyst mimicking subconjunctival abscess after strabismus surgery. *J AAPOS*; 11: 303–304.
- Kim JH, Oh SY (2008). A conjunctival cyst with delayed internal hemorrhage after strabismus surgery. *J AAPOS*; 12: 409–411.
- Nath K, Gogi R, Zaidi Nahid (1983). Cystic lesions of conjunctiva. *IJO*; 31: 1–4.
- Shields CL, Demirci H, Karatza E, Shields JA (2004). Clinical survey of 1,643 melanocytic and nonmelanocytic conjunctival tumors. *Ophthalmology*; 111: 1747–1754.
- [Thatte S](#), [Jain J](#), [Kinger M](#), [Palod S](#), [Wadhva J](#), [Vishnoi A](#) (2015). Clinical study of histologically proven conjunctival cysts. *Saudi J Ophthalmol.*; 29(2):109-15.