

Case report

Spontaneous formation and closure of full thickness macular hole in a vitrecto-mised eye, : a case report

Rajya Laxmi Gurung

Department of vitreo-retina, Biratnagar Eye Hospital, Biratnagar, Nepal

Introduction

The exact pathogenesis of macular hole (MH) is controversial with most of the cases being idiopathic. Trauma is an important cause of secondary MH formation. MH post Pars Plana Vitrectomy (PPV) is an even rare entity with only a handful of cases reported so far (Kumagai et al, 2008; Smiddy W.E, 1993; Kimura et al, 2005). An even rarer event is spontaneous closure of post PPV full thickness macular hole (FTMH), though spontaneous closure of traumatic macular hole (TMH) has been reported before. Herein, we report a 26 year old male patient who developed FTMH post PPV that closed spontaneously.

Case presentation:

A 26 years male presented to us in August 2016 with history of left eye (LE) blunt trauma. On examination, best corrected visual acuity (BCVA) in LE was finger counting (FC). Slit lamp examination (SLE) revealed hazy cornea with mid dilated pupil, grade 2 anterior chamber (AC) reaction and traumatic early cataract. The posterior segment examination was hazy due to presence of vitreous haemorrhage (VH). Intra ocular pressure (IOP) measured with goldmann applanation tonometer was 48 mm Hg. Gonioscopy of LE showed presence of angle recession and >270 degree of peripheral anterior synechia (PAS). B-scan ultrasonography of LE revealed presence of dense VH with intact

retina. Examination of right eye (RE) was unremarkable.

The patient underwent LE standard Pars Plana Vitrectomy (PPV) with Phaco-emulsification with Pars Plana insertion of baerveldt glaucoma implant in the supero-temporal quadrant. Other than the insertion of Capsular tension ring (CTR) for zonular dialysis, the surgery was uneventful. No MH was noted intra-operatively.

On the first post-up day, the BCVA in LE improved to 20/200, IOP was in the higher range 26 mm Hg. Anterior segment examination revealed intra-ocular lens (IOL) in place with the tube of the baerveldt shunt clearly visible in the vitreous cavity. Fundus evaluation revealed clearing of VH with no MH. The patient was discharged on topical steroids and anti-glaucoma medications.

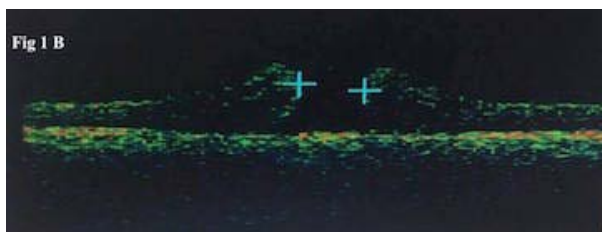
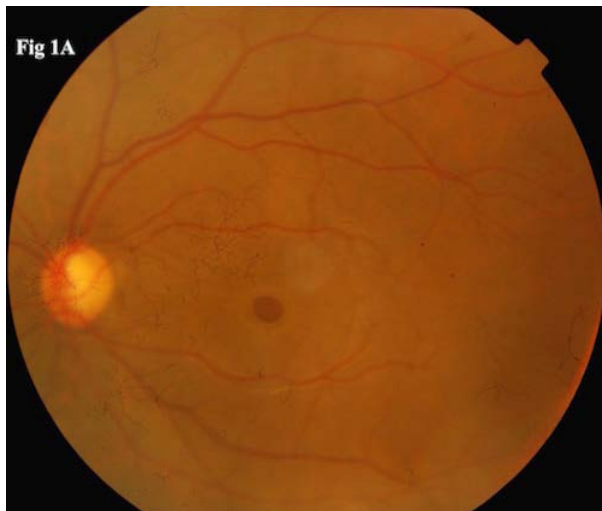
On follow up at 1 week, the BCVA improved to 20/125, on fundus evaluation, there was no MH. IOP of LE was 22 mm Hg. On follow up at 2 weeks, the BCVA decreased to 20/200. Fundus evaluation revealed a FTMH (Fig 1A) which was confirmed by Optical coherence tomography (OCT) (Fig 1B).

Received on; 12/03/17

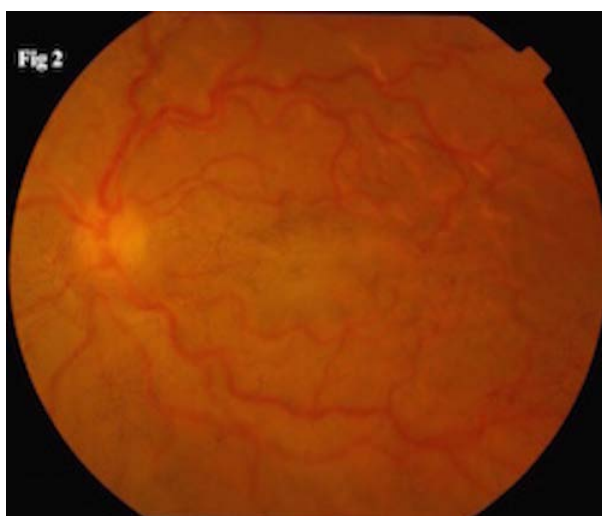
Accepted on: 17/06/17

Corresponding author

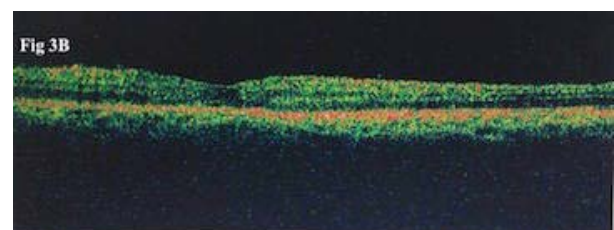
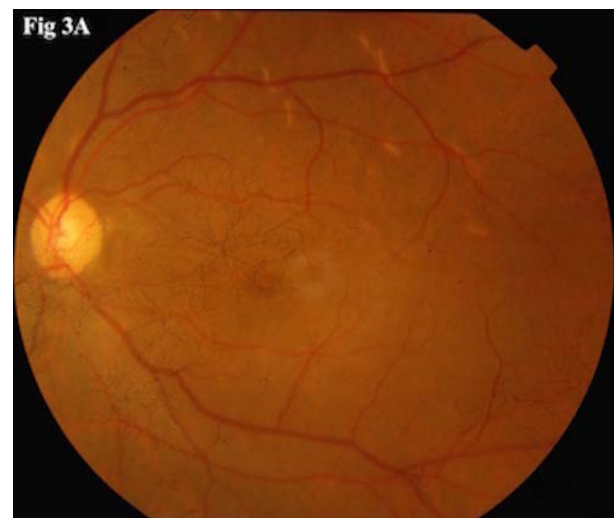Rajya Laxmi Gurung, MD,
Department of vitreo-retina, Biratnagar Eye Hospital,
Mills area Biratnagar -17, Nepal;
e-mail: rajya82@yahoo.com; Mob no : 9856013613



Watzke Allen test was positive. The IOP of the LE was 22 mm Hg. Various treatment options, including conservative management, were discussed with the patient. On the third follow up at 3 weeks, the BCVA was 20/200. IOP in the LE was 4 mmHg due to opening of the baerveldt valve. Fundus evaluation revealed the closure of MH (Fig 2), there was dilated tortuous retinal vessels with mild disc hyperaemia.



Apart from the spontaneous closure of MH, rest of the fundus findings was consistent with hypotony maculopathy. Anti-glaucoma medications were stopped and topical steroids were continued in tapering dose. On fourth follow up 8 weeks, the BCVA in LE had improved to 20/80. IOP was 20 mm Hg without any anti-glaucoma medication. MH remained closed (Fig 3A), which was confirmed by OCT (Fig 3B).



Discussion

FTMH post PPV is very rare. Though there are a handful of reports about post PPV MH, the exact pathogenesis and management of such atypical MH is controversial. In our case, whether the FTMH developed as a result of the primary blunt trauma or as a result of PPV is difficult to distinguish. The fact that intra-operatively there was no MH, favour the latter. However, TMH may develop immediately after trauma or several weeks post trauma. The reported incidence of post PPV MH is 0.24 % (Lee et al, 2010). Brown et al (1988) first reported incidence of 0.9% after scleral buckling, M

Benzerroug et al (2008) also reported 0.9% after post retinal detachment PPV. Retinal detachment (RD), epiretinal membrane (ERM) and cystoid macular oedema (CME) were frequent ocular pathologies associated with post PPV MH formation. Lee et al (2010) have suggested two pathogenic mechanisms for post PPV MH formation, cystoid degeneration and tangential traction. Kumagai et al (2008) reported 47 cases of secondary MH after vitrectomy, showing that all eyes diagnosed with secondary MH had an ERM.

In our case, no internal limiting membrane peeling was done during PPV so ERM could be one of the causative factors. As reported by Kim et al (2015), induced VMT due to remnant posterior vitreous cortex around macula as a result of incomplete PVD could also be one of the reasons for post PPV MH.

Intra-operative iatrogenic trauma could be another cause of post PPV MH, but the surgery was uneventful and no MH was detected at the time of closure and till 1st follow up.

Spontaneous closure of post PPV MH is very unusual and difficult to predict due to the rarity of post PPV MH. Kim et al (2015) have reported a case of spontaneous closure of MH, which developed post RD surgery. According to the authors, induced VMT due to incomplete PVD was the cause of MH and spontaneous removal of VMT led to the closing of MH.

Tsilimbaris et al (2007) have reported three case series of spontaneous closure of post PPV MH; all the 3 cases had undergone PPV for RD and secondarily developed MH in the post op period, which resolved spontaneously over the course of one year with improvement in final BCVA. In our patient, the closure of hole was within four weeks period with subsequent improvement in BCVA. Our findings are also in accordance with two single- patient reports published in the literature by Lo and Hubbard (2006) and Shukla et al (2006). Lo and Hubbard

(2006) reported a case who developed MH post PPV for vitreous haemorrhage (VH) after 7 years, the hole closed spontaneously to again recur after a year. Shukla et al (2006) reported a case of spontaneous closure of MH post PPV for central retinal vein occlusion (CRVO).

There are few studies on surgical out come for post PPV MH. Kumagai et al (2008) have reported 47 eyes with post PPV MH. All the patients underwent re-PPV with or without ILM peeling. Anatomic closure was reported after single surgical procedure in 33 (68%) eyes whereas rest of the eyes required additional procedure. Lee et al in their study reported 90 % closure of secondary MH after PPV with ILM peeling.

Our case is very unique due to the fact that the hole developed in the immediate post operative period and also closed spontaneously in a very short period of time. However a long term follow up is a must since re-opening of hole could happen as reported by Lo and Hubbard (2006). Moreover, in our case hypotony might have played a significant role in the spontaneous closure of the MH. Significant hypotony resulted in collapse of scleral wall, which led to decrease in the vireo-macular traction aiding in the spontaneous closure of the MH. Hypotony might also have exaggerated the epiretinal membrane shrinkage and contracture aiding in the spontaneous closure of MH. Till date, no studies have mentioned any correlation between hypotony maculopathy and spontaneous closure of MH. Previous studies have mentioned smaller MH size to be a good prognostic factor for spontaneous closure unlike in our case where the hole size was large, 623 microns.

Conclusion

Spontaneous closure of FTMH in prior vitrectomized eye is an unusual event. Our case report is sixth to be reported in the literature; moreover this is the first with any correlation



with hypotony. In these patients, factors such as exaggerated epiretinal membrane shrinkage and contracture, remnant posterior vitreous cortex around macula, post-surgical inflammation, cystoid macular changes, iatrogenic trauma could represent the pathogenesis, the remission of which may explain the spontaneous resolution. Though spontaneous closure can occur but long term follow up with regular OCT is a must as very small chances of re-opening of MH is still present.

References

Benzerroug M, Genevois O, Siahmed K et al (2008). Results of surgery on macular holes that develop after rhegmatogenous retinal detachment. *British Journal of Ophthalmology*; 92(2):217-219.

Brown GC (1988). Macular hole following rhegmatogenous retinal detachment repair. *Archives of Ophthalmology*;106(6):765-766.

Kim JY, Park SP (2015). Macular hole formation and spontaneous closure after vitrectomy for rhegmatogenous retinal detachment documented by spectral-domain optical coherence tomography: Case report and literature review. *Indian journal of ophthalmology*;63(10):791-793.

Kimura H, Kuroda S, Nagata M (2005). Macular hole formation in postvitrectomized eyes;25(4):521-523.

Kumagai K, Ogino N, Furukawa M et al (2008). Surgical outcomes for patients who develop macular holes after pars plana vitrectomy. *American journal of ophthalmology*;145(6):1077-1080.

Lee SH, Park KH, Kim JH et al (2010). Secondary macular hole formation after vitrectomy. *Retina*;30(7):1072-1077.

Lo WR, Hubbard GB (2006). Macular hole formation, spontaneous closure, and recurrence in a previously vitrectomized eye. *American journal of ophthalmology*;141(5):962-964.

Shukla D, Rajendran A, Kim R (2006). Macular hole formation and spontaneous closure after vitrectomy for central retinal vein occlusion. *Graefe's Archive for Clinical and Experimental Ophthalmology*;244(10):1350-1352.

Smiddy WE (1993). Atypical presentations of macular holes. *Archives of Ophthalmology*;111(5):626-631.

Tsilimbaris MK, Gotzaridis S, Charisis SK et al (2007). Spontaneous closure of macular holes developed after pars plana vitrectomy. *In Seminars in ophthalmology*; 22(1): 39-42.

Source of financial disclosures: none