

Case report

Ocular Decompression Retinopathy : A Case Series

Kirti Singh¹, Mainak Bhattacharyya¹, Keerti Wali¹, Kartik Rana¹, Divya Jain¹

¹Department of Ophthalmology; Guru Nanak Eye Centre, Delhi, India

Abstract

Introduction: Ocular decompression retinopathy (ODR) is a relatively rare entity with variable prognosis depending on extent and pre-existing condition. This article describes profile of two cases with a brief review of the condition.

Case report: Case 1 highlights extensive choroidal detachment with subhyaloid haemorrhage and multiple intra-retinal hemorrhages in the posterior pole seen on first post-operative day in a 6 year old child with congenital glaucoma who underwent Trab & Trab. Case 2 describes multiple intraretinal hemorrhages seen at posterior pole on second post-operative day in a 24 year old pregnant lady with post traumatic cataract and secondary glaucoma who underwent cataract extraction with Cionni ring. Both patients had complete resolution of the haemorrhages with topical steroids.

Conclusion: Ocular decompression retinopathy is mostly seen after operations on cases with advanced glaucoma and those with vulnerable blood flow fluidics. Adequate precautions to prevent this entity should be adopted during surgery and management of the manifest entity is conservative with good prognosis.

Keywords: Decompression retinopathy, Glaucoma, Haemorrhages, Trabeculectomy

Introduction

The term ocular decompression retinopathy was coined by Fechner et al (1992) to describe retinal changes subsequent to iatrogenic lowering of intraocular pressure after glaucoma filtering surgery. The cause was attributed to sudden reduction of IOP over a relatively short time in a previously pressurized eye. This was followed by other reports corroborating the occurrence of this entity after glaucoma surgery. Thereafter it was described after minor procedures in the gamut of glaucoma management like iridotomy, iridoplasty, anterior chamber paracentesis by Gupta et al (2005) and rarely following medical management. Other surgical procedures implicated in its aetiology are also

orbital decompression, phacoemulsification and vitrectomy.

Ocular decompression retinopathy (ODR) is a relatively rare entity with variable prognosis depending on extent and pre-existing condition. This article describes profile of two cases of ODR and a brief review of the condition.

Case 1

A 6-year old male child presented with very poor vision hampering independent navigation for last 1 year. There was no history of photophobia or epiphora in the past. On examination, visual acuity was CF 2 meter with accurate projection of rays in right eye and only perception of light (PL) with inaccurate projection (PR) all four quadrants in left eye. Cornea was clear with diameter of 12 -13 mm OU along with central Haab's striae OD. Intraocular pressure (IOP)

Received: 24/11/16

Accepted: 20/06/17

Corresponding author

Mainak Bhattacharyya
Maharaja Ranjit Singh Marg, Delhi -110002, India
91-9891348130
drmainakb@gmail.com

by Perkins tonometer was 38 mm OU. Disc damage was significant with average sized disc DDLS scale 8 (cup-disc ratio 0.9:1) both eyes.

The child was the product of non-consanguineous marriage with similar affliction in one elder sibling who had been operated for glaucoma. Ocular hypotensive treatment was initiated in form of oral Acetazolamide, topical Dorzolamide and topical Timolol. This resulted in control of intraocular pressure (IOP) within 2 weeks to 20 mm-Hg. The patient was scheduled for trabeculectomy and trabeculotomy (Trab & Trab) in the right eye.

Examination under anaesthesia prior to Trab & Trab under sevoflurane documented IOP of 18 mm: 16 mm Hg:: OD:OS respectively. Standard trabeculectomy and trabeculotomy with adjunctive use of 0.02 % Mitomycin C for 3 minutes along with subconjunctival amniotic membrane over the superficial sclera flap was performed under general anesthesia using nitrous oxide/ sevoflurane mixture along with intravenous fentanyl.

The surgery was done as per protocol followed for surgery in advanced glaucoma settings which included creation and titration of side port, slow decompression during inner sclerostomy and preplaced sclera flap sutures. Superficial scleral flap was sutured using two fixed 10-0 nylon sutures and one surrogate releasable suture of 9-0 vicryl suture. Anterior chamber (AC) was maintained throughout and bleb titration at end of surgery through side port left the anterior chamber deep with no bleb leak on table.

Examination on 1st post-operative day revealed shallow anterior chamber, diffuse bleb with hypotony (IOP < 4 mm Hg). Visual acuity had deteriorated to light perception with inaccurate PR in 2 quadrants. Dilated fundus exam revealed extensive choroidal detachment with subhyaloid haemorrhage and multiple

intraretinal hemorrhages in the posterior pole. (Fig 1;i,ii) Decompression retinopathy was diagnosed and topical NSAIDs were started in addition to two hourly topical steroids. The steroids were tapered over 2 weeks by which time both choroidal detachment and retinal hemorrhages started resolving and IOP value was 10 mm-Hg. (Fig 1;iii) Visual acuity had improved to CF 1 m with accurate PR.

The left eye was subjected to Trab & Trab 3 months after right eye had regained preoperative visual acuity of CF 2 m and the postoperative course of this eye with similar surgical protocol was uneventful. (Fig 1;iv)

Case 2

A 24-year-old pregnant lady presented with marked diminution of vision OD following injury sustained with firecracker a week ago. On examination vision recorded was HMCF, PR accurate OD and 20/20 OS. The IOP recorded was 35 mm Hg and 14 mm Hg in OD and OS respectively. Anterior segment evaluation showed resolving hyphema, iridodialysis of 4-5 clock hours, subluxated cataractous lens with 180- 270 degrees zonular dialysis. (Fig 2;i) Cataract precluded fundus evaluation; however ultrasonography findings were unequivocal.

Medical management was initiated with systemic (mannitol and glycerol) along with topical anti glaucoma medications; 2% Pilocarpine and 0.5% Timolol (relatively safer drugs in pregnancy). IOP could be lowered to early 20s (20-22) in pre-operative period on the systemic and topical anti-glaucomamedications. In view of her second trimester pregnancy systemic acetazolamide was withheld. Over a 7 day period the hyphema resolved and gonioscopy performed documented angle recession of 4-5 clock hours. Ongoing phacodonesis with persistent secondary glaucoma necessitating systemic mannitol for IOP control led to the decision to perform phacoemulsification with capsular

bag stabilization.

Cataract management took priority over trabeculectomy due to unstable lens dynamics. Low power, reduced fluidics, ‘in-the-bag’ phacoemulification was done along with stabilization of capsular bag using a fixated single loop Cionni ring (Fig 2;ii,iii). The surgery was performed under peribulbar block using Xylocaine 2% along with bupivacaine 0.75% 1:1 mixture with hyaluronidase 75 IU/ml.

Surgery was uneventful and vision improved to 20/120 (Snellen equivalent 6/36) with clear media and IOP of 24 mm Hg within 3 days postoperatively. Fundus examination however on second day revealed multiple intraretinal hemorrhages at posterior pole (Fig 2;iv), suggestive of decompression retinopathy. Systemic anti-glaucoma medications were gradually withdrawn, topical timolol continued and 2% dorzolamide was subsequently added. Patient was also prescribed topical steroid-antibiotic combination routinely prescribed post cataract surgeries; although use of topical steroids is debatable in pregnancy (Category C), but the risk to benefit ratio in this eye with complicated cataract surgery with ensuing ODR compelled us to use topical steroids with intensive monitoring.

These haemorrhages resorbed over a two-week period and IOP control was sufficient for all anti-glaucoma drops to be withdrawn. Vision at 3 month post-op was documented to be 20/40 (Snellen equivalent 6/12), with IOP of 12 mm Hg. (Fig 2;v) Visual acuity and IOP remained stable over a 16 month follow up during which period the patient underwent normal vaginal term delivery of a healthy baby. At last follow up a 2 clock hours IOL capture was noted post parturition. (Fig 2;vi)

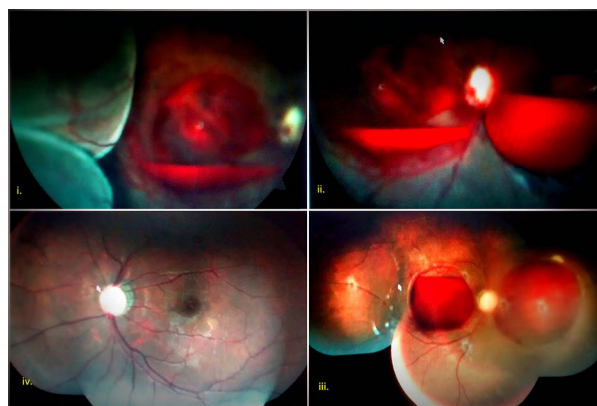


Figure 1: (L-R clockwise) OD: Fundus photographs of i,ii: 2nd Post op-day showing extensive choroidal detachment with subhyaloid and multiple intraretinal haemorrhages, iii: 15th post- op day showing ongoing resolution of choroidal detachment and haemorrhages OS: iv: 2nd post-op day with similar surgical protocol but no evidence of decompression retinopathy

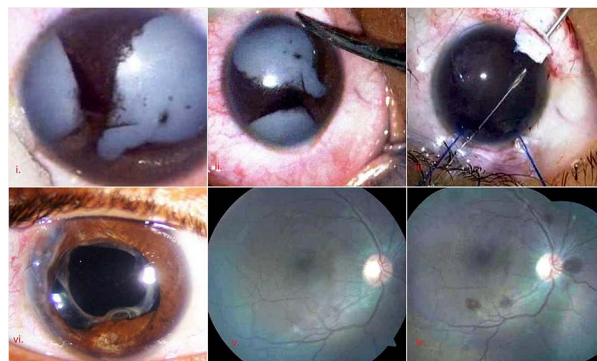


Figure 2: (L-R clockwise from top) i: pre-operative SLE showing 4-5 clock hours iridodialysis with subluxated cataractous lens, ii,iii: intra-operative; cataract extraction with cionni and IOL insertion, iv: 2nd post-operative day fundus photo showing multiple intra-retinal haemorrhages at posterior pole, v: 15th post-operative day fundus photo showing complete resolution of haemorrhages, vi: SLE at 16 months showing IOL capture

Discussion

Types of retinal bleeds after glaucoma surgery has been classified by Suzuki et al (1999) into three categories: small peripheral hemorrhages

seen after dilatation, massive benign bleed (ODR) and central retinal vein occlusion (CRVO)/ hemorrhagic retinopathy. The first entity and usually the second entity are usually self-limiting and relatively benign.

The clinical spectrum of ODR ranges from retinal haemorrhages to optic nerve changes. Haemorrhages have been reported to occur in all retinal layers with subhyaloid layer involvement seen in 33% cases and vitreous hemorrhage in 5% by Mukkamala et al (2013). Central retina involvement with peripapillary area being the most vulnerable is most common and occurs in 92% cases while peripheral extension of central haemorrhage is seen in almost 72% patients and Roth spots are seen in 20% cases as described by Karimdas et al (2002). Optic nerve head findings occur in nearly one fourth cases and include peripapillary nerve head haemorrhages, optic disc hyperemia and edema. Other unusual findings reported are choroidal detachment, serous retinal / macular detachment and macular edema as seen in case 1.

This complication occurs regardless of type of glaucoma, surgery or anesthesia and this is corroborated in our series with one case occurring under GA and other under LA. The glaucoma subtypes where ODR has been reported include primary open angle, buphthalmos, juvenile glaucoma, angle closure glaucoma and secondary glaucoma due to trauma, uveitis or neovascularization by Dudley et al (1996) and Fechner et al (1992).

Since lowering of IOP by medical means has also been reported in isolated cases by Gupta et al (2005), the common denominator appears to be sudden reduction of pressures causing rupture of retinal capillaries. Mukkamala et al (2013) have quantified this mean reduction of IOP to be 33 ± 16 mm Hg with mean time for diagnosis being 1.5 ± 2.0 days. This is borne out by case 2 who had the ODR findings on 2nd post-operative day.

The patho-physiology for ODR as enunciated

by Fechtner et al (1992) is increased retinal and choroidal blood flow subsequent to rapid lowering of IOP overwhelming retinal capillary bed capacitance leading to multiple focal endothelial leaks. Glaucomatous eyes have prior deranged retinal autoregulation and studies by Riva et al (1996) have confirmed poor autoregulation subsequent to low perfusion pressure and high IOP to be the potentiator for ODR.

The cause for ODR in our case series could not be explained on sudden decompression as IOP was recorded as normal immediately prior to surgery. We hypothesize valsalva retinopathy during extubation in case 1 (operated under GA) as a probable cause for ODR in case 1, further potentiated by hypotony in such eyes with retinal capillaries already vulnerable due to disturbed autoregulation. This has been previously reported in a child with developmental glaucoma by Mandal et al (2001). The concussion trauma sustained by the patient coupled with the altered blood flow profile during pregnancy could be the underlying cause for ODR in case 2.

The probable etiology for CRVO after trabeculectomy on the other hand is anterior shift of lamina cribrosa resulting in acute blockage of axonal transport post sudden decrease in IOP. Again, this type of bleed is more common in advanced disc damage case. Another explanation suggests that sudden drop in IOP causes anterior displacement and contraction of vitreous gel leading to quick detachment of posterior vitreous, thereby tearing small vessels on retinal surface.

While being confronted with a picture like ODR the differential diagnosis should include arteriosclerosis, hypertensive retinopathy, and vascular occlusions due to other cause, blood dyscrasias including leukemia, HIV retinopathy and battered baby syndrome.

Prognosis depends on the type of bleed with vascular occlusions causing ischemia and

irreversible vision loss with optic atrophy. On the other hand, hemorrhages associated with ODR are essentially benign and resolve without sequelae as described by Bansal et al (2009). Development of epiretinal membrane however is a poor prognosticator and can occur even after months of resolution of the bleed as stated by Dudley et al (1996).

In view of benign self-resolving nature of disease management should be conservative with surgical vitrectomy reserved only for visually significant, non-resolving vitreous or hyaloid bleeds. Kuruvilla et al (2015) described that non-resolving subhyaloid bleed can be treated with Nd YAG puncture known to successfully treat premacular hemorrhage secondary to valsalva retinopathy.

As intra and peri-operative hypotony is a proven cause for ODR prevention of this devastating entity involves certain pre-operative and operative measures. Preoperative precautions involve operating in quiet milieu with controlled IOP. Intra-operative precautions include controlled reduction of intraocular pressures by surgical step of creating an oblique and controlled paracentesis, placement of small amount viscoelastic in the AC prior to creation of sclerostomy, use of tight releasable sutures to avoid postoperative hypotony and bleb titration at end of surgery leaving AC formed with adequately pressurized globe.

Conclusion

Ocular decompression retinopathy is a rare, visually disabling entity seen after operations on cases with advanced glaucoma and those with vulnerable blood flow fluidics. Adequate precautions to prevent this entity should be adopted during surgery and management of the manifest entity is conservative with good prognosis.

References

Bansal Atul, Ramanathan U S. (2009). Ocular decompression retinopathy after trabeculectomy with mitomycin-C for angle

recession glaucoma. Indian Journal of Ophthalmology; 57(2) :153-4.

Dudley DF, Leen MM, Kinyoun JL, Mills RP. (1996). Retinal hemorrhages associated with ocular decompression after glaucoma surgery. Ophthalmic Surg Lasers; 27:147-50.

Fechner RD, Minckler D, Weinreb RN, Frangei G, Janpol LM. (1992). Complications of glaucoma surgery. Ocular decompression retinopathy. Arch Ophthalmol; 110: 965-8.

Gupta R, Browning AC, Amoaku WM. (2005). Multiple retinal haemorrhages (decompression retinopathy) following paracentesis for macular branch artery occlusion. Eye; 19:592-3.

Karadimas P, Papastathopoulos KI, Bouzas EA. (2002). Decompression retinopathy following filtration surgery. Ophthalmic Surg Lasers, 33:175-6.

Kuruvilla O, Munie M, Shah M, Desai U, Miller JA, Ober MD. (2014). Nd:YAG membranotomy for preretinal hemorrhage secondary to valsalva retinopathy. Saudi J Ophthalmol; 28 (2):145-51.

Mandal AK, Jalali S, Rao VS, Gothwal VK, Karim A. (2001). Valsalva retinopathy-like hemorrhage associated with combined trabeculotomy-trabeculectomy in a patient with developmental glaucoma. Ophthalmic Surg Lasers; 32(4):330-2.

Mukkamala SK, Patel A, Dorairaj S, McGlynn R, Sidoti PA, Weinreb RN, et al. (2013). Ocular decompression retinopathy: A review. Surv Ophthalmol; 58(6):505-12.

Riva CE, Grunwald JE, Petring BL (1986). Autoregulation of Human Retinal Blood Flow. Invest Ophthalmol Vis Sci; 27:1706-12.

Suzuki R, Nakayama M, Satoh N. (1999). Three types of retinal bleeding as a complication of hypotony after trabeculectomy. Ophthalmologica; 213: 135-8.

Source of financial disclosures: nil. Conflict of interest: declare