

Case report

Nocardia choroidal abscess-a Case report with Review of literature

Prachi Abhishek Dave¹, Manisha Agarwal¹, Neelam Sapra², Prajakta Kimmatkar³

¹Vitreoretina Services, Dr.Shroff's Charity Eye Hospital, 5027-Kedar Nath Road, Daryaganj, New- Delhi-110002.

²Microbiology Services, Dr.Shroff's Charity Eye Hospital, 5027-Kedar Nath Road, Daryaganj, New- Delhi-110002.

³Pediatric Services, Dr.Shroff's Charity Eye Hospital, 5027-Kedar Nath Road, Daryaganj, New- Delhi-110002.

Abstract

Introduction: Nocardia is a common cause of corneal infections but is a rare cause of choroidal abscess. We report a rare case of choroidal abscess, secondary to Nocardia and its management. **Case:** We report a case of choroidal abscess secondary to Nocardia asteroides species in an immunocompetent young male diagnosed by culture positivity of vitreous biopsy. He was managed by oral trimethoprim-sulfamethoxazole and intravitreal Amikacin injections. **Conclusion:** All the previous reported cases were found to be immunocompromised patients. However, our patient was immunocompetent and the confirmation of diagnosis was done by culture of vitreous biopsy in comparison to a retinochoroidal biopsy, in all other previous cases.

Key Words: Choroidal abscess, Nocardia asteroides, Intravitreal amikacin

Introduction

We report a case of choroidal abscess secondary to Nocardia Asteroides species in an immunocompetent male patient. The vitreous biopsy and culture confirmed the diagnosis thereby avoiding a retinochoroidal biopsy and its associated complications. The patient was managed by intravitreal and systemic antibiotics.

Case History

An 18 year old male patient presented with gradual painless diminution of vision in the left eye for last 6 months. There was no significant systemic history. On examination, the

best-corrected visual acuity (BCVA) in the right eye was 6/6, N6 and in the left eye hand movements close to face. Anterior segment examination showed a relative afferent papillary defect (RAPD) in the left eye. Fundus examination of the right eye was within normal limits and the left eye showed a yellowish sub-retinal lesion with sub-retinal fluid in the super-temporal quadrant and involving the macula (Fig 1 A). Ultrasound B-Scan of the left eye showed a sub-retinal mass measuring 11mm x 6.4 x 5.6 mm with increased surface reflectivity and medium to low internal reflectivity and overlying exudative retinal detachment. Fundus fluorescein angiography (FFA) of the left eye showed mottled hyperfluorescence within the lesion and pooling of the dye within the exudative detachment of the retina (Fig 1 C,D,E). OCT of the left

Received: 13/10/16

Accepted: 12/04/17

Corresponding Author

Dr.Prachi A Dave,
Vitreoretina Services,
Dr.Shroff's Charity Eye Hospital,
5027 Kedar Nath Road, Daryaganj-110002, New Delhi -110002. India
Email id: drpdjhala@gmail.com
Mobile: +91-7838178429

eye showed a subretinal elevated lesion with sub-retinal fluid (Fig 1B).

The patient was systemically evaluated and was found to have height and weight below the 5th percentile, mentally subnormal and skin showed Pityriasis Versicolor and the laboratory investigations showed haemoglobin-12gram%, total leucocyte count- 11300 cu.mm, erythrocyte sedimentation rate- 47 mm in 1st hour, mantoux test negative, HIV-1 and 2 was negative and he was immunocompetent. Contrast enhanced computed tomography (CECT) of the chest was within normal limits. A vitreous biopsy was performed using a 25-gauge vitrectomy cutter and an undiluted vitreous sample over the lesion was collected. Microbiological examination of the vitreous sample showed gram-positive filamentous organisms and culture on blood agar showed chalky white colonies suggestive of *Nocardia* species (Fig 2). Antibiotic sensitivity showed that the *Nocardia* species was sensitive to trimethoprim-sulfamethoxazole, amikacin and levofloxacin. Subsequently MRI brain was done to rule out intracranial Nocardiosis which was found to be normal.

The patient was treated with systemic trimethoprim- 160mg/day and sulphamethoxazole- 800mg/day and intravitreal injections of Amikacin (200 micrograms/0.05ml) and the patient responded well to the treatment.

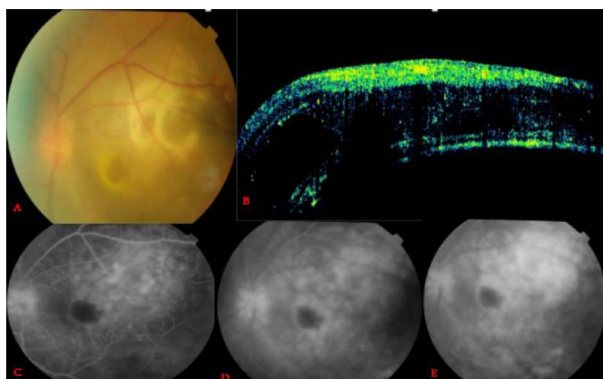


Fig. 1

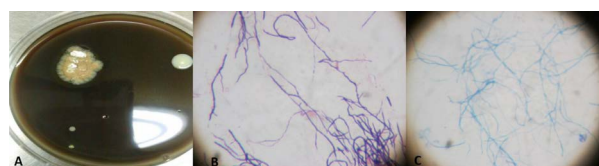

Fig. 2

Discussion

Nocardia infection in humans is very rare and often self-limiting. It is a slow growing, gram positive, variable acid-fast filamentous aerobic organism that inhabits the soil. The most common species causing human infection are *Nocardia brasiliensis* and *Nocardia asteroides* which is found in 90% of the cases. The most common presentation is a pneumonia-like illness confused with pulmonary tuberculosis or histoplasmosis and a subcutaneous abscess. Ocular nocardiosis can be classified by the mechanism of inoculation: exogenous infections generally occur post-traumatically whereas endogenous disease is secondary to hematogenous spread from distant sites (Silva et al,2015). The latter category is named as “metastatic nocardiosis.” The organism affects the cornea and sclera in the former category whereas in the latter category it leads to involvement of the choroid. *Nocardia* choroidal abscess is a rare disease entity with literature revealing only a few sporadic case reports (Phillips et al,1992; Bozbeyoglu et al,2004) . *Nocardial* choroidal abscess has been reported in immunocompromised individuals (Silva et al,2015; Phillips et al , 1992; Bozbeyoglu et al,2004). The diagnosis was confirmed by doing a retinochoroidal biopsy and microbiological examination in all the previously reported cases.

All the previously reported cases in literature showed low vitreous tap positivity for identifying *Nocardia* species (Eschle-Meniconi et al, 2011; Dodds et al, 2006) and they had to perform transvitreal retinochoroidal biopsy to confirm the diagnosis however in our case the diagnosis was made by culturing the vitreous

sample itself thereby avoiding a retinochoroidal biopsy and its associated complications such as retinal detachment. All the cases reported in literature were immunocompromised however our patient was immunocompetent (Silva et al, 2015; Phillips et al, 1992; Bozbeyoglu et al, 2004; Eschle-Meniconi et al, 2011; Dodds et al, 2006). Our case highlights the fact that *Nocardia* infection is not limited to immunocompromised state and may occur even in immunocompetent individuals. Our patient responded well to intravitreal Amikacin injections, which remains the treatment of choice, as the penetration of systemic antibiotics is poor into the choroid.

References:

Bozbeyoglu S, Yilmaz G, Akova YA (2004). Choroidal abscess due to nocardial infection in a renal allograft recipient. *Retina*; 24(1):164-6.

Dodds EM, Echandi LV, Puente SI, Kaufman S (2006). Subretinal abscess due to *Nocardia farcinica* resistant to trimethoprim- sulfamethoxazole in a patient with systemic lupus erythematosus. *Ocul Immunol Inflamm*; 14(4):249-51.

Eschle-Meniconi ME, Guex-Crosier Y, Wolfensberger TJ (2011). Endogenous ocular nocardiosis: an interventional case report with a review of the literature. *Surv Ophthalmol* ;56:383–415.

Phillips W, Shields C, Shields J, et al (1992). *Nocardia* Choroidal abscess. *British Journal Of Ophthalmology*; 76:694-696.

Silva R, Young R, Sridhar J et al (2015). *Nocardia* Choroidal abscess Risk factors, treatment strategies, and visual outcomes. *Retina*; 35:2137-2145.

Source(s) of support: nil. Commercial interest: nil