

Original article

Factors affecting the visual outcome of pediatric cataract surgery: a hospital based prospective study in eastern Nepal

Santosh Chaudhary, Poonam Lavaju, Bhuwan Govinda Shrestha, Sangeeta Shah,
Sanjib Kumar Chaudhary
Department of Ophthalmology, BP Koirala Institute of Health Science
Dharan, Nepal

Introduction

The World Health Organization's (WHO) global initiative for the elimination of avoidable blindness by the year 2020 (Thylefors et al., 1995) has prioritized the control of childhood blindness. Currently cataract remains one of the most important causes of treatable blindness in children (Giles et al., 2016).

An estimated 19 million children are visually impaired and 1.5 million are blind with 1 million children living in Asia and 300,000 in Africa (Visual impairment and blindness, 2014). Congenital cataract is responsible for about 10% of all visual loss in children. Kohler and Stoll have reported the prevalence of pediatric cataract to range from 1.2 to 6 cases per 10,000 births (Stoll et al., 1992).

In Nepal, as in other developing countries, cataract is believed to be a leading cause of blindness in children. According to The Nepal Blindness Survey from 1978 to 1980, congenital cataract accounted for 16.3% of blindness detected in children under the age of 15 years (Brilliant et al., 1985). Epidemiology of Blindness in Nepal 2012 survey has suggested that the prevalence of childhood blindness has reduced from 0.68% in 1981 to 0.4% in 2011 (Sapkota, 2012).

The visual outcome of cataract surgery in children have generally been poorer than in adults (Yamamoto et al., 1998) as blindness in children with cataract is not only attributed to cataract, but also to visual deprivation from early onset and delayed presentation, and thus delayed surgery, complications of surgery, and associated ocular abnormalities (Clare, 2009; Shrivastava, 2004).

With the limited number of studies regarding visual outcome following surgery in pediatric cataract in Nepal, we present a prospective study of the visual outcome of pediatric cataract surgery performed during 1-year period at a tertiary care center in Eastern Nepal.

Material and methods

All subjects up to 14 years of age who underwent cataract surgery in Department of Ophthalmology at BP Koirala Institute of Health Sciences during 1-year period was included in the study. Study was conducted after approval from the Institutional Review Board. All the procedures were carried out after obtaining consent from the guardian. Pediatric patients of age more than 14 years, traumatic and complicated cataract were excluded from the study. All data were entered in Microsoft Excel spreadsheet 2013 and converted into SPSS (Statistical Package for Social Science) version 17.0 program for statistical analysis.

Detailed demographic data, clinical history, general physical examination and detailed

Received: 21/1/17

Accepted: 13/06/17

Corresponding author

Santosh Chaudhary
Department of Ophthalmology, BP Koirala Institute of Health Sciences,
Dharan 18, Sunsari, Nepal
E-mail: infosantosh@gmail.com
Telephone number: +977-9852056887



ophthalmological examination was carried out as per pro forma. Preoperative and postoperative visual acuity for distance in each eye was measured using Snellen's distance visual acuity charts or Allen picture cards. In infants and preverbal children, visual acuity was measured based on fixation pattern. Visual acuity was then classified into 4 grades according to the WHO International Classifications of blindness and low vision (ICD-10, Update and Revision 2006) ("World Health Organization. International Statistical Classification of Diseases and Related Health Problems: Tenth Revision," 1992). Cataract morphology was studied after dilating pupil with topical tropicamide and phenylephrine drops. Posterior segment of eye was evaluated with the help of an indirect ophthalmoscope. Ultrasound B scan was done when fundus was not visible by indirect ophthalmoscopy. Posterior chamber IOL power was calculated using SRK-II formula in co-operative children where keratometry was possible. In young and unco-operative children, the axial length of eye was measured preoperatively under general anaesthesia (GA) on operation table and IOL power was calculated using the Dahan Formula (Dahan and Drusedau, 1997).

Surgery was performed by three ophthalmic surgeons under GA. Mydriasis was achieved with use of tropicamide and phenylephrine drops instilled 3 times every 10 minutes before surgery. A continuous curvilinear capsulorhexis (CCC) was done followed by hydrodissection and lens aspiration. Primary posterior capsulotomy (PPC) and anterior vitrectomy was performed in patients younger than 8 years. Children younger than 2 years with bilateral cataract were left aphakic and prescribed aphakic glasses based on retinoscopy findings and with unilateral cases, PCIOL was implanted at same setting. In children, older than 2 years, non-foldable PMMA PCIOL was implanted at the time of surgery. At the end

of procedure, nylon 10-0 interrupted suture was applied and subconjunctival injection of dexamethasone 2mg and gentamicin 10mg was administered.

Postoperatively, all children received 1% prednisolone eye drop 2 hourly, tapered and eventually discontinued after 6 weeks, tobramycin and atropine eye drops. Aphakic glasses were prescribed for visual rehabilitation in all patients with aphakia based on retinoscopy findings. Children with unilateral cataract received occlusion therapy for amblyopia postoperatively. Visual outcome at each follow up (1st week, 1st month, 3rd month and 6th month) was evaluated with respect to laterality, aphakic/ pseudophakic status, age, requirement for additional surgeries and Nd:YAG laser, cataract morphology, presence or absence of strabismus and nystagmus, retinoscopy, refractive error and ocular findings.

Results

A total of 51 eyes of 30 children under 14 years underwent cataract surgery during the study period. There were 17 males (56.7%) and 13 females (43.3%). The mean age of presentation was 3.84 ± 3.14 years. The details of patient demographic and clinical characteristics are summarized in Table 1.

Table 1: Baseline Demographics and Clinical Characteristics of patients

Characteristics	
Age N (%)	
<2 years	8 (26.7%)
2 to <5 years	12 (40.0%)
5 to <8 years	8 (26.7%)
8 to <14 years	2 (6.7%)
Gender N (%)	
Male	17 (56.7%)
Female	13 (43.3%)
Residential Status N (%)	
Rural	28 (93.3%)
Urban	2 (6.7%)
Mode of Presentation N (%)	

Diminution of vision	16 (53.3%)
Leukocoria	14 (46.7%)
Duration of Symptoms to Surgery N (%)	
<6 months	20 (66.7%)
6-12 months	3 (10%)
>1 years	7 (23%)
Laterality N (%)	
Unilateral	6 (20%)
Bilateral	24 (80%)
Nystagmus	13 (43.3%)
Strabismus	6 (20%)
Cataract Morphology N (%)	
Zonular	32 (62.7%)
Total	13 (25.5%)
Others	Posterior subcapsular cataract - 4, Blue dot cataract - 1, membranous cataract - 1
Follow-up	Mean 3.03 ± 2.41 months (Range 1 month to 11 months)

Fifteen eyes (29.4%) of 8 children (<2 years of age) underwent lens aspiration with posterior capsulotomy and anterior vitrectomy while in patients more than 2 years of age (36 eyes), 32 eyes (62.7%) underwent lens aspiration with PCIOL implantation and 4 eyes (7.8%) underwent lens aspiration with posterior capsulotomy, anterior vitrectomy and PCIOL implantation.

Table 2 illustrates change in visual status post-operatively

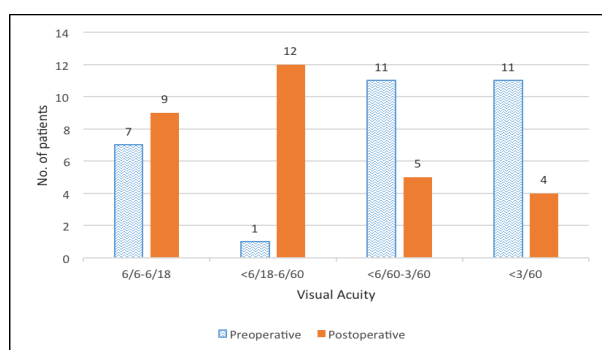


Table 2: Comparison of preoperative and postoperative Best Corrected Visual Acuity at last follow-up

There was significant improvement in best corrected visual acuities (BCVA) following surgery (P=0.001). Preoperatively eight patients (26.7%) had visual acuity (VA) >6/60 while 11 patients (36.7%) were blind (VA<3/60). Postoperatively, 21 patients (70%) had VA >6/60 and only 4 patients (13.3%) were blind. Visual improvement was seen in 35 eyes (68.6%) following surgery.

Most common postoperative complication was visual axis opacification 29 (39%). Twenty seven of 36 eyes developed visual axis opacification when PPC was not done while only 2 of 15 eyes developed visual axis opacification when PPC was done. A significant correlation was seen between PPC and absence of visual axis opacification (P<0.001). Other complications were fibrinous uveitis in 2 cases (3.9%) at 1st postoperative day, optic capture and decentered IOL was seen in 1 case (1.95%) each at last follow-up.

Nine eyes (17.6%) required Nd:YAG capsulotomy for visually significant PCO. Four eyes (7.8%) needed additional surgical procedure under general anaesthesia (membranectomy in two eyes, loose suture removal at side port in one eye and examination under general anaesthesia for decentered IOL in one eye).

Discussion

Any opacification of the lens and its capsule in children less than 14 years of age is defined as pediatric cataract. Visual prognosis of children with congenital cataracts has improved dramatically these days because of early detection, prompt treatment and amblyopia management, advances in microsurgical techniques and instrumentation, and IOL developments (Hing et al., 1990; Lundvall and Kugelberg, 2002). We performed a prospective

study of cataract surgery performed in children below 14 years over 1 year period.

The study showed that treatment significantly improved vision postoperatively ($P=0.001$) with 30% children achieving 6/18 or better and 70% children achieving 6/60 or better, which is similar to a study done in tertiary center in Kathmandu (Thakur et al., 2004). The visual outcome was better than the study done in tertiary eye center Lahan (Wilson et al., 2010) and poor than study done by Bowman in Tanzanian children (Bowman et al., 2007) and Cassidy in London (Cassidy et al., 2001). There was a significant correlation between preoperative vision and improvement of vision postoperatively ($P=0.001$) which is similar to study done by Bowman et al where preoperative blindness was the strongest predictor of poor postoperative visual outcome (Bowman et al., 2007).

The mean age of children was 3.84 ± 3.14 years. Age at presentation has a significant effect on visual outcome ($P=0.001$) with better visual outcome in children more than 2 years. This is similar to other studies (Shah et al., 2012; Yang et al., 2006) while studies done by Lim Z, The Toronto Experience (Lim et al., 2012) and Tomkins et al (2011) showed no relationship between final visual acuity and age at presentation. Fifty seven percent were male (M:F=1.3:1). Sex had no correlation with visual outcome ($P=0.286$). Though there is no evidence that the incidence of childhood cataract is more in males, more males were brought for surgery. This may be because the parents concern for their sons which is common in many parts of developing world including ours.

Duration of symptoms to surgery has no significant association with visual outcome ($P = 0.68$) which is different from study done by Thakur et al (2004), in which it is stated that late presentation leading to deprivation

amblyopia was the primary cause of a poor visual outcome.

Eighty percent of cases were bilateral in this study but had no significant association with visual improvement postoperatively ($P=0.912$) similar to Lim et al (2012) but other studies suggests that visual outcome was better in bilateral than in unilateral cases (Cassidy et al., 2001; Hochstrasser and Gloor, 1994; Shah et al., 2012). Presence of nystagmus has poor visual outcome ($P=0.022$) similar to other studies (Tomkins et al., 2011; Wilson et al., 2010) but Young et al (2012) and Bradford et al (1994) has suggested that its presence is not a poor prognostic factor. Presence of strabismus has no significant correlation with visual outcome ($P=0.64$). Morphological forms of cataract had no significant association with visual outcome ($P=0.64$) but in study done by Shah et al (2012) lamellar cataract had significantly better outcome, However Lim et al (2012) found better outcome with posterior subcapsular cataract. My study did not show any correlation. This may be due to smaller number of cases in my study.

Bowman et al (2007), Shah et al (2012) and Hochstrasser et al (1994) has shown that insertion of IOL resulted in significant improvement in visual outcome. Our study did not show significant correlation with postoperative final visual outcome in relation to IOL implantation or aphakia ($P=0.129$), this may be due to early correction of aphakia with glasses in aphakic cases and amblyopia therapy.

Visual axis opacification is the most common complication following pediatric cataract surgery. The incidence of PCO is nearly 100% in infants not undergoing PPC and anterior vitrectomy (Kim et al., 2008). In our study, it was seen that 75% of eyes, which did not undergo PPC, developed PCO while only 11.76%, which underwent PPC, developed PCO.

Conclusion

Cataract is a leading cause of blindness in children in the developing world. Cataract surgery significantly improves vision in pediatric patients. Early age of presentation, presence of nystagmus and poor preoperative visual acuity were found to be significantly associated with poor visual outcome postoperatively while sex, duration, laterality, strabismus, cataract morphology and IOL implantation had no association visual outcome. Primary posterior capsulotomy with anterior vitrectomy significantly reduces the chance of visual axis opacification.

Limitations include smaller sample size and difficulty in actual quantification of visual acuity in preverbal children. Long term visual outcome was also not evaluated due to short follow-up duration of 6 months.

Reference

Bowman RJC, Kabiru J, Negretti G, Wood ML (2007). Outcomes of Bilateral Cataract Surgery in Tanzanian Children Ophthalmology;114:2287–2292.

Bradford GM, Keech RV, Scott WE (1994). Factors affecting visual outcome after surgery for bilateral congenital cataracts. Am. J. Ophthalmol; 11:58–64.

Brilliant LB, Pokhrel RP, Grasset NC et al (1985). Epidemiology of blindness in Nepal. Bull. World Health Organ; 63:375–386.

Cassidy L, Rahi J, Nischal K, Russell-Eggitt I, Taylor D (2001). Outcome of lens aspiration and intraocular lens implantation in children aged 5 years and under. Br. J. Ophthalmol;85:540–2.

Clare G (2009). Worldwide causes of blindness in children, in: Pediatric Ophthalmology: Current Thought and A Practical Guide. Springer, Berlin: 47–60.

Dahan E, Drusedau MU (1997).

Choice of lens and dioptric power in pediatric pseudophakia. J. Cataract Refract; Surg. 23 Suppl 1:618–623.

Giles K, Christelle D, Yannick B, Fricke OH, Wiedemann P (2016). Cataract surgery with intraocular lens implantation in children aged 5-15 in local anaesthesia: visual outcomes and complications. Pan Afr. Med. J; 24:200.

Hing S, Speedwell L, Taylor D (1990). Lens surgery in infancy and childhood. Br. J. Ophthalmol; 74:73–77.

Hochstrasser P, Gloor B (1994). Surgical results of uni- and bilateral congenital and traumatic cataract in infancy to adolescence. Klin. Monbl. Augenheilkd;204:274–8.

Kim KH, Ahn K, Chung ES, Chung TY (2008). Clinical outcomes of surgical techniques in congenital cataracts. Korean J. Ophthalmol; 22:87–91.

Lim Z, Rubab S, Chan YH, Levin AV (2012). Management and outcomes of cataract in children: the Toronto experience. J. AAPOS; 16:249–54.

Lundvall A, Kugelberg U (2002). Outcome after treatment of congenital bilateral cataract. Acta Ophthalmol. Scand; 80:593–597.

Sapkota YD (2012). Epidemiology of Blindness in Nepal. 1:3.

Shah MA, Shah SM, Shikhangi KA, Upadhyay PR, Bardoloi GB (2012). Factors Affecting Visual Outcome Following Surgical Treatment of Cataracts in Children. Open Journal of Ophthalmology; 2(4):131–139.

Shrivastava K (2004). Childhood Cataracts: Aetiology and Management. Community Eye Health. 17:33–36.

Stoll C, Alembik Y, Dott B, Roth MP (1992). Epidemiology of congenital eye malformations in 131,760 consecutive births. Ophthalmic Paediatr. Genet. 13:179–86.



Thakur J, Reddy H, Wilson ME, Paudyal G, Gurung R, Thapa S, Tabin G, Ruit S (2004). Pediatric cataract surgery in Nepal. *J. Cataract Refract. Surg.* 30:1629–35.

Thylefors B, Négrel AD, Pararajasegaram R, Dadzie KY (1995). Global data on blindness. *Bull. World Health Organ.* 73:115–121.

Tomkins O, Ben-Zion I, Moore DB, Helveston EE (2011). Outcomes of pediatric cataract surgery at a tertiary care center in rural southern Ethiopia. *Arch. Ophthalmol.* 129:1293–7.

Visual impairment and blindness [WWW Document] (2014). URL <http://www.who.int/mediacentre/factsheets/fs282/en/> (accessed 12.5.16).

Wilson ME, Hennig, A, Trivedi RH, Thomas BJ, Singh SK (2010). Clinical characteristics and early postoperative outcomes of pediatric cataract surgery with IOL implantation from Lahan, Nepal. *J. Pediatr. Ophthalmol. Strabismus* 48:286–91.

World Health Organization. International Statistical Classification of Diseases and Related Health Problems: Tenth Revision [WWW Document], 1992. URL <http://www.who.int/classifications/icd/en/>

Yamamoto M, Dogru M, Nakamura M, Shirabe H, Tsukahara Y, Sekiya Y (1998). Visual function following congenital cataract surgery. *Jpn. J. Ophthalmol.* 42:411–6.

Yang ML, Hou CH, Lee JS, Liang YS, Kao LY, Lin KK (2006). Clinical characteristics and surgical outcomes of pediatric cataract in Taiwan. *Graefes Arch. Clin. Exp. Ophthalmol.* 244:1485–90.

Young MP, Heidary G, VanderVeen DK (2012). Relationship between the timing of cataract surgery and development of nystagmus in patients with bilateral infantile cataracts. *J. AAPOS* 16:554–7.