

## Letter to editor

### Uveitis- Glaucoma-Hyphema Syndrome

Zvi Gur<sup>1</sup>, ErezTsumei<sup>1</sup>, Asaf Achiron<sup>2</sup>

<sup>1</sup>Department of Ophthalmology, Soroka University Medical Center, Ben Gurion University of the Negev, Beer Sheva, Israel.

<sup>2</sup>Department of Ophthalmology, Edith Wolfson Medical Center, Holon, Israel

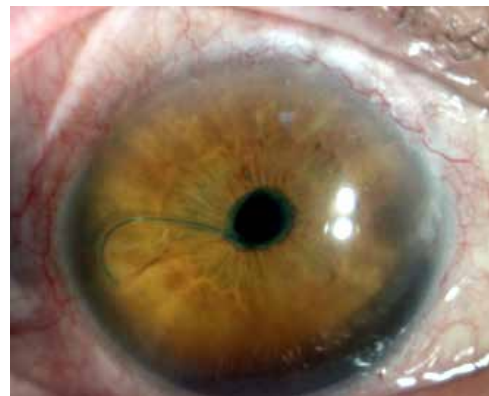
Twenty years after undergoing an operation to simultaneously repair a traumatic retinal detachment and extract a cataract, a 66-year-old man arrived at our outpatient clinic complaining of pain and deteriorating vision in his right eye. Upon examination, we found that the intraocular lens (IOL) was sub luxated with its stabilizing haptic protruding through the pupil. The constant irritation of the iris had caused an inflammatory reaction in the anterior chamber, diffuse hyphema (mainly at lower anterior chamber) and increased intraocular pressure. This uveitis-glaucoma-hyphema (UGH) syndrome is a rare post-operative complication caused by mechanical rubbing of the IOL against the vascular iris (Zhang et al, 2014). Conservative treatment with cycloplegic and steroidal eye drops is an option, but the definitive treatment is surgical removal of the IOL (Sousa et al, 2016). Extra care should be taken near the inflammatory scars between the IOL and other intraocular structures. Delaying the removal of the IOL can result in macular edema and corneal decompensation (Arthur et al. 2009).

#### References

Arthur SN, MM Wright, N Kramarevsky, SC Kaufman & ALGrajewski (2009): Uveitis-Glaucoma-Hyphema Syndrome and Corneal Decompensation in Association With Cosmetic Iris Implants. American journal of ophthalmology 148: 790-793.

Sousa DC, I Leal, MY Faria & LA Pinto (2016): A Rare Manifestation of Uveitis-glaucoma-hyphema Syndrome. Journal of Current Glaucoma Practice 10: 76-78.

Zhang L, CT Hood, JP Vrabc, AL Cullen, EA Parrish & SEMoroi (2014): Mechanisms for in-the-bag uveitis-glaucoma-hyphema syndrome. Journal of Cataract & Refractive Surgery 40: 490-492.



#### Address for correspondence

Zvi Gur, MD  
Department of Ophthalmology, Soroka University Medical Center, Beer Sheva, Israel.  
Address: 151 ShderotltzahkRager, Beer Sheva, Israel, 84101  
Tel: +972-8-6400761; Fax: +972-8-6403927  
Email: zvigur@hotmail.com