

Original article

## Eye changes among HIV positive patients on antiretroviral therapy in Nepal

Labh RK<sup>1</sup>, Chaudhary M<sup>2</sup>, Shah DN<sup>2</sup>

<sup>1</sup>Biratnagar Eye Hospital, Biratnagar, Nepal

<sup>2</sup>B.P. Koirala Lions Centre for Ophthalmic Studies, Kathmandu, Nepal

### Abstract

**Background:** HIV/AIDS has various ocular manifestations. **Objective:** To find out eye findings among HIV positive patients in the era of antiretroviral therapy. **Method** This Hospital based cross sectional descriptive study was carried at B. P. Koirala Lions Centre for Ophthalmic Studies. Patient profile, WHO clinical stage, CD4+ cell count, duration of HIV, antiretroviral therapy, and systemic diseases were recorded. All the cases underwent ocular examination as per the study protocol and the findings were noted in a proforma developed for the study. The results were analysed with SPSS 14.0. **Results:** Of 100 HIV positive cases (including 55 antiretroviral therapy patients) 62% patients were male and 38% were female. The mean age of presentation was 27.72 years. Heterosexual transmission (62%) was the commonest mode of transmission of HIV. Thirty seven percent patients were illiterate. Systemic disease was present in 20% cases. Ocular complaint was present in 53% patients. Ocular disease was present in 40% HIV positive patients. Almost 55% of these cases were on antiretroviral therapy. Moderate to lower CD4 count patient had frequent eye disease. Patients in WHO Stage III and IV also had frequent eye problems. Anterior segment and external ocular disorder was present in 25% patients. The commonest manifestation was conjunctivitis in 10% of total cases. Posterior segment manifestation was present in 11%, neuro-ophthalmic lesion in 4% and orbital lesion in 1% patient. **Conclusion:** Anterior segment manifestation is still common ocular manifestations in HIV positive patients in Nepal. Patients in WHO Stage III and IV are more vulnerable for eye changes. Young aged male and migrant workers are at risk of acquiring HIV in developing country like Nepal. Eye findings even in patients on antiretroviral therapy are similar. However, large sample size and long follow up study is required to have final disclosure.

**Keywords:** Acquired immune deficiency syndrome, antiretroviral therapy, cytomegalovirus retinitis, human immune virus, immune recovery uveitis

### Introduction

HIV is caused by a retrovirus, known as human immunodeficiency virus (Weiss,

1993). Transmission of HIV occurs through the exchange of body fluids, sexual contact with infected partners, direct exposure to contaminated blood or blood products, or perinatal transmission from infected mothers to their offspring (Wynn, 2000).

Received: 10/09/15

Accepted: 03/12/15

#### Address for Correspondence

Dr. Rajan Kumar Labh  
Ophthalmologist  
Biratnagar Eye Hospital, Biratnagar, Nepal  
Email: rajan.labh@yahoo.com

Worldwide, according to United Nations Program on HIV/AIDS, an estimated 35.3 million people are infected with HIV by 2012 (JUNP on HIV/AIDS, 2013). In Nepal, 25222, HIV positive cases have been reported until July 2014 by National Centre for AIDS and STD control (NCASC, 2014).

HIV has the ability to affect every organ and system of the body directly or indirectly by making the host susceptible to opportunistic infections. Ocular manifestations have been reported in 70-80% of individuals infected with HIV, and can involve any ocular structures anterior to posterior (Holland, 1992; Biswas et al, 2000). Since, the introduction of highly active antiretroviral therapy (HAART) in late 1996, there is marked case reduction in acquired immune deficiency syndrome (AIDS) -related morbidity and mortality (Jabs, 1997, 2002; Jacobson, 1997, 2000; Palella et al, 1998).

So far relatively few studies have been done in developing countries on ocular manifestations of HIV patient on antiretroviral therapy (ART). Most of the studies have shown reduced incidence and prevalence of ocular manifestations in patients on HAART in different places (Palella et al, 1998; Jacobson et al, 1997; Song et al, 2000; Lin et al, 2002; Torriani et al, 2000). Nepal is now going through a transition phase, and with the introduction of voluntary counseling and testing center (VCTC) and the provision of HAART free of cost to HIV-infected patients, the spectrum of ophthalmological manifestations may have varied. Thus, this study has been undertaken to understand the profile of the HIV-positive/AIDS patients, various types and magnitude of ocular manifestations, on ARV therapy, and to look for variation from the other studies done elsewhere.

### Materials and methods

This descriptive single center cross-sectional study was done at BP Koirala Lions Center for Ophthalmic Studies (BPKLCOS), Tribhuvan

University Teaching Hospital (TUTH) from 1<sup>st</sup> March 2009- 28<sup>th</sup> February 2011. All diagnosed HIV/AIDS cases presenting to BPKLCOS, and other departments of TUTH were included while patients with pre-existing eye disease (Diabetes, Hypertension, other known complications of ocular diseases) and unwilling to participate in the study were excluded. Informed verbal consent was taken from the patient before enrolling them in the study.

Detail history was taken from the patients and from guardians in case of small children. Profile of patient (age, sex, occupation, education, marital status, migration, address) was documented. Duration of HIV infection, CD4+ count, ART status, duration of ART, mode of transmission of HIV infection, WHO staging associated systemic illness present or not were also mentioned.

Visual acuity was assessed by Snellen vision box with multiple optotypes for literate, E-chart for illiterate and Catford drum in case of children. Extra ocular movement and a cover test were done with torch light. Periorbital region/ lids and adnexa examination performed in day light / bright and focused torch light. Anterior segment examined using Haag-Streit 900 slit lamp. Detail fundus examination was performed under mydriasis with Heine Beta 200 direct ophthalmoscope, binocular indirect ophthalmoscope with +20D lens, +90D lenses and Haag-Streit 900 slit lamp in all the cases. Other investigations were done as per requirement. These cases were recorded in the proforma and statistical analysis was done with the help of SPSS 14.0.

### Results

There were 100 cases enrolled in the study during this period and 55 of them were receiving ART. They were 62(62%) males and 38(38%) females. Their mean age of presentation was 27.72 years (SD<sup>+</sup>- 13.79). Most of the patients were in their fourth decade (39%) (Table 1).

Of this number 62% acquired HIV through heterosexual transmission, remaining 26% and 12% acquired HIV through vertical and intravenous route respectively. Participants were engaged as laborer (29%), housewives (27%), students (16%), office staff (12%) and drivers (3%). Among them, 17% were migrant workers. India followed by Gulf country was their common migrating destination. Literally, literacy was poor with only 7% participants' pursuing their education till secondary school level. Large numbers of participant (74%) were just primary school level educated.

**Table 1: showing age distribution of cases with most of the patients in younger age**

Age group	Gender		Total	Percent (%)
	Male	Female		
0-10 years	17 (17%)	08 (8%)	25	25
11-20 years	02 (2%)	00 (0%)	02	02
21-30 years	11 (11%)	09 (9%)	20	20
31-40 years	23 (23%)	16 (16%)	39	39
41-50 years	07 (7%)	03 (3%)	10	10

**Table 2: CD4 Lymphocyte count among ART receiving patient with most of the patient ranging their CD4 count 200-499.**

CD4+ Count (cells/mm <sup>3</sup> )	ART		Total	Remarks
	Yes (%)	No (%)		
>500	05 (55.55%)	04 (44.45%)	09	5 persons not having record of CD4 count are not included here
200-499	30 (52.63%)	27 (47.37%)	57	
51-199	17 (77.27%)	05 (22.73%)	22	
<50	03 (42.85%)	04 (57.15%)	07	
Total	55	40	95	

Nearly 93% and 96% patient had their vision better than 6/60 in right and left eyes respectively (Table 3). There were two patients with visual impairment and one blind patient.

**Table 3: showing visual acuity of the patients with only some percentage of the patients showing poor vision**

Visual Acuity	Right eye	Percent (%)	Left eye	Percent
6/6-6/18	92	92	89	89
<6/18-6/60	01	01	07	07
<6/60-3/60	01	01	00	00
<3/60-CFCF	03	03	02	02
PL	02	02	02	02
NPL	01	01	00	00
Total	100	100	100	100

<b>51-60 years</b>	02 (2%)	02 (2%)	04	04
<b>Total</b>	62 (62%)	38 (38%)	100	100

Majority of the patients (86/100) were in WHO clinical stage I and II of the disease and the remaining 14% (14/100) patients were in clinical stage III and IV of the disease. An ocular disease was present in 70% (9/14) of WHO stage III and IV patient. Most of an ocular disease patient 65% (6/9) was on ART.

Ninety-five percent patients had their CD4 count done. Among them, 10% patients had CD4 count more than (>) 500cells/mm<sup>3</sup>, 60% patients had CD4 count between 200-500 cells/mm<sup>3</sup>, 23% patient had CD4 count between 51-199 cells/mm<sup>3</sup> and 7% patient had CD4 count less than (<) 50 cells/mm<sup>3</sup>. The CD4 count among those patients who were receiving ART has been mentioned in Table 2.

Clinically 53% (53/100) patients presented with some ocular complaint. Diminution of vision 45% (24/53), watering (24%), redness (24%), and foreign body sensation (17%) were some of them. Of this number 55% (29/53) were receiving an ART.

Ocular disease was present in 40% (40/100) of cases. Of them, 55% (22/40) patients were

receiving ART. Anterior segment and external ocular disorder were involved in 25% (25/100) of the cases. In an anterior segment, bacterial conjunctivitis 40% (10/25) was a common eye disease. Bacterial conjunctivitis was also a common ocular disease in ART receiving patients 27% (6/22). Further details of anterior segment finding have been mentioned in Table 4.

**Table 4: showing anterior segment disease of the patients and their CD4 cell count. The asterisk (\*) sign denotes the patient receiving ART. Most of the patients were receiving ART only for shorter duration (less than 3 months).**

Ocular Disease	CD4+ T Lymphocyte Count (cells/mm <sup>3</sup> )				Total
	>500	200-499	51-199	<50	
Conjunctivitis	02(1*)	06(3*)	02*	00	10
Dry Eye	00	02(1*)	00	00	02
Conjunctival Squamous Cell Carcinoma	00	00	01	00	01
Blepharitis	00	04(1*)	01*	00	05
Corneal Ulcer	00	00	00	01	01
HerpesZosterOphthalmicus	01*	00	00	00	01
Keratopathy	00	00	01*	01	02
Anterior Uveitis	00	01*	01	00	02
Immune Recovery Uveitis	00	00	00	01*	01

Similarly, the posterior segment was involved in 11% (11/100) patients, 27% (11/40) of an ocular diseased patient and 14% (6/55) of an ART patient. CMV retinitis was diagnosed in three

patients; two patients had a HIV retinopathy. Detail of posterior segment findings among ART receiving and non-receiving cases has been given in table- 5.

**Table 5: showing posterior segment and neuro-ophthalmic disease of the patient and their CD4 cell count. The asterisk (\*) sign denotes patients on ART.**

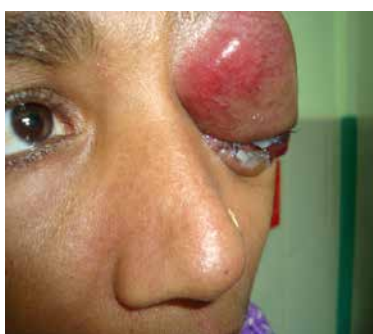Ocular Disease	CD4+ T Lymphocyte Count (cells/mm <sup>3</sup> )				Total
	>500	200-499	51-199	<50	
Retinal Vasculitis	00	01	00	00	01
CMV retinitis	00	01*	01	01*	03
HIV retinopathy	00	00	01	01*	02
Choroiditis	00	01	00	00	01
Retinal Detachment	00	02	02*	00	04
Disc Edema	00	01	00	00	01
Optic Neuropathy	00	01	00	01*	02
Ocular motor nerve palsy	00	00	01*	00	01

Out of total 100 HIV positive patients 55(55%) were receiving ART. Among them, 24(43.63%) were receiving ART for less than 3 months and only 1(1.8%) was receiving ART for more than 5 years. Minimum duration for receiving

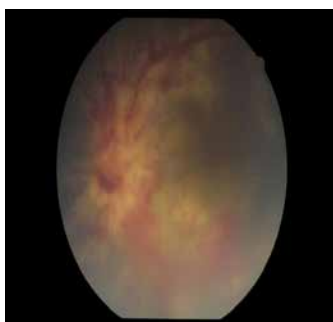
ART was 1 week and maximum duration for receiving ART was 96 month. Mean duration of ART was 6.71 month (SD+/-14.14 month). Of them 43% (24/55) patient was on ART for less than 3 months.

Neuro-ophthalmic related lesions were present in 4% (4/100) patient. There were cases of optic neuropathy, third nerve palsy and disc edema. A female had histopathologically proven large cell NHL. She was on ART for 18 months.

Systemic disease was present in 20% (20/100) cases. Pulmonary tuberculosis 60% (12/20) was the most common systemic infection, 10% patient had pneumonia, and 10% had liver disease. A case each of meningitis and herpes zoster ophthalmicus was also present.



**Figure 1:** Case of NHL



**Figure 2:** CMV Retinitis

### Discussion

The spectrum of eye changes in HIV and AIDS patients depends on several factors like availability of healthcare facility, variation in diseases patterns, status of the disease, awareness, literacy etc. Ninety percent of individuals with AIDS live in developing countries of sub-Saharan Africa, Indian Subcontinent, Latin America and Southeast Asia (Susan et al, 1997). In Nepal, 22000 peoples are living with HIV (NCASC, 2014). Due to their lower socio-economic status;

many patients are predicted to die in a relatively earlier phase of the disease, before developing any opportunistic infection (Biswas et al, 2000).

Most of the people acquired HIV in younger age. Similar younger age people were also reported in other studies done in this subcontinent (Gharai et al, 2008; Lamichhane et al, 2010). Some studies in other African Nations also had younger age involvement (Ayena et al, 2010; Azonobiet al, 2013).

We had mostly younger aged male being infected with HIV than their female counterpart which was also similar to other studies done in this subcontinent and elsewhere (Gharai et al, 2008; Shah et al, 2009; Lamichhane et al, 2010; Ayena et al, 2010; Azonobiet al, 2013).

In Nepal, HIV infected patients usually do not undergo routine ophthalmic evaluation and are usually referred for ophthalmic examination only if they have any ophthalmic symptoms. Thus, the sample size in this study is just representation of small number of HIV positive patients who presented to this hospital for routine checkup. Therefore it is difficult to comment rigidly on the mode of transmission of HIV; however, even with a smaller sample size we had most of the cases with heterosexual transmission. Surprising results were cases of intravenous transmission of HIV. These patients were mostly young male and indulged in such activities because of friends. Similar other studies done in different developing and developed countries also had reported more heterosexual transmission (Biswas et al, 2000; Sriprakash et al, 2004). On the other side, study done in United States of America (USA) reported homosexual transmission in 60% cases (Jabs, 1995).

Nepal has a lot of population working as migrant worker. According to data published by National Centre for AIDS and STD Control, Nepal, seasonal labor migrants accounted for 41% of the high risk cases (UNPHA, 2008).

This might be reason for higher number of migrant workers presenting as HIV positive cases in this study.

Awareness of HIV positive people regarding ocular involvement is less in Nepal and most of the patients present only when they have any ocular complaint. These complaints are varied and point towards the visual status and diagnosis. We had most of the patients with good vision. This might be due to the fact that these patients were mostly from the capital city of Nepal and they routinely visit the ART center available in the hospital. There is study from this subcontinent where almost similar visual status was present in the patients (Biswas et al, 2000).

Anterior segment manifestations of HIV occur in about 50% of HIV infected patients and include dry eye, infectious keratitis and iridocyclitis (Biswas et al, 2008). Here we had anterior segment disorders commonly in the form of conjunctivitis (40%) and blepharitis (20%). These are basically nonspecific disorders. Two cases of dry eyes and one case of herpes zoster ophthalmicus (HZO) was also present. Dry eye usually occurs in about 20% of HIV positive patients usually in the later stages of illness (Shukla et al, 2007). HZO affects about 5-15% of patients infected with HIV. It occurs early in the course of HIV infection when the CD4 count is  $> 200$  cells/mm<sup>3</sup>. We had 6 years child with HZO and CD4 cell count 246 cells/mm<sup>3</sup>.

Varicella zoster virus and Herpes simplex virus most commonly cause infectious keratitis in HIV positive patients (Sirkul et al, 2008). However, the frequency of bacterial and fungal keratitis is also similar to that in immunocompetent individuals but it tends to be more severe. The most common fungal organism is candida especially in intravenous drug abusers (Govender et al, 2010). Microsporidia has emerged as an important opportunistic protozoan in HIV positive patients (Joseph et

al, 2005). Corneal ulcer in this study was also fungal, positive for candida in culture. There was not a single case of microsporidia present in this study. However, there was a case of viral keratopathy as well.

Uveitis is one of the earlier sign of various chronic infections seen in HIV positive patient (Govender et al, 2010). Mild form of iridocyclitis is usually associated with retinitis due to CMV or VZV (Govender et al, 2010). We had cases of anterior uveitis among the both ART receiving and ART non receiving group. These patients did not have any associated retinitis and were neither taking medications like rifabutin or cidofovir.

Conjunctivitis was a common ocular manifestations presenting as 25% eye disease in HIV patients. A study from Tanzania and Togo also reported (conjunctivitis, blepharitis) as common nonspecific ocular manifestations 53% and 56.8% respectively among HIV patients (Sahoo, 2010; Ayena et al, 2010). However, similar study done in Nigeria had conjunctivitis in just 4.8% cases (Azonobiet al, 2013). The higher percentage of conjunctivitis in this study might be due to opportunistic infection and seasonal variation.

Posterior segment manifestations occur in 10% to 50% of HIV infected individuals, mostly in form of micro-vasculopathy (Biswas et al, 2000; Joseph et al, 2005; Sahoo, 2010; Govender et al, 2010). In 11% patients posterior segment involvement was there in this study and almost half of the patients were receiving ART. Various cross sectional and other studies have shown cotton wool spot as the most common micro-vasculopathy present in HIV patients (Freeman, 1984; Biswas et al, 2000; Sahoo, 2010; Govender et al, 2010). However, we had only one case of HIV retinopathy. This might be due to fact that most of the patient were in early stage of HIV.

CMV retinitis is a most common ocular opportunistic infection. It has been reported in



15-40% patients (Shukla et al, 2007; Govender et al 2010). In pre HAART era mortality due to CMV was high but post HAART era incidence of CMV retinitis has declined and survival rate has increased (Goldberg et al, 2005; Holland, 2008). There was 7% case of CMV retinitis patient in this study which was similar with the findings of the studies done in Tanzania (Sahoo, 2010) and Nigeria (Azonobi et al, 2013) where CMV retinitis was responsible for 4.8% and 7.2% respectively of ocular complications of HIV cases.

There were 10% cases of retinal detachment in this study. Retinal detachment in HIV is not uncommon and can occur in CMV retinitis, acute retinal necrosis (ARN) and progressive outer retinal necrosis (PORN) patients. Prognosis of RD is very poor and difficult to manage (Jain et al, 2013). There was a case of choroiditis as well. The cause for choroiditis was not isolated. However, choroiditis has been reported secondary to cryptococcal, tubercular, syphilitic, toxoplasma infections (Joseph et al, 2005; Govender et al, 2010).

In this study 43% patients were on ART for less than 3 month and among them 46% had ocular diseases. It is reported that immune recovery may not be achieved for three months or longer post ART and during that interval patients are still at risk for opportunistic infections, including CMV retinitis (Holland, 2008).

Neuro-ophthalmic related lesions were seen in 4% of total cases. In patients with AIDS there is a 3% to 8% incidence of neuro-ophthalmological disorders (Jabs et al, 1989; Mansour, 1990; Ziegler, 1991; Sadun, 1995).

One case of unilateral optic neuropathy had projection of light (PL) vision in one eye, CD4+ count was 11cells/mm<sup>3</sup> and the patient was on ART for 3 months duration. There were 2.5% cases of NHL. NHL accounts for 3.5 to 5% of AIDS defining illnesses (Matzkin et al, 1994).

Pulmonary tuberculosis was the most common systemic infection in 20% HIV patients. A study done from India had 67% case of pulmonary tuberculosis. (Biswas et al, 2000).

Ocular diseases were more common among the patients with lower CD4+ count. Patients in WHO Stage III and IV had more ocular diseases and among these patients 65% were on ART. Higher prevalence of ocular manifestations among the ART patients in WHO Stage III and IV has also been reported (Shah et al, 2009).

Only those patients who presented to Tribhuvan University Teaching Hospital were considered. Hence, this does not represent actual ocular changes among the other HIV positive patients. Most of the ART receiving patients were on ART only for shorter duration. This was a single centered cross sectional hospital based study; thus follow up study of these patients are required to look for any variation in clinical manifestations of HIV positive cases irrespective of antiretroviral therapy in long run.

### **Conclusion**

It can be concluded that anterior segment manifestations are more common in HIV patients. Young aged male and migrant workers are at more risk of acquiring HIV with heterosexual transmission being commoner. Eye changes are more common in WHO stage III and IV patients. However larger sample size and longer follow up study is required to have final disclosure.

### **Conflict of interests**

The authors declare that there is no conflict of interests

### **Acknowledgement**

The authors would like to thank department of medicine Tribhuvan University Teaching Hospital, antiretroviral therapy center teaching hospital, and all supporting staffs and colleagues.

## References

Ayena KD, Amedome KM, Agbo AR, Kpetessou-Ayivon AL, Dzidzinyo BK et al (2010). Ocular manifestations in HIV/AIDS patients undergoing highly active antiretroviral treatment (HAART) in Togo. *Med Trop*; 70(2): 137-40.

Azonobi R I, Udoye E, Tebepah T, Opubiri I R (2013). Ocular manifestation of HIV/AIDS infection among patients receiving highly active Anti retroviral therapy(HAART) in a tertiary eye care center. *J AHR*; 5(9): 322-327.

Biswas J, Madhavan HN, George AE, Kumarasamy N, Solomon S (2000). Ocular lesions associated with HIV infections in India: a series of 100 consecutive patients evaluated at a referral centre. *Am J Ophthalmol* ; 129: 9-15.

Biswas J, Sudharshan S (2008). Anterior segment manifestations of human immunodeficiency virus/ Acquired immune deficiency syndrome. *Ind J Ophthalmol*; 56: 363-75.

Freeman AH (1984). The retinal lesions of the acquired immune deficiency syndrome. *Trans Am Ophthalmol Soc*; 82:447-91.

Gharai S, Venkatesh P, Garg S, Sharma SK, Vohra R (2008). Ophthalmic manifestations of HIV infections in India in the era of HAART. *Ophthalmic Epidemiol*; 15(4): 264-271.

Goldberg DE, Smith LM, Angelilli A, Freeman WR (2005). HIV associated retinopathy in the HAART era. *Retina*; 25(5): 633-49.

Govender P, Hansraj R, Naidoo KS, Visser L (2010). Ocular manifestations of HIV/AIDS: A literature review. *S Afr Optom*; 69(4): 193-9.

Holland GN (1992). Acquired immunodeficiency syndrome and ophthalmology: the first decade. *Am J Ophthalmol*; 114: 86-95.

Holland GN (2008). AIDS and ophthalmology: the first quarter century. *Am J*

*Ophthalmol*; 145(3): 397-408.

Jabs DA (1995). "Ocular manifestations of HIV infection". *Trans Am Ophthalmol Soc*; 93: 623-83.

Jabs DA, Bartlett JG (1997). AIDS and ophthalmology: A period of transition. *Am J Ophthalmol*; 124(2): 141-57.

Jabs DA, Green WR, Fox R, Polk BF, Bartlett JG(1989). Ocular manifestations of acquired immune deficiency syndrome. *Ophthalmology*; 96: 1092-9.

Jabs DA, Van Natta ML, Kempen JH, Reed Pavan P, Lim JI, Murphy RL, et al (2002). Characteristics of patients with cytomegalovirus retinitis in the era of highly active antiretroviral therapy. *Am J Ophthalmol*; 133(1): 48-61

Jacobson MA, Stanley H, Holtzer C, Margolis TP, Cunningham ET(2000). Natural history and outcome of new AIDS-related cytomegalovirus retinitis diagnosed in the era of highly active antiretroviral therapy. *Clin Infect Dis*; 30(1): 231-33.

Jacobson MA, Zegans M, Pavan PR, O'Donnell JJ, Sattler F, Rao N et al (1997). Cytomegalovirus retinitis after initiation of highly active antiretroviral therapy. *Lancet*; 349(9063): 1443-45.

Jain C, Malik V. K. , Malik K.P.S. , Jain Kirti , Kumar Sanjeev , Kumar Sandeep (2013). Review Article: Ocular Manifestations of AIDS. *JARBS*; 5(4): 429-435.

Joint United Nations Programme on HIV/AIDS [internet] (2008). Geneva: Country Progress Report- Nepal; <http://www.unaids.org/nepal/>

Joint United Nations Programme on HIV/AIDS [internet] (2013). Geneva: AIDS epidemic update; <http://www.unaids.org/epidemiology/>

Joseph J, Vemuganti GK and Sharma S (2005). Microsporidia: Emerging ocular pathogens. *Ind J Med Micro*; 23: 80-91.





Lamichhane G, Shah DN, Sharma.S, Chaudhary.M (2010). Ocular manifestations in HIV/AIDS cases in Nepal. *Nep J Oph*; 2(3): 45-50.

Lin DY, Warren JF, Lazzeroni LC Wolitz RA, Mansour SE (2002). Cytomegalovirus retinitis after initiation of highly active antiretroviral therapy in HIV-infected patients:natural history and clinical predictors. *Retina*; 22(2): 268-77.

Mansour AM (1990). Neuro-ophthalmic findings in acquired immunodeficiency syndrome. *J ClinNeuroophthalmol*; 10: 167-74.

Matzkin DC, Slamovits TL, Rosenbaum PS (1994). Simultaneous intraocular and orbital non-Hodgkin lymphoma in the acquired immune deficiency syndrome. *Ophthalmology*; 101: 850-5.

National Centre for AIDS and STD control [internet] (2014). Nepal: HIV situation in Nepal; <http://www.ncasc.gov.np/>

Palella FJ Jr, Delaney KM, Moorman AC, Loveless MO, Fuhrer J, Satten GA et al (1998). Declining morbidity and mortality among patients with advanced human immunodeficiency virus infection. *N Engl J Med*; 338(13): 853-60.

Sahoo S (2010). HIV/AIDS-related ocular manifestations. *Malaysian J Med Sci*; 17(1): 12-16.

Sadun AA, Pepose JS, Madigan MC, Laycock KA, Tenhula WN (1995). AIDS-related optic neuropathy: a histological, virological and ultrastructural study. *Graefes Arch ClinExpOphthalmol*; 233:387-98.

Shah SU, Kerkar SP, Pazare AR (2009). Evaluation of ocular manifestations and blindness in HIV/AIDS patients on HAART in a tertiary care hospital in western India. *Br J Ophthalmol*; 93: 88-90.

Shukla DS, Rathinam SR, Cunningham ET (2007). Contribution of HIV/AIDS Global Blindness. *IntOphthalmolClin*; 42: 27-43.

Sirkul T, Prabriputaloong T, Smathivat A et al (2008). Predisposing factors and etiologic diagnosis of ulcerative keratitis. *ClinSci*; 27: 283-7.

Song MK, Karavellas MP, Macdonald JC, Plummer DJ, Freeman WR (2000). Characterization of reactivation of cytomegalovirus retinitis in patients healed after treatment with highly active antiretroviral therapy. *Retina*; 20(2): 151-55.

Sriprakash KS, Babu R, Kumar C, Rathod S, Shiva Kami A, Muralidharan RU (2004). Ocular manifestation of HIV/AIDS: an experience at a major eye hospital in South India. All India Ophthalmologic Society 62nd Conference, Varanasi, India. Jan 8-11.

Susan L, Paul C (1997). HIV and AIDS and the eye in developing countries. *Arch Ophthalmol*; 115: 1291-9.

Torriani FJ, Freeman WR, Macdonald JC et al (2000). CMV retinitis recurs after stopping treatment in virological and immunological failure of potent antiretroviral therapy. *AIDS*; 14(2): 173-80.

Weiss R (1993). "How does HIV cause AIDS?" *Science*; 260 (5112): 1273-9.

W. Wynn McMullen and Donald J. D'Amico (2000). AIDS and its ophthalmic manifestations. In Albert DM, Jakobiec FA, AzarDT, Gragoudas ES, Power SM, Robinson NL 2nd ed. principle and practice of ophthalmology. Philadelphia: WB Saunders Elsevier.

Ziegler JL (1991). Biologic' differences in acquired immune deficiency syndrome-associated non-Hodgkin's lymphomas? *JClinOncol*; 9:1329-31.

**Source of support: nil. Conflict of interest: none**