

Case report

Penetrating ocular fish hook injury: a case report

Chandana Chakraborti¹, Udayaditya Mukhopadhyaya², Dayal Bandhu Mazumder¹,
Partha Tripathi³, Swapan Kumar Samanta¹

¹Dept. of Ophthalmology, Calcutta National Medical College, Sundari Mohan Avenue,
Kolkata 700014, West Bengal, India

²Dept. of Ophthalmology, RIO, Kolkata, Kolkata 700001, West Bengal, India

³Chinsurah District Hospital, Hooghly, West Bengal

Abstract

Background: Fishing is a popular rural recreational activity. Fortunately, penetrating ocular injuries with fish hooks are rare. These injuries are usually caused by fish hook prongs penetrating the ocular tissues. We report a rare case of penetrating fish hook injury to the globe and its successful surgical management. **Case:** A 12- year-old female child was referred to the causality with a fish hook embedded in her right eye. She sustained the injury while fishing with her father. The fish hook had penetrated the globe obliquely. The hook was removed via its entrance wound under general anesthesia. Subsequently the child developed traumatic cataract which was operated with a final visual outcome of 6/12. **Conclusion:** Visual prognosis can be profoundly affected by the initial management. Prompt surgical intervention as done in our case is recommended to prevent significant visual loss.

Keywords: Fishhook, penetrating ocular injury, traumatic cataract

Introduction

Penetrating ocular fish hook injuries are rare. Potential visual loss may occur due to complications like corneal scarring, retinal detachment and endophthalmitis (Aiello LP et al, 1992). There are two main aspects of fish hook injuries. One is the mechanical aspect, caused by penetrating foreign bodies and the other is infection (Deramo VA et al, 1999; Fuentes-Mallozz DA, 2005). We would like to report this case because there is a limited number of penetrating ocular fish hook injuries reported in the literature.

Case report

A 12- year- old female child presented to the causality with a fish hook embedded in her right eye (RE) .While fishing with her father she sustained the injury. The father cut off the fishing line and tried to remove the hook but failed. The child was brought to the hospital 4 hours after the injury. On examination she had the best corrected visual acuity (BCVA) of hand movement with projection of light in all four quadrants in right eye. The fish hook had penetrated the globe obliquely , 2 mm away from limbus at 2'0 clock (Figure1). Slit lamp examination of the RE revealed , a shallow anterior chamber , mid dilated, , irregular , non reacting pupil and iris pigment dispersion on the anterior lens surface. Fundus examination showed poor fundal glow. The left eye was normal.

Received on: 29/5/14

Accepted on: 21/6/15

Address for correspondence

Dr Chandana Chakraborti ,
MBBS, MD (AIIMS)

Assistant Professor, Dept. of Ophthalmology
Calcutta National Medical College, Sundari Mohan Avenue,
Kolkata 700014
West Bengal, India
Email: cchakoptha@yahoo.com

Computed tomographic (CT) scanning was performed and suggested that the point of the hook had penetrated the ocular coats (Figure 2).

The patient was started on a regimen of intravenous cefazolin sodium 20 mg /kg /day in three divided doses and gentamycin sulfate 6 mg /kg /day in three divided doses. Under general anesthesia conjunctiva was dissected at the area of hook penetration. The shank of the hook was grasped outside the sclera with forceps and the barb of the fish hook was removed via its wound of entry. Prolapsing uveal tissue was abscised and the scleral wound was closed with 8-0 vicryl, conjunctiva was sutured with 8-0 silk suture and anterior chamber was reformed using balanced salt solution after the removal of the hook. Post operatively prednisolone 30 mg once daily orally was started and tapered over a period of 6 weeks. Systemic antibiotic was continued for one week. Topical steroid, antibiotics and cycloplegic mydriatics were given in appropriate doses. Post-operatively B scan ultrasonography was done to rule out any posterior segment pathology, but it was within normal limit. At 1 week follow up there was traumatic cataract (Figure 3). After 1 month of the injury when the eye became quiet, extracapsular cataract surgery with intraocular lens implantation was performed. At one month follow up her right eye vision was 6/12 unaided.

Discussion

Fishing is a popular leisure activity in many parts of the world. Ocular fishing injuries though uncommon may cause potentially devastating ocular trauma. Permanent vision damage may occur with removal of the fish hook although patient may present with minimal vision deficit.

Many different types and sizes of fishhooks are available. All hooks are made up of same basic parts .The basic parts of the fish hook are the eye, shank, bend, barb and point (Figure

4). When examining the hook, it is important to note if the fish hook is single, multiple or treble, whether the hook is barbed, and the number and locations of the barbs, these detail will help determine the best removal technique (Gammons M et al, 2001). Often persons will know the type of hook they were using and may be able to provide a sample for inspection.

While not routinely performed, X- rays may aid in determining the type of fish hook and depth of penetration in difficult cases. In our case position of the hook in CT scan was inconclusive, probably due to change of position of the point caused by attempt to remove the hook by the father which resulted in more tissue damage.

Removal of a fish hook penetrating the globe can be very challenging. Several fish hook expulsion techniques have been described in the literature (Srinivasan S et al, 2001).

1) The backout method or retrograde technique

It refers to backing the hook out through its entrance wound. Although technically simple, it is primarily useful for barbless hooks. If a barb is present and engaged in ocular tissues, this method can cause excessive ocular damage.

2) The snatch technique

This is a modification of the backout method, where downward pressure in the hook shank and rapid extraction are used to diminish pain during the removal procedure in non ocular tissues. This is a relatively traumatic technique and not advised for penetrating ocular injuries. Knox et al reported 4 cases of penetrating ocular injuries from fish hooks which were removed by back out method. In all cases final visual outcomes were 6/12 or better which suggest that a good visual outcome can be achieved with less published backout method of fish hook extraction.

3) *The advance and cut technique*

It is the most useful technique in the anterior segment fish hook injuries. The hook shank is grasped firmly, and a controlled surgical incision is placed to allow a traumatic delivery of the point and the barb. Sterile wire cutters are used to transect the hook at a location between the barb and the bend, after which the barbless hook is easily removed using the backout technique described previously. Advantages of this method are surgically controlled second wound, no enlargement of the primary wound and minimal traumatic manipulation. In our case, advancing the fish hook was not possible as it could have caused more damage to the inner structures.

4) *Needle –cover technique*

For hook penetration of the retina needle cover technique described by Grand and Lobes is preferred. A large bore needle is passed into the eye through the hook entry wound. The fish hook barb is then engaged within the lumen of the needle and both are withdrawn together.

5) *Cut- it out technique*

It consists of making a small incision with a scalpel blade at the entrance wound and then sliding the scalpel blade along the hook to the point of the fish hook. After this, the fish hook is simply backed out of the wound as per the simple back out method.

Aiello et al reported 5 cases of penetrating ocular fish hook injuries and showed promising visual outcome with appropriate surgical technique. Kamath et al, 2000 reported an unusual case of a 44-year- old male with a fishhook embedded in his left upper eyelid which was loaded with nine live maggots used as bait. Knox et al in 2004 reported four cases of penetrating ocular injuries from fish hooks. In all cases the hooks were extracted by back out technique and the final visual outcomes were 6/12 or better.

The technique of choice used for removal of the hook will vary depending on the case

and perhaps more important than the method of hook extraction is the need for prompt, appropriate surgical intervention.

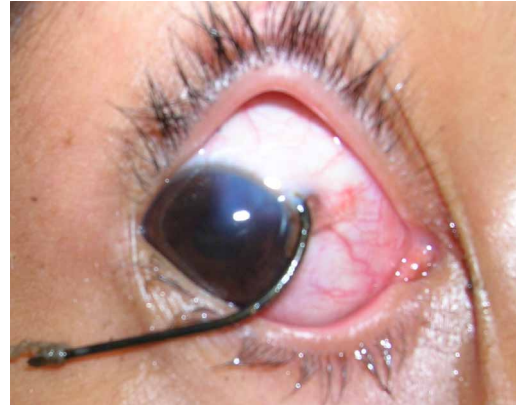

Figure 1: Fish hook penetrating right eye near limbus.(Reproduced from, Sure Success in Ophthalmology Viva-Voce and Practical Examination 2013,by Dutta J and Chakraborti C(New Delhi) Plate NO 15 .Copyright JP Brothers Medical Publishers(P) Ltd.

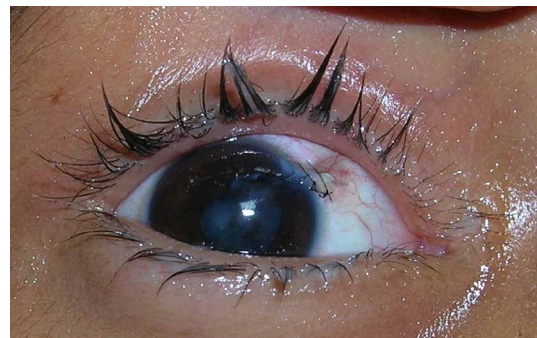

Figure 2: Coronal CT scan of right eye showing the fish hook.

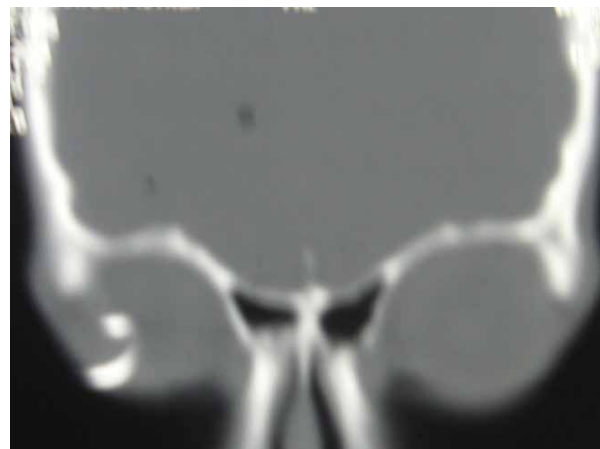


Figure 3: Traumatic cataract of the right eye



Figure 4: The fish hook which penetrated the globe

Conclusion

Removal of hook must be careful with a complete restoration of the eye structures. It is important to increase public awareness about the sight threatening complications of this popular sport and advise to wear protective eye gear.

References

Aiello LP, Iwamoto M, Guyer DR (1992). Penetrating ocular fish-hook injuries. Surgical management and long term visual outcome. *Ophthalmology*;99:862-866.

Deramo VA, Maus M, Cohen E, Jeffers J (1999). Removal of a fishhook in the eyelid and cornea using a vertical eyelid-splitting technique. *Arch Ophthalmol* ;117:541-542.

Fuentes-Mallozz DA, Mendez-Orozco CA (2005). Eyelid fish-hook injury: case report. *Boletín Médico del Hospital Infantil de México* ;62:449-453.

Gammons M, Jackson E (2001). Fishhook removal. *Am Fam Physicin.* ;63:2231-2236.

Kamath GG (2000). Fish hook injury of the eyelid: An unusual case. *Br J Ophthalmol* ;84:441-442.

Knox FA, Chan WC, Clara E, Johnston SE, Brayrs JH (2004). Penetrating Ocular Injuries from Fish hooks. *International Ophthalmology* ;25:291-294.

Srinivasan S, Macleod S (2001). Fish hook injury to the eyelid. *Indian J Ophthalmol* ;49:115-116.

Source of support: nil. Conflict of interest: none