

## Original article

# Outcomes of implantable collamer lens v4 and v4c for correction of high myopia – a case series

Smita Karandikar, Vipul Bhandari, Jagdeesh Reddy  
Sankara eye centre, shivanandapuram, coimbatore, Tamil Nadu, 640135

### Abstract

**Objective:** To evaluate the visual outcomes and intraocular pressure changes after Visian Implantable Collamer Lens (ICL) implantation V4b and V4c (with centraflow technology) for correction of myopia. **Materials and methods:** A prospective, consecutive, comparative interventional case series of V4b and V4c ICL implantation done for correction of high myopia ( $>-6$  diopter D) in patients unsuitable for laser vision correction. The outcome measures that were evaluated included preoperative and postoperative uncorrected distant visual acuity (UDVA), best spectacle corrected distant visual acuity (CDVA), endothelial cell count (ECC), presence of lens opacification, intraocular pressure (IOP) and ICL vaulting. A follow-up of upto 1 year was done. A questionnaire was given at the end of follow-up period. **Results :** A total of 30 eyes ( $24.56\pm 4.8$  years) underwent V4b ICL implantation (10 non-toric, 20 toric ICL-TICL) with intraoperative peripheral iridectomy (PI) and 34 eyes ( $26.13\pm 3.8$  years) had implantation of V4c ICL with centraflow (12 non-toric, 22 TICL). The mean preoperative manifest spherical equivalent (MSE) was  $8.98\pm 2.8$  D and  $9.24\pm 2.4$  D in the V4b and V4c groups respectively which reduced to postoperative values of  $-0.28\pm 1.3$  D and  $-0.19\pm 1.18$  D respectively. The mean preoperative astigmatism was  $-1.8\pm 1.2$  diopter cylinder (Dcyl) and  $-1.9\pm 1.6$  Dcyl which respectively reduced to  $-0.8\pm 0.8$  Dcyl and  $-0.9\pm 0.3$  Dcyl. At the end of 1 year follow up, mean ECC loss was 7.6% and 7.1%, mean vault was  $583.12\pm 231.12$   $\mu$  and  $602\pm 241.24$   $\mu$  respectively in the V4b and V4c groups. Anterior subcapsular opacities were present in 6.66% and 2.94% of eyes with V4b and V4c groups respectively. Two eyes from both V4b (10%) and V4c (8.33%) had rotation of more than 30 degrees and required re-rotation surgery done successfully. Two eyes (6.66%) with V4b ICL implantation had high postoperative IOP ( $>35$  mm Hg) and required Nd:Yag laser iridotomy later done with successful control of IOP. The safety indices were 1.12 and 1.15 and efficacy indices were 1.5 and 1.6 in the V4b and V4c groups respectively at the end of 1 year. The most common visual complaint was glare and haloes in 24% and 27% in the two groups respectively. However, they were not annoying enough to cause visual disability. **Conclusions:** Both V4b and V4c Visian ICL implantations are comparable in terms of visual outcome and safety profile for correction of high myopia. However, V4c ICL offers these advantages without the requirement of an additional PI.

**Keywords:** ICL, Centra flow

Received on: 07/01/15

Accepted on: 30/06/15

**Address for correspondence**

Dr Vipul Bhandari  
Sankara Eye Centre, Shivanandapuram, Coimbatore,  
Tamil Nadu, 640135  
Email: drvipulbhandari@gmail.com

## Introduction

Phakic intraocular lens (pIOL) provides internal compensation of the dysfunctional refractive condition of the phakic eye and reduces or eliminates the dependence on glasses or contact lenses. (Lovisol CF et al, 2005) An implantable lens consisting of a biocompatible collagen copolymer (Visian Implantable Collamer lens [ICL]; STAAR Surgical, Nidau, Switzerland) was developed in 1993 as a posterior chamber pIOL and was called the implantable contact lens, as initially it was thought that it would come into contact with the anterior surface of the crystalline lens. (Rosen E et al, 1998) Staar (Monrovia, CA, USA) patented this material made of 60% poly-hydroxyethylmethacrylate-HEMA, water (36%), benzophenone (3.8%) and 0.2% porcine collagen and called it the Collamer (collagen-copolymer). (Lovisol et al, 2005; Rosen et al, 1998). ICL is a posterior chamber phakic IOL which is soft, flexible gel-lens ushering an era of reversible refractive surgery. ICLs are ciliary sulcus placed posterior chamber pIOLs that can be implanted through a small (3.0 mm), self-sealing limbal/clear corneal incision. In contrast with refractive lens exchange, ICL implantation does not impair natural accommodation or increase the risk of retinal detachment above the background rate for untreated patients with high myopia and have a good safety profile. (Chun YS et al, 2004)

ICL is a boon in achieving spectacle independence in patients who are unsuitable for laser refractive procedures like those with high myopia ( $>-13$  diopter D), thin corneas, those with expected residual stromal bed thickness less than  $300\mu$  and severe dry eye. With its increasing acceptance and establishment of safety profile, ICL implantation has become an increasingly popular choice for the correction of moderate to high myopia. (Sanders DR et al, 2003; Kamiya K et al, 2009)

The convexo-concave design of the ICL creates a vault between it and the anterior lens

surface. However, the previous V4b ICM-ICL Model is known to cause pupillary block and so either a preoperative/intraoperative laser/surgical peripheral iridotomy/iridectomy (PI) is required. To overcome this additional step, the V4c ICM Model with a central hole (0.36mm)-KS aquaport (named after Kimiya Shimizu MD, Japan) was developed in 2011. It has a central hole in addition to two additional holes outside the optic facilitating aqueous outflow and removal of ophthalmic viscosurgical device (OVD) during surgery. It also helps maintain the lens nutrition. (Kawamorita T et al, 2012)

However, complications of ICL implantation such as cataract formation (anterior subcapsular lens opacities-typical butterfly cataract), endothelial cell loss, pigment dispersion, intraocular pressure (IOP) elevation and secondary glaucoma have been reported and these complications are expected to increase with time. (Sanders DR et al, 2003; Kamiya K et al, 2009) Studies have shown good acceptance profile of both the ICL models. (Sanders DR et al, 2003; Kamiya K et al, 2009; Higuera-Esteban A et al, 2013)

In view of the increasing prevalence of this surgical procedure, we conducted this study to evaluate the visual outcome, complication rate and safety indices of both the V4b and V4c ICM-ICL Models for the correction of moderate to high myopia in a tertiary eye care centre in South India.

## Material and methods

This is a prospective, consecutive, comparative, interventional case series. All patients undergoing ICL implantation for the correction of moderate to high myopia (manifest spherical equivalent  $-MSE \geq -4$  D) were included in the study. The following were the inclusion criteria- (a) age between 21-45 years (b) stable refraction within past 1 year (c) Patients not suitable for corneal based laser refractive procedures- those with abnormal corneal topography and keratoconus, predicted thin residual stromal



bed thickness of less than 300 $\mu$ , high refractive errors of >-13D, severe dry eye (d) corneal diameter >11 mm (e) internal anterior chamber depth-ACD (measured from endothelium) >2.9 mm. Bilateral implantation of the same ICL model for the correction of bilateral moderate-high myopia was preferred in an individual patient. The selection of the ICL model was done on the basis of computer randomization. A detail preoperative assessment was carried out including uncorrected distant visual acuity (UDVA), corrected distant visual acuity (CDVA), IOP measurement with noncontact tonometry-NCT (Tomey FT-1000) and a gonioscopy to ensure wide open angles. A detailed slit lamp examination to rule out any ocular pathology like old uveitis was done. A detailed fundus examination to rule out any myopia related or other fundus pathology was done and prophylactic laser if required was given. Automated and manual keratometry values were recorded using Topcon KR-8800 and ultrasound pachymetry using Tomey Pachymeter SP2000. Corneal topography was performed using Optikon 2000 Keratron Scout topographer and axial length and ACD by Sonomed PacScan 300. The White to White (WTW) diameter was measured using a digital biometric ruler-digital calipers. Endothelial cell count (ECC) was measured using Tomey EM-3000 specular microscope. The ICL power was calculated using the Staar Surgical Customer Service Department formula that uses the ACD, mean keratometry or simulated keratometry values, central corneal pachymetry, horizontal WTW distance and refraction 12 mm from the corneal vertex. The horizontal axis was marked with the patient sitting at the slit lamp prior to the surgery. Two dots were placed on the corneo-limbal area with a surgical marker indicating 0 and 180 meridians as reference for later toric ICL (TICL) alignment.

### ***Surgical technique***

Pupillary dilatation was achieved with a combination eyedrop containing 1%

tropicamide and 2.5% phenylephrine. 0.5% proparacaine was the topical anaesthetic used. With a temporal approach, two 1 mm paracenteses were made using angled keratome or 15 degree side port knife at 12 and 6 'o' clock positions. Hypromellose 2% (Viscomet PF, Unimed technologies) viscoelastic was injected into the anterior chamber taking care not to overfill the chamber. A temporal 3 mm clear corneal incision was made. The required ICL was loaded into the cartridge in the specified manner, ready for insertion. The paracenteses were used to position the footplates under the iris using the special manipulating instruments like Vukich's manipulator. It was ensured that all haptics were posterior to the iris. In case of V4b ICL, the pupil was constricted with 0.5% pilocarpine (Miochol 0.01% preservative free from appasamy ocular devices) and a single PI at 1 'o' clock position was done with vitrector under viscoelastic cover (figure 1 and 2). In case of V4c ICL (figure 3), this step was skipped. In case of TICL proper alignment was ensured. Viscoelastic was cleared from the AC.

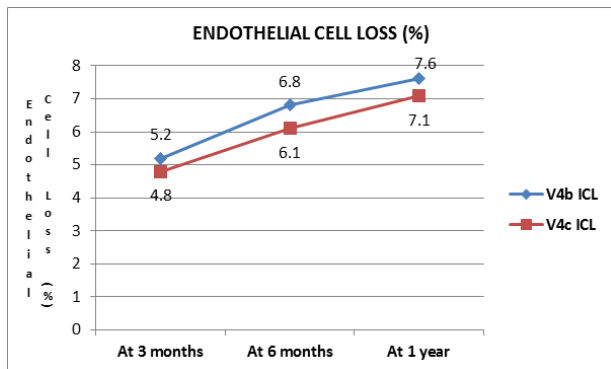
A standard postoperative regime consisting of topical prednisolone acetate (Allergan) 4 times a day for 5 days tapering over 2 weeks and topical gatifloxacin 0.3% (Allergan) 4 times a day for 2 weeks was started. 0.5% Timolol (sun pharmaceutical) was also started 2 times per day for 3 days. Postoperatively, patient was examined at 4 hours to check for proper ICL positioning and vaulting (figure 4) on slit lamp and IOP checked. The patient was then followed on postoperative day 1, 1 week, 1 month, 3 months, 6 months, 9 months and 1 year. The main surgical outcomes were evaluated at 1, 3, 6 and 12 months follow up. At each of these visits, UDVA, CDVA, MSE, IOP, ICL vaulting, ECC were evaluated. ICL vault was measured by anterior segment optical coherence tomography (AS-OCT) RTVue (Model-RT100 Version 6.9). A questionnaire was given at the end of follow-up period of 1 year.

**Table 1: Demographics**

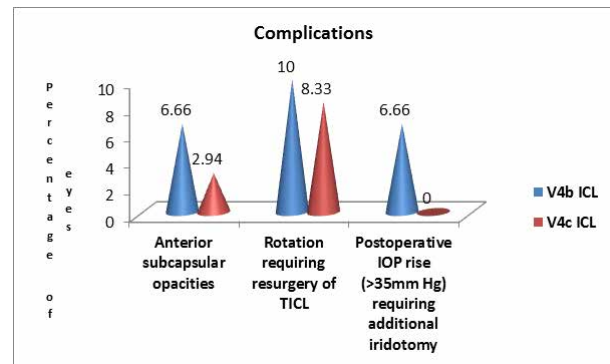
	V4b ICL group	V4c ICL group	P value
Age (years)*	24.56±4.8	26.13±3.8	0.72
Sex*	Males (n)	24	0.81
	Females (n)	9	
TICL (n)#	20	22	0.8
Preoperative MSE (D)#	-8.98±2.8	-9.24±2.4	0.51
Preoperative astigmatism (Dcyl)#	-1.8±1.2	-1.9±1.6	0.68
Postoperative MSE (D) at 1 year#	-0.28±1.3	-0.19±1.18	0.07
Postoperative astigmatism (Dcyl) at 1 year#	-0.8±0.8	-0.9±0.3	0.62

\*-X<sup>2</sup> Test. #-Mann Whitney U value Test  
 MSE-manifest spherical equivalent

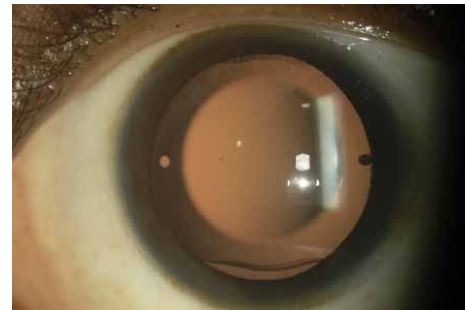
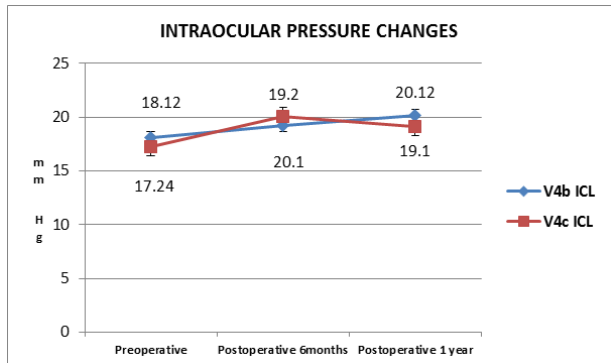
**Graph 1**



**Graph 4**

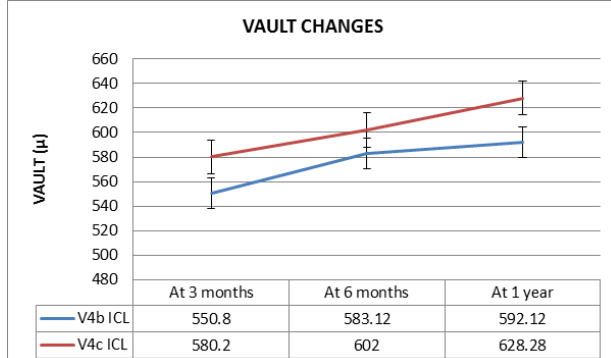


**Graph 2**

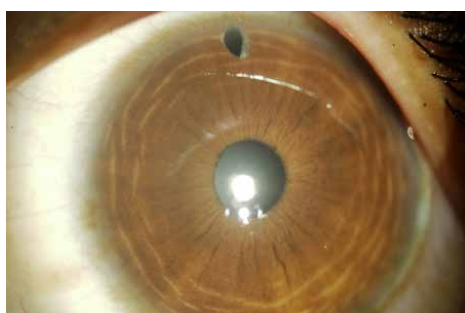

**Figure 1:** Showing slit lamp photograph of V4b ICL in situ

**Graph 3**



**Figure 2:** Showing slit lamp photograph of V4b ICL in situ with peripheral iridectomy done



**Figure 3:** Showing slit lamp photograph of V4c ICL with central hole in situ



**Figure 4:** Showing slit lamp photograph of ICL vault

### Results

A total of 30 eyes (mean age  $24.56 \pm 4.8$  years) underwent V4b ICL implantation (10 non-toric ICL, 20 TICL) with intraoperative PI and 34 eyes (mean age  $26.13 \pm 3.8$  years) had implantation of V4c ICL with centraflow (12 non-toric ICL, 22 TICL). The mean preoperative MSE was  $8.98 \pm 2.8$  D and  $9.24 \pm 2.4$  D in the V4b and V4c groups respectively which reduced to postoperative values of  $-0.28 \pm 1.3$  D and  $-0.19 \pm 1.18$  D respectively (Table 1). 97.38% and 98.12% of eyes had MSE within  $\pm 1.00$  D and 54.83% and 57.12% of eyes had MSE within  $\pm 0.50$  D of emmetropia in the two groups respectively. The mean preoperative astigmatism was  $-1.8 \pm 1.2$  diopter cylinder (Dcyl) and  $-1.9 \pm 1.6$  Dcyl in the V4b and V4c groups which respectively reduced to  $-0.8 \pm 0.8$  Dcyl and  $-0.9 \pm 0.3$  Dcyl. Gain of 1 line was seen in 10% and 11.76% eyes in V4b and V4c groups respectively while no change in CDVA was seen in 90% and 88.24% of eyes. No eye had loss of lines post surgery. The two groups were comparable.

The mean ECC loss was 6.8% and 6.1% in the V4b and V4c groups respectively at 6 months follow-up which increased to 7.6% and 7.1% at the end of 1 year (Graph 1). The mean preoperative IOP was  $18.12 \pm 1.4$  mm Hg and  $17.24 \pm 1.4$  mm Hg in groups V4b and V4c respectively which was maintained at a mean of  $20.12 \pm 1.2$  mm of Hg and  $19.1 \pm 1.3$  mm of Hg at the end of 1 year (Graph 2).

The mean vault was  $583.12 \pm 231.12 \mu$  and  $602 \pm 241.24 \mu$  respectively in the V4b and V4c groups at 6 months follow-up which was maintained at  $592.12 \pm 240.15 \mu$  and  $628.28 \pm 300.15 \mu$  at the end of 1 year (Graph 3).

Anterior subcapsular opacities were present in 6.66% and 2.94% of eyes with V4b and V4c groups respectively at the end of 1 year. None of the eyes had visually significant cataract. None of the eyes required ICL exchange due to improper vaulting. Two eyes from both V4b (10%) and V4c (8.33%) had rotation of more than 30 degrees and required re-rotation surgery done successfully. Two eyes (6.66%) with V4b ICL implantation had high postoperative IOP ( $>35$  mm Hg) and required additional Nd:Yag (Neodymium Yttrium Aluminium Garnet) laser iridotomy later done with successful control of IOP (Graph 4).

The safety indices were 1.12 and 1.15 and efficacy indices were 1.5 and 1.6 in the V4b and V4c groups respectively at the end of 1 year. The most common visual complaint was glare and haloes in 24% and 27% in the two groups respectively. However, they were not annoying enough to cause visual disability.

### Discussion

Phakic intraocular lens implantation is so far the only refractive treatment for high myopia that offers preservation of accommodation and potential reversibility.

In our study, we found no statistical significant difference in the UDVA, CDVA, MSE, ECC loss, IOP and vaulting between the two models of ICL V4b and V4c. Both the types of ICL with

or without the centraflo showed a satisfactory visual outcome which was maintained at the end of 1 year follow-up period.

(Huseynova T et al, 2014) also found similar results with the two models with both providing good visual outcome and no difference in the objective scatter index and higher order aberrations. (Ferrer-Blasco T et al, 2013) have also observed similar results.

ICLs have emerged as a successful and promising modality for the treatment of moderate to high myopia especially in candidates unsuitable for laser refractive procedures. (Sanders DR et al, 2004; Han SY, 2007). Though being an intraocular procedure, it provides the advantage of reversibility and an acceptable safety profile. With the advent of toric ICL, significant amount of astigmatism can be corrected. (Chang J et al, 2009) The TICL have shown to be stable over a long term period with the haptics enforcing stable lens position in the ciliary sulcus. (Mori T et al, 2012). The TICL is fundamentally different from toric intraocular lenses as it is not subject to contraction of the capsular bag. The soft footplates of the ICL conform to the undulations or the normal topography of the contours of the ciliary sulcus with a kind of lock-and-key situation where the footplates will drape over and into the tiny irregular features of the sulcus. This prevents excessive lens movement. In our study, we had 2 eyes from each of the groups requiring re-rotation surgery with successful outcomes. (Lee D et al, 2015) found an incidence of 1.7% of rotation in excess of 10 degrees with 98.3% showing excellent rotational stability without decrease in visual acuity.

There were no reports of excessive pigment dispersion or secondary glaucoma in our study. The IOP was maintained in both the groups over 1 year.

(Higuera-Esteban A et al, 2013) found no significant changes between the V4b and

V4c models with respect to IOP stability. (Kawamorita T et al, 2012) studied the fluid dynamics of aqueous humour in V4c model and suggested that Hole-ICLs improve the circulation of aqueous humour to the anterior surface of the crystalline lens. (Sanders et al, 2012) reported approximately 6% to 7% of eyes developing anterior subcapsular opacities at 7 year following ICL implantation but only 1% to 2% had progressed to clinically significant cataract in the same period, especially in high myopes and older patients. (Fernandes PR et al, 2011) also found cataract as the major complication. In our study, none of the eyes had visually significant cataract at the end of 1 year follow-up period.

In a study conducted by (Pothireddy R et al, 2012) in India, the safety index was 0.75 and the efficacy index was 1.04 twelve months postoperatively. ICL was thus evaluated to be a safe and effective procedure in terms of visual outcome. (Pineda-Fernandez A et al, 2004) reported MSE in 61.1% and 22% of eyes within  $\pm 1.00D$  and  $\pm 0.50 D$  of emmetropia.<sup>[18]</sup> In their study, the mean residual sphere was  $-0.25 D$  and mean residual cylinder was  $-0.12 D$  cyl. Insignificant refractive change during follow up after ICL implantation with similar results was obtained by (Igarashi A et al, 2014)

A study by (Dejaco-Ruhsurm I et al, 2002; Edelhauser HF et al, 2004) demonstrated rapid cell loss until 1 year postoperatively, after which the rate of loss was no longer statistically significant. In our study, the vitrector PI had clean cuts with minimum pigment dispersion and chance of being incomplete or getting blocked were non-existent. IOP was stable throughout the 12 months of follow up in both the groups and this could be attributed not just to the centraflo technology but also to the negligible pigment dispersion due to avoidance of PI. None of our cases developed secondary glaucoma following excessive vault or pigment dispersion during the follow up. In our study,

the ICL vault was maintained at 1 year follow-up period. (Kamiya K et al, 2009; Lee H et al, 2014)

(Kamiya K et al, 2015) in their study found the vault of the new central hole pIOL to be essentially equivalent to the vault of the conventional pIOL, suggesting that the presence of the central hole did not significantly affect the vault or the refractive accuracy.

(Kamiya K et al, 2012; Kamiya K et al 2013) found the V4c ICL with aquaport essentially equivalent in the optical quality variables to conventional ICL implantation, suggesting that the presence of the central artificial hole does not significantly affect the optical quality and the intraocular scattering after surgery. (Maroccos R et al, 2001) studied pIOLs and found that V4b ICL implantation leads to decreased night vision performance with glare and haloes. (Lyu IJ et al, 2011) found a common incidence of glare and haloes after ICL implantation. Many studies (Alfonso JF et al, 2013; Alfonso JF et al, 2011) have shown good visual performance and quality of life after ICL implantation. In our study, patients in both groups experienced glare and haloes but they were visually insignificant and non-annoying.

### Conclusion

ICL offers a safe, effective and reversible option for correction of high myopia. However, evaluation of the incidence of cataract formation and endothelial cell loss over a decade should be carried out.

ICL with a central hole offers an added advantage of annulling a PI and providing a stable IOP.

### References

Alfonso JF, Lisa C, Cueto LFV, Belda-Salmerón L, Madrid-Costa D & Montés-Micó R (2013) Clinical outcomes after implantation of a posterior chamber collagen copolymer phakic intraocular lens with a central hole

for myopic correction. *Journal of Cataract & Refractive Surgery*;39(6):915-921.

Alfonso JF, Baamonde B, Fernández-Vega L, Fernandes P, González-Méijome JM, et al (2011). Posterior chamber collagen copolymer phakic intraocular lenses to correct myopia: five-year follow-up. *J Cataract Refract Surg*;37: 873–880. doi: 10.1016/j.jcrs.2010.11.040

Chang J, Lau S (2009). Toric Implantable Collamer Lens for high myopic astigmatic Asian eyes. *Ophthalmology*;116:2340-2347.

Chun YS, Lee JH, Lee JM, et al (2004). Outcomes after implantable contact lens for moderate to high myopia. *J Korean Ophthalmol Soc*;45:480–489.

Dejaco-Ruhswurm I, Scholz U, Pieh S, Hanselmayer G, Lackner B, Italon C et al (2002). Long-term endothelial changes in phakic eyes with posterior chamber intraocular lenses. *J Cataract Refract Surg*;28:1589-93.

Edelhauser HF, Sanders DR, Azar R, Lamielle H (2004). ICL in Treatment of Myopia Study Group. Corneal endothelial assessment after ICL implantation. *J Cataract Refract Surg*;30:576–583.

Fernandes PR, González-Méijome JM, Madrid-Costa D, Ferrer-Blasco T, Jorge J & Montés-Micó R (2011). Implantable collamer posterior chamber intraocular lenses: a review of potential complications

Ferrer-Blasco T, García-Lázaro S, Belda-Salmerón L, Albarrán-Diego C & Montés-Micó R (2013). Intra-eye Visual Function Comparison With and Without a Central Hole Contact Lens-Based System: Potential Applications to ICL Design. *Journal of Refractive Surgery*;29(10):702.

Han SY, Lee KH (2007). Long term effect of ICL implantation to treat high myopia. *J Korean Ophthalmol Soc*;48:465–472.

Higuera-Esteban A, Ortiz-Gomariz A,

Gutiérrez-Ortega R, Villa-Collar C, Abad-Montes JP, Fernandes P & González-Méijome JM (2013). Intraocular pressure after implantation of the Visian implantable Collamer lens with CentraFLOW without iridotomy. *American journal of ophthalmology*;156(4):800-805.

Huseynova T, Ozaki S, Ishizuka T, Mita M & Tomita M (2014). Comparative study of 2 types of implantable collamer lenses, 1 with and 1 without a central artificial hole. *American journal of ophthalmology*;157(6):1136-1143.

Igarashi A, Shimizu K, Kamiya K (2014). Eight-Year Follow-Up of Posterior Chamber Phakic Intraocular Lens Implantation for Moderate to High Myopia. *Am J Ophthalmol*;157:532-9

Kamiya K, Shimizu K, Igarashi A, Hikita F, Komatsu M (2009). Four-Year Follow-up of Posterior Chamber Phakic Intraocular Lens Implantation for Moderate to High Myopia. *Arch Ophthalmol*;127:845-50.

Kamiya K, Shimizu K, Kawamorita T (2009). Changes in vaulting and the effect on refraction after posterior chamber phakic intraocular lens implantation. *J Cataract Refract Surg*;35:1582-1586. doi: 10.1016/j.jcrs.03.052

Kamiya K, Shimizu K, Ando W, Igarashi A, Iijima K & Koh A (2015). Comparison of vault after implantation of posterior chamber phakic intraocular lens with and without a central hole. *Journal of Cataract & Refractive Surgery*;41(1):67-72.

Kamiya K, Shimizu K, Saito A, Igarashi A & Kobashi H (2013). Comparison of optical quality and intraocular scattering after posterior chamber phakic intraocular lens with and without a central hole (Hole ICL and Conventional ICL) implantation using the double-pass instrument. *PloS one*;8(6):e66846.

Kamiya K, Shimizu K, Igarashi A, Kobashi H, Ishii R, et al (2012). Clinical evaluation of optical quality and intraocular scattering

after posterior chamber phakic intraocular lens implantation. *Invest Ophthalmol Vis Sci*;53:3161-3166. doi: 10.1167/iovs.12-9650

Kawamorita T, Uozato H, Shimizu K (2012). Fluid dynamics simulation of aqueous humour in a posterior-chamber phakic intraocular lens with a central perforation. *Graefes Arch Clin Exp Ophthalmol*;250:935-9.

Lee D, Lee SJ & Kyung H (2015). Rotational Stability after Toric Implantable Collamer Lens Implantation. *Journal of the Korean Ophthalmological Society.* ;56(4):477-484.

Lee H, Kang SY, Seo KY, Chung B, Choi JY & Kim KS (2014). Dynamic Vaulting Changes in V4c versus V4 Posterior Chamber Phakic Lenses Under Differing Lighting Conditions. *American journal of ophthalmology.* 2014;158(6):1199-1204.

Lovisolo CF, Reinstein DZ (2005). Phakic Intraocular Lenses. *Surv Ophthalmol.* ;50:549-87.

Lyu IJ, Kim C, Chung ES & Chung TY (2011). Risk Factors Associated with Glare and Halo after ICL Implantation. *Investigative Ophthalmology & Visual Science.* ;52(14):6204-6204.

Maroccos R, Vaz F, Marinho A, Guell J & Lohmann CP (2001). Glare and halos after "phakic IOL". *Surgery for the correction of high myopia. Der Ophthalmologe: Zeitschrift der Deutschen Ophthalmologischen Gesellschaft*;98(11):1055-1059.

Mori T, Yokoyama S, Kojima T, et al (2012). Factors affecting rotation of a posterior chamber collagen copolymer toric phakic intraocular lens. *J Cataract Refract Surg*;38:568-573.

Pineda-Fernandez A, Jaramillo J, Vargas J, Jaramillo M, Jaramillo J, Galindez A (2004). Phakic posterior chamber intraocular lens for high myopia *J Cataract Refract Surg* ;30:2277-83.





Pothireddy R, Reddy KP, Senthil S, Rao HL (2012). Posterior chamber toricphakic intraocular lenses for myopic astigmatism first experience in India. *J Cataract Refract Surg*;38:1583-9.

Rosen E, Gore C (1998). Staar Collamer posterior chamber phakic intraocular lens to correct myopia and hyperopia. *J Cataract Refract Surg*;24:596-06.

Sanders DR, Vukich JA, Doney K, Gaston M.(2003) Implantable Contact Lens in Treatment of Myopia Study Group. U.S. Food

and Drug Administration clinical trial of the Implantable Contact Lens for moderate to high myopia. *Ophthalmology*;110:255–266.

Sanders DR, Doney K, Poco M (2004). ICL in Treatment of Myopia Study Group. United States Food and Drug Administration clinical trial of the Implantable Collamer Lens (ICL) for moderate to high myopia: three-year follow-up. *Ophthalmology*;111:1683–1692.

Sanders DR (2008). Anterior subcapsular opacities and cataracts 5 years after surgery in the Visian Implantable Collamer Lens FDA trial. *J Refract Surg*;24:566–70.

**Source of support: nil. Conflict of interest: none**