

## Original article

# Ocular injuries in the people's uprising of April 2006 in Kathmandu, Nepal

Ananda K Sharma, Dev N Shah, Jeevan K Shrestha, Madhu Thapa, Gauri S Shrestha  
BP Koirala Lion's Centre for Ophthalmic Studies, IOM, Kathmandu, Nepal

## Abstract

**Introduction:** In April 2006, the people of Nepal organised mass demonstrations demanding the restoration of democracy in the country. The ocular injuries that resulted during the riots that ensued, their pattern and the visual outcome of the injured have not yet been reported. **Objective:** To study the demographic profile, type, severity and the visual outcome of ocular injuries that occurred during the 2006 people's uprising in Nepal. **Subjects and methods:** This was a retrospective interventional series of cases involving 29 subjects. The main outcome measures were demography, laterality of injury, type of injury and the visual status before and after the trauma. **Results:** The age of the victims ranged from 14 to 32 years. Among the victims with eye injuries, 27 (93.1 %) were males, who were unemployed youth, students and construction workers. The left eye was injured more frequently than the right. Non-lethal bullets and explosive tear gas were the commonest agents of the major ocular injuries. The main types of injuries requiring hospitalization were closed globe injuries in eight victims and open globe in six. Surgical intervention was required in 57.2 % (n = 29) of the cases. The visual outcome was poor in cases of open globe injury with posterior segment involvement. **Conclusion:** Non-lethal bullets and explosive tear gases can cause significant visual impairment. Severe open globe injury with a retained intra-ocular foreign body is associated with significant visual loss.

**Keywords:** rubber bullets, tear gas, ocular injury

## Introduction

The eyes represent only 0.1 % of the total body surface and 0.27 % of the anterior body surface. However, their significance to the individual and society is disproportionately higher (Nordber, 2000). The eye is the third most common organ affected by injuries after the extremities (Nordber, 2000). Uni-ocular blindness is most commonly due to ocular injury (Vernon et al, 1984). Ocular trauma represents half of the

patients attending the eye emergency service in a hospital (Chiapella and Rosenthal, 1985; Vernon, 1983).

Ocular injuries are associated with significant socioeconomic impact (Nordber, 2000; Johnston and Armstrong, 1986). Most importantly, the psychological impact of ocular trauma cannot be evaluated only in terms of financial measure.

In April 2006, Nepal witnessed a 19-day-long people's uprising in which all the opposing political forces and nearly all sections of the society participated. Twenty people lost their lives in these nineteen days and many others were seriously injured (Taman, 2011).

Received on 09.09.2013 Accepted on: 15.12.2013  
**Address for correspondence**  
Dr Ananda Kumar Sharma, MD  
Associate Professor and Head Department of Ophthalmology  
IOM, Maharajgunj, Kathmandu  
Tel: +977-9851078622  
Email: dr.anandasharma@gmail.com

A study of the ocular injuries in uprisings has not been conducted so far in the country. Hence, this study aims to describe the demography, type, pattern of ocular injuries and their treatment outcome during a period of mass socio-political upheaval.

### Materials and methods

This was a retrospective interventional series of cases with eye injuries in 29 subjects. A total of 543 cases of injuries were examined in the Emergency Department during those 19 days. The visual acuity was assessed in each subject with an internally illuminated standard Snellen's chart. A brief clinical history related to the ocular injury and time of injury was received from the patients. All the subjects then underwent a detailed eye examination under a slit-lamp bio-microscope (Haag-Striet 900).

The subjects injured with tear gas were immediately taken for eye irrigation with normal saline and a detailed examination was performed thereafter. Subjects with ocular surface foreign bodies had their eyes flushed with normal saline. The foreign bodies were then removed, after instillation of topical 4 % Xylocaine.

Patients who were unable to open their eyes due to severe lid and peri-orbital edema were examined under the operating microscope before surgery. An X-ray of the orbit and head, a CT scan and ocular ultrasonography were performed for all subjects with an ocular foreign body suspected. All cases with severe eye and adnexal injuries received systemic antibiotics. An informed consent was taken from all the subjects for the treatment and clinical photographic documentation for academic purposes.

### Results

A total of 543 cases with injuries reported to the Emergency Department in the 19 days. Among them, 15 (2.7 %) had adnexal injuries and 14 (2.6 %) ocular injuries. Males comprised of 27 (93.1 %). The traumatic agents were a wooden stick in nine (31.0 %), rubber bullet in eight (27.6 %), others (bumps against a wall, falls, etc.) in

four (13.8 %), tear gas in three (10.3 %), bricks and stones in three (10.3 %) and metallic bullets in two subjects (6.9 %).

### Adnexal and ocular surface (minor) injuries

Fifteen people, fourteen (93.3 %) male and one (6.7 %) female, sustained minor ocular injuries (Table 1). Periorbital injury with sub-conjunctival hemorrhage, lacerated injury over the left eye brow, sub-conjunctival hemorrhage, ecchymosis and mild traumatic iritis and bilateral conjunctival congestion were the injuries in this group of fifteen. The subjects' age ranged from 14 to 29 years. All the subjects were discharged from the emergency on the same day after treatment. At three months follow-up, all the subjects had improved.

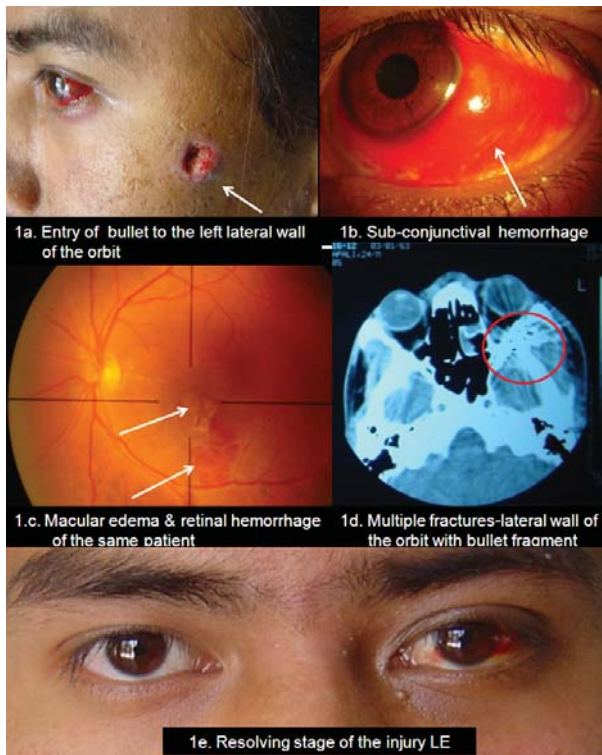
**Table 1: Description of the minor ocular injuries**

Description	No (%)
Male	14 (93.3)
Female	1 (6.7)
RE: Periorbital injury with SC h-ge	3 (20.0)
RE: Corneal abrasion with FB	2 (13.3)
LE: Lid laceration with SCh-ge	4 (26.7)
LE: Ecchymosis and mild traumatic iritis	3 (20.0)
BE: Conjunctival congestion + tearing	3 (20.0)
Students	5 (33.3)
Unemployed youth	6 (40.0)
Construction workers	4 (26.7)
≤15 years	1 (6.7)
>15 years	14 (93.3)
Stick (charged) injury	9 (60.0)
Brick/stones	2 (13.3)
Others: (hit against wall, fall during escape)	4 (26.7)
Total	15 (100)

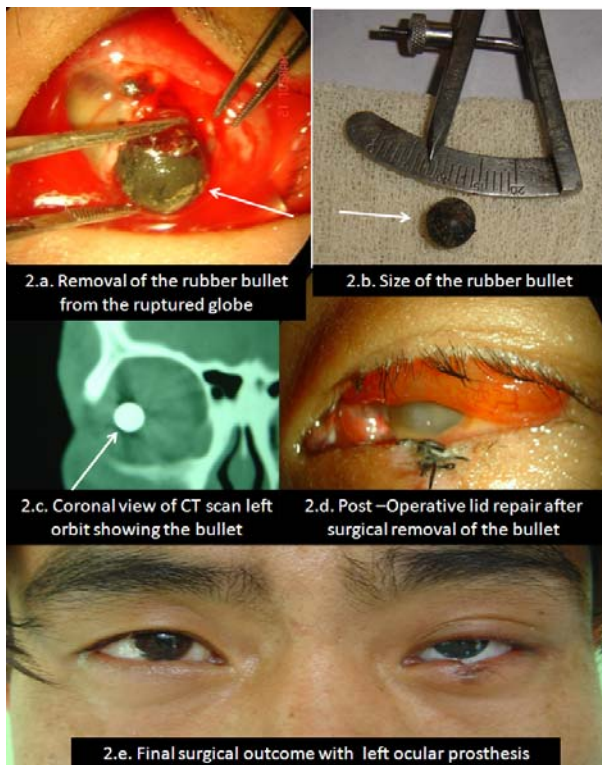
FB=foreign body, SC h-ge = sub-conjunctival hemorrhage

### Major ocular (open and closed globe) injuries

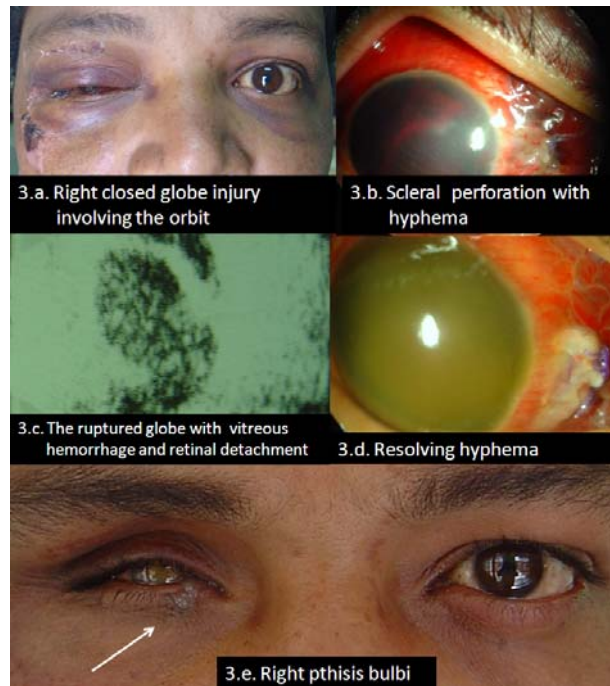
Fourteen subjects (Table 2) with a age range of 14 to 32 years sustained major ocular injury that comprised of open globe injury (Figures 2,3,7,8) in six subjects (42.9 %) and closed globe injury (Figures 1,5,6,9) in eight (57.1 %). The details of the major ocular injuries regarding the age, sex, and profession of the subjects and the traumatic agent, laterality of the injuries and the time of presentation are present in Table 2.



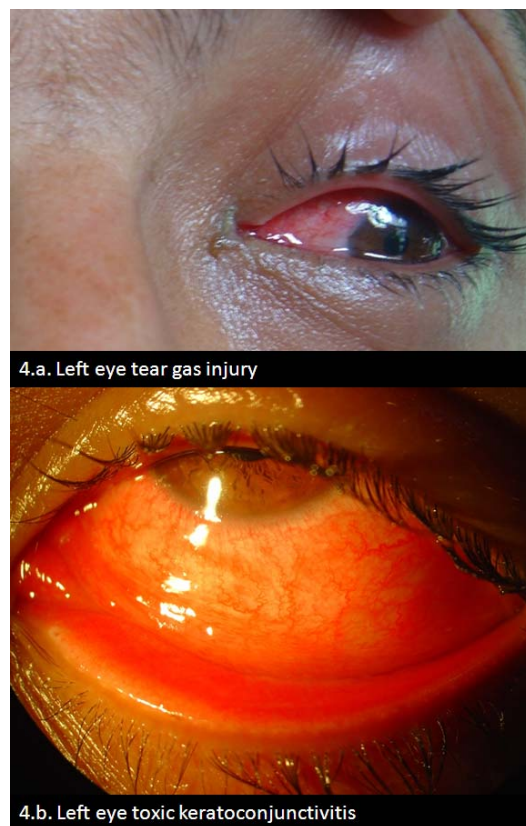
**Figure 1 a - e:** Closed globe injury with extra-orbital foreign body and multiple fractures of the orbit



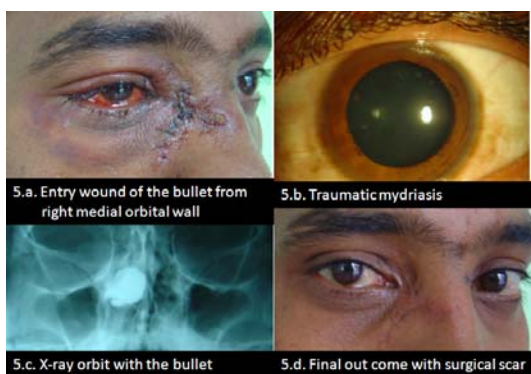**Figure 2 a - e:** Open globe injury with intra-ocular foreign body (rubber bullet) and lower lid injury



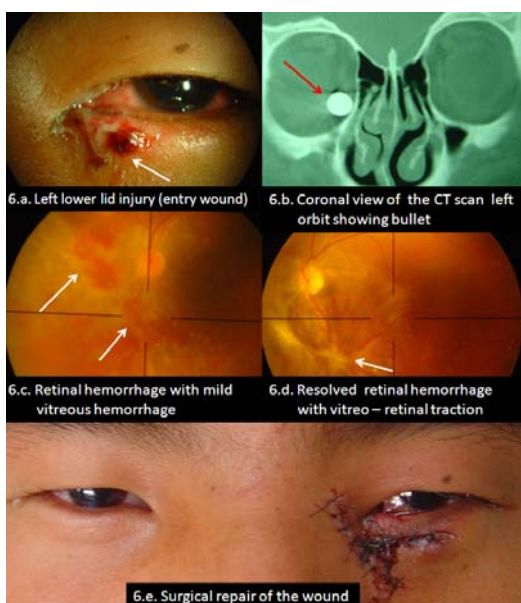
**Figure 3 a - e:** Open globe injury with total hyphema, vitreous hemorrhage and retinal detachment



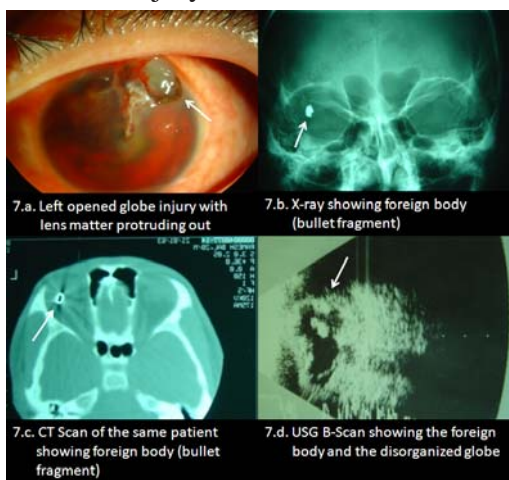
**Figure 4 a - b:** Tear gas injury (toxic keratoconjunctivitis)



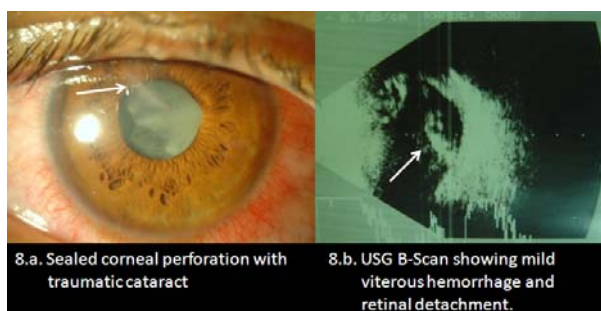
**Figure 5 a - d:** Closed globe injury with extra-orbital foreign body with traumatic mydriasis



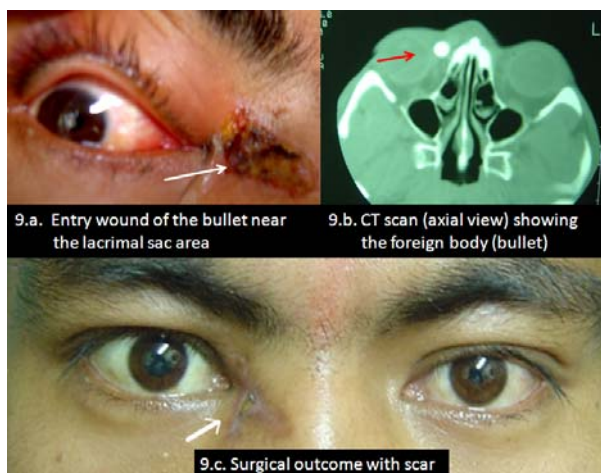
**Figure 6 a - e:** Closed globe injury with intra-orbital foreign body with posterior segment and lower lid injury



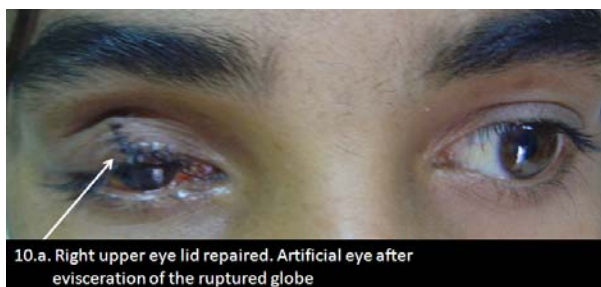**Figure 7 a - d:** Open globe injury with intra-ocular foreign body and ruptured globe and lens at the surface and AC exudates with total hyphema



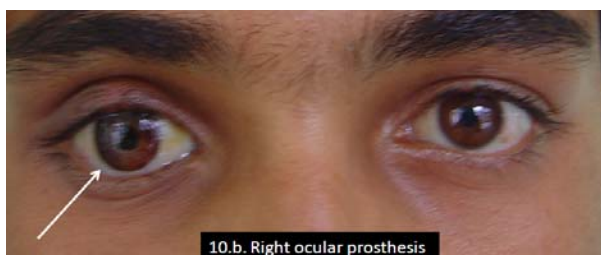**Figure 8 a - b:** Open globe injury with intra-ocular foreign body and traumatic cataract



**Figure 9a - c:** Closed globe injury with intra-orbital foreign body (rubber bullet entry at nasal canthal)



**Figure 10a:** Open globe injury with rubber bullet and upper eye lid injury repaired



**Figure 10 b:** Right ocular prosthesis

**Table 2: Description of the major ocular injuries**

Category		Type of injury		*OGI with intra-ocular FB		* CGI with intra-orbital FB	
		OGI N (%)	CGI N (%)	N (%)	N (%)		
Age	≤15 years	1 (16.7)	1 (12.5)	1 (100)	-		
	>15 years	5 (83.3)	7 (87.5)	4 (80.0)	4 (57.1)		
Sex	Male	6 (100)	7 (87.5)	5 (83.3)	4 (57.1)		
	Female	-	1 (12.5)	-	-		
Profession	Student	2 (33.3)	3 (37.5)	2 (100)	1 (33.3)		
	Construction Workers	2 (33.3)	3 (37.5)	2 (100)	2 (66.7)		
	Unemployed Youth	2 (33.4)	2 (25.0)	1 (50.0)	1 (50.0)		
Traumatic agent	Tear gas	-	3 (37.5)	-	-		
	Rubber bullet	4 (66.6)	4 (50.0)	4 (100)	3 (75.0)		
	Metal bullet	1 (16.7)	1 (12.5)	1	1		
	Brick/stone	1 (16.7)	-	-	-		
Laterality	Unilateral	6 (100)	6 (75.0)	5 (83.3)	4 (66.7)		
	Bilateral	-	2 (25.0)	-	-		
Time of presentation	≤24 hours	4 (66.6)	6 (75.0)	4 (100)	3 (50.0)		
	>24 hours	2 (33.4)	2 (25.0)	1 (50.0)	1 (50.0)		
<b>Total</b>		<b>6 (100)</b>	<b>8 (100)</b>	<b>5 (83.3)</b>	<b>4 (50.0)</b>		

\*OGI= Open Globe Injury; \*CGI=Close Globe Injury

\*Percentage derived as the ratio within the group having the same type of ocular injury

Ocular injury with retained foreign body was present in nine subjects (64.3 %), all of whom were males and had unilateral injury; and a bullet injury was responsible for the foreign body in all these nine cases. Open globe injury with retained intraocular foreign body was found in five (83.3 %) out of six subjects. Likewise, closed globe injury with retained intra-orbital/extra-orbital foreign body was present in four subjects (50%) out of eight. A bullet injury was the cause of the retained foreign body in nine subjects.

Seven of the nine subjects with major ocular injury with a foreign body (71.4 %) presented to Emergency Department within 24 hours of sustaining the injury and two (28.6 %) presented after 24 hours (range 24 to 72 hours).

The associated ocular findings are presented in **Table 3**: The most affected sites were lid (Figures 2 d and 6 e) in 64.3 %, retina (Figures 1 c and 6 c) in 64.2 %, vitreous hemorrhage in 35.7 % and orbital wall fracture (Figure 1 d) in 28.6 %. In the lid, lacerations were present in four (28.6 %) and ecchymoses were present in four (28.6 %) (Figures 4 a, 5 a and 6a). Total hyphema (Figure 3 b) was present in four (28.6 %) subjects. Retinal as well as vitreous hemorrhage were each the associated findings and present in five (37.5 %) subjects. Toxic keratoconjunctivitis (Figure 4) was related to exposure to tear gas. Two subjects who were exposed to tear gas developed ocular irritation and dry eye symptoms on follow-up visits.

**Table 3. The associated ocular findings**

Structure and conditions	No (%)
Lid and periorbital injury	9 (64.3)
Laceration	4 (28.6)
Ecchymosis	4 (28.6)
Lid edema	1 (7.1)
Toxic keratoconjunctivitis	2 (14.3)
Traumatic hyphema	4 (28.6)
Iris sphincter tear	1 (7.1)
Lens injury	3 (21.4)
Cataract	2 (14.3)
Lens subluxation	1 (7.1)
Vitreous haemorrhage	5 (35.7)
Retinal Injury	9 (64.2)
Comotio retinae	3 (21.4)
Retinal hemorrhage	5 (35.7)
Retinal detachment	1 (7.1)
Orbital fracture	4 (28.6)

### Visual and surgical outcome

Table 4 gives the details of the presenting and final visual acuity and Table 5 the treatment provided and outcome. The presenting as well as final visual acuity was equal to or better than 6/12 in two subjects (14.3 %) sustaining tear gas injury that caused toxic keratoconjunctivitis and mild lid edema. They were irrigated and provided palliative treatment with lubricating and antibiotic eye drops.

**Table 4: The presenting and final visual acuity**

Visual Acuity	Presenting VA in OGI N (%)	Presenting VA in CGI N (%)	Final VA in OGI N (%)	Final VA in CGI N (%)
6/6-6/12	-	2 (25.0)	-	3 (37.5)
6/18-6/36	-	-	-	4 (50.0)
6/60-4/60	-	5 (62.5)	1 (16.7)	1 (12.5)
3/60-1/60	1 (16.7)	1 (12.5)	-	-
PL	4 (66.6)	-	-	-
NPL	1 (16.7)	-	5 (83.3)	-
Total	6 (100)	8 (100)	-	-

VA = visual acuity; OGI = Open globe injury; CGI = Close globe injury

Surgical exploration (Figures 2, 5, and 9) of the orbit for bullet removal was done in four subjects (28.6 %) sustaining closed globe injury. Three subjects had a presenting visual acuity of 6/60 and one subject had a presenting visual acuity of 3/60, as a result of vitreous haemorrhage and macular edema. The entry of the bullet was the nasal orbital wall (Figures 5 a, 6 a, and 9 a) in two subjects and the temporal wall (Figure 1 a) and floor each in one subject. These bullet victims sustained a diversity of ocular injuries like retinal hemorrhages, commotio-retinae, and vitreous hemorrhages.

**Table 5. Medical and surgical treatment**

Treatment	No (%)	Remark	No (%)
Lid repair	1 (7.1)	Ocular prosthesis	4 (28.6)
Lid repair + evisceration + bullet removal	2 (14.3)	Scar	5 (35.7)
Surgical exploration (bullet removal)	4 (28.6)	Normal	3 (21.4)
Evisceration + bullet removal	2 (14.3)	Lost follow-up	2 (14.3)
Cataract surgery	2 (14.3)	<b>Total</b>	<b>14 (100)</b>
Eye irrigation and ocular surface foreign body removal	2 (14.3)		
Medical treatment (topical steroid and antibiotic)	1 (7.1)		
<b>Total</b>	<b>14 (100)</b>		

A combined procedure of lid repair (Figures 2 d, 6 e and 10 a), evisceration of globe and bullet removal was performed in two subjects (14.3 %). They had presenting visual acuity of perception of light, and after treatment they became blind to no perception of light in the affected eye. Both the subjects had open globe injury with intra-ocular foreign body. The cosmetic appearance improved after ocular prosthesis implantation (Figure 10 b).

Evisceration and bullet removal was done in another two subjects (14.3 %). Cataract surgery was done on two subjects (14.3 %) following closed globe injury. Presenting visual acuity was 3/60 in one case and 6/60 in the other. The final visual outcome after cataract extraction was 6/60 in the former due to vitreous haemorrhage, whereas it was 6/9 in the latter. There was a case of unilateral open globe injury with significant ecchymosis, total hyphema, vitreous hemorrhage and retinal detachment. The presenting visual acuity was perception of light. The subject was managed with medical treatment. However, the affected eye developed into a phthisis bulbi (Figure 3 e).

### Discussion

The present study describes the demographic profile, type, severity, treatment and the visual outcome of ocular injuries that occurred during the 19-day-long 2006 people's uprising in Nepal. The pattern of ocular injuries depends upon the methods of protest and of quelling the uprising resorted to by the two parties of a political confrontation. The recent civil unrest in the Kashmir valley resulted in 60 cases of eye injuries (Khan et al, 2012). Similarly, Jaouni and O'shea (1997) reported 567 cases of ocular injuries during the Palestine Intifada over a six-year period leading to blindness in 38 % of the victims. Lavy and Asleh (2003) reported cases of ocular rubber bullet injuries in 42 consecutive cases that caused ruptured globe in 38 %, orbital

fractures in 33 %, retinal damage in 26 %, and retained rubber bullet in or around the orbit in 21 %. The Vietnam conflict of 1964 to 1973 resulted in ocular injuries in 9 % of all the injured (Hoeftle, 1968), the Persian Gulf War of 1990 and 1991 in 13 % (Heier et al, 1993) and Operations Iraqi and Enduring Freedom reported in 13 % (Charters, 2007). In their study, Blanch et al (2011) reported significant ocular injury in 0.64 %. This finding was higher than that of the report by Thach et al (2008).

During Operation Iraqi Freedom, females accounted for 2 % of the military wounded. In our study, males comprised of 93.1 %. Unilateral injury was found in 82.7 %. The commonest traumatic agents causing minor and major eye injuries were sticks during 'lathi' charges in 31.0 % and rubber bullets in 27.6 % respectively. The age of the victims ranged from 14 to 32 years.

An Indian study similar to the present study in the Kashmir Valley by Khan et al (2012) reported ocular injury in 95 % of the males, where the major causative agents were stones (48.3 %) and pellets (30 %).

In our study, there were 543 reported cases of trauma in our Emergency Department during the 2006 peoples' uprising. Among these, 29 subjects had eye injuries, of which 15 had sustained adnexal and ocular surface injuries and 14 had severe ocular injuries.

Though the pattern of ocular injury was quite similar in various studies (Weichel et al, 2008; Erdurman et al, 2011; & Blanch 2011), the types of injuries differed according to the type of weapon used. Injuries of the head and neck are more common when stones are used (James, 1975), while injuries to the limbs are seen more with firearms and bomb blasts (Kennedy and Johnston, 1993; Dalvie et al, 1993; Emile et al, 1998). In our study, the most common weapons used were sticks in 'lathi' charges in 31.0 %,



rubber bullets in 27.6 %, tear gas in 10.3 %, brick and stone in 10.3 % and metallic bullets in 6.9 %.

The impact of rubber bullets has been published in previous studies as well. Rubber bullet and tear gas are commonly used by police force to disperse the civilian crowd without causing severe damage. However, Millar et al (1975) reported a significant proportion of permanent disabilities and deformities (18.9 %) including ruptured globes and orbital fractures as a result of rubber bullets and tear gas use.

Naturally, not all the cases of the eye injuries sustained in the uprising reported to our hospital. However, we think that this report quite accurately reflects the nature and types of the ocular injuries seen in similar circumstances.

The limitation of our study was that the final outcome of the surgical interventions and long term effect of tear gas exposure were not evaluated in those who were lost for follow-up visits. We could also not evaluate the adverse effects and toxicity of the bullet that was not removed.

### **Conclusion**

The most common traumatic agent in the minor ocular injuries were sticks. Bullets and explosive tear gases caused significant visual impairment. Open globe injuries with retained intra-ocular foreign bodies and closed-globe injury with posterior segment involvement caused significant vision loss. Minor ocular injuries involving the adnexal and ocular surface did not cause visual impairment and cosmetic defects. And the unemployed youth and students are most vulnerable to eye injuries during political uprising.

### **Acknowledgement**

We acknowledge Professor PC Karmacharya and Professor S Shakya (Consultant Ophthalmologists), Professor PN Prasad, HOD, Emergency Department, Professor CL Bhusal,

ENT Consultant and Professor MN Marahatta, HOD, Department of Anaesthesiology and Critical Care for their contributions. Mr Suresh Sharma is also acknowledged for his contribution in clinical and fundus photography.

### **References**

Blanch RJ, Bindra MS, Jacks AS, Scott RAH (2011). Ophthalmic injuries in British Armed Forces in Iraq and Afghanistan. *Eye*;25:218–23.

Charters L (2007). Protective eye wear essential for modern soldier. *Ophthalmol Times*.

Chiapella AP, Rosenthal AR (1985). One year in an eye casualty clinic. *Br J Ophthalmol*;69: 865 – 70.

Dalvie SS, Pai PR, Shenoy SG, Bapat RD (1993). Analytical data of January 1993 communal riot victims. The KEM hospital experience. *J Postgrad Med*;39:5–9.

Emile H, Hashmonai D (1998). Victims of the Palestinian uprising (intifada): a retrospective review of 220 cases. *J of Emerg Med*;16:389–94.

Erdurman FC, Hurmeric V, Gokce G, Durukan AH, Sobaci G, Altinsoy HI (2011). Ocular injuries from improvised explosive devices. *Eye*;25:1491–8.

Heier JS, Enzenauer RW, Wintermeyer SF, Delaney M, LaPiana FP (1993). Ocular injuries and diseases at a combat support hospital in support of Operations Desert Shield and Desert Storm. *Arch Ophthalmol*;111:795– 8.

Hoefle FB (1968). Initial treatment of eye injuries: First Corps Area of Viet Nam, 1966. *Arch Ophthalmol*;79:33–5.

James WV (1975). Riot injuries to policemen. An analysis of 808 policemen injured in rioting between 1969 and 1972 in Northern Ireland. *Injury*;7:41–3.





Johnston PB, Armstrong MF (1986). Eye injuries in Northern Ireland two years after seat belt. *Br J Ophthalmol*;70:460-2.

Jaouni ZM, O'Shea JG (1997). Surgical management of ophthalmic trauma due to the Palestinian Intifada. *Eye (Lond)*;11:392-7.

Khan S, Maqbool A, Abdullah N, Keng MQ (2012). Pattern of ocular injuries in stone pelters in Kashmir valley. *Saudi Journal of Ophthalmology*;26:327-30.

Kennedy TL, Johnston GW (1975). Civilian bomb injuries. *Br Med J*;1:382-3.

Lavy T, Asleh SA (2003). Ocular rubber bullet injuries. *Eye*;17:821-4.

Millar R, Rutherford WH, Johnston S, Malhotra VJ (1975). Injuries caused by rubber bullets: a report on 90 patients. *Br J Surg*;62:480-6.

Nordber E (2000). Ocular injuries as a public health problem in sub-saharan Africa: Epidemiology and prospect for control. *East Afr Med J*;77:1 - 43.

Tamang LR (2011). Nepal and Egypt: some striking parallels. [Available at [http://www.idea.int/asia\\_pacific/nepal/nepal\\_egypt\\_parallels.cfm](http://www.idea.int/asia_pacific/nepal/nepal_egypt_parallels.cfm)] retrieved on 09 March , 2014

Thach AB, Johnson AJ, Carroll RB, et al (2008). Severe eye injuries in the war in Iraq, 2003-2005. *Ophthalmology*;115:377-82.

Vernon SA (1983). Analysis of all new cases seen in a busy regional centre ophthalmic casualty department during a 24hour period. *J R Soc Med*;76:279-82.

Vernon SA, Yorston DB (1984). Incidence of Ocular Injuries from road accidents after introduction of seat belt legislation. *J R Soc Med*;77:198 - 200.

Weichel ED, Colyer MH, Ludlow SE, Bower KS, Eiseman AS (2008). Combat Ocular Trauma Visual Outcomes during Operations Iraqi and Enduring Freedom. *Ophthalmology*; 115:2235-45.

**Source of support: nil. Conflict of interest: none**