

Successful Laparoscopic Retrieval of an Accidental Intra - Abdominal Sewing Needle – A Case Report

Sunil Basukala¹, Narayan Thapa¹, Sushil Rana Magar², Bikash Rayamajhi¹, Dhirendra Ayer¹, Alok Raj Gautam³ and Ravi Bhandari²

¹Department of Surgery, Nepalese Army Institute of Health Sciences, Shree Birendra Hospital, Chhauni, Kathmandu, Nepal

²Department of Orthopaedics, Nepalese Army Institute of Health Sciences, Shree Birendra Hospital, Chhauni, Kathmandu, Nepal

³Department of Anaesthesiology and Critical Care Medicine, Nepalese Army Institute of Health Sciences, Shree Birendra Hospital, Chhauni, Kathmandu, Nepal

ABSTRACT

Accidental ingestion of sewing needle is a common presentation in daily emergency medical practice but its insertion through the abdominal wall is quite rare. We present a case of 26 years old serving soldier who had an accidental intraabdominal insertion of sewing needle which was managed laparoscopically. Initially patient was asymptomatic, however he complained of lower abdominal pain later. This was followed by successful laparoscopic retrieval of sewing needle located in right iliac fossa with no documented complications during six months of follow-up of the patient.

Key Words: Accidental; sewing needle; laparoscopic; abdomen

Correspondence: Sunil Basukala, Department of Surgery, Nepalese Army Institute of Health Sciences, Shree Birendra Hospital, Chhauni, Kathmandu, Nepal. E-mail: anyurysm@gmail.com

DOI: 10.3126/mjsbh.v21i1.40349

Submitted on: 2021-10-13

Accepted on: 2022-03-25



This work is licensed under creative common license:

<http://creativecommons.org/licenses/by-nc-nd/4.0/> © MJSBH 2020



INTRODUCTION

Foreign body ingestion is commonly seen among paediatric population, and the vast majority of foreign bodies pass through the gastrointestinal tract uneventfully.^{1,2} However, very limited studies are present on the prevalence of accidental insertion of foreign bodies (FB) among adult populations.¹ Symptoms of an abdominal foreign body vary with the nature, type and location of the object. Perforation of either bowel or major vessel is mainly caused by thin, pointed objects, such as needles and magnetic foreign bodies.⁴ Radiologic localization of the foreign bodies is mandatory when surgical intervention is considered.⁵ In this study, we report a unique case of a 26-year-old serving soldier with an accidental intraabdominal insertion of sewing needle a month prior to hospital presentation which was managed laparoscopically.

CASE REPORT

A 26 years old serving soldier was referred to us from the Department of Orthopedics with a history of an accidental intraabdominal sewing needle insertion. During history taking, he could not exactly recall how the needle got there, but he gave history of accidental needle prick sensation on his right lower abdomen one month back while lying on the bed. We presumed that the needle migrated slowly to the present location intrabdominally. Even though patient was asymptomatic initially, he later complained of right lower abdominal pain which was sharp “needle prick” type in character, episodic and was aggravated by certain movements or postures like bending forward. His bowel and bladder habits were normal. On abdominal examination, there was tenderness in right lower quadrant. There was no guarding, rigidity or rebound tenderness. His laboratory parameters were within normal limits. Ultrasonography of abdomen and pelvis revealed a 3.5 cm long needle-like, hyperechoic metallic object in right lower abdomen suggestive of foreign body. This was followed by plain abdominal X-ray which showed around 4 centimetres needle like, radio opaque shadow in lower abdomen slightly left to the midline. Abdominal computed tomography (CT) scan suggested the presence of intraabdominal metallic foreign body close to caecum which was of similar morphology as seen in ultrasound and X-Ray Figure 1.

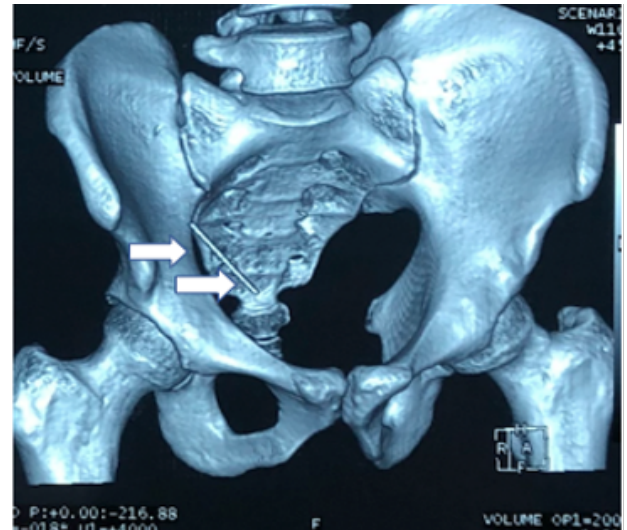

Figure 1. 3D CT showing foreign body in the right lower pelvis (Pointed in white arrows)

Patient underwent laparoscopic exploration of foreign body after counselling. Intraoperative localization of the needle was done by C-arm fluoroscopy fig. 2. The area was marked by metal clips and another abdominal film was taken for exact orientation.

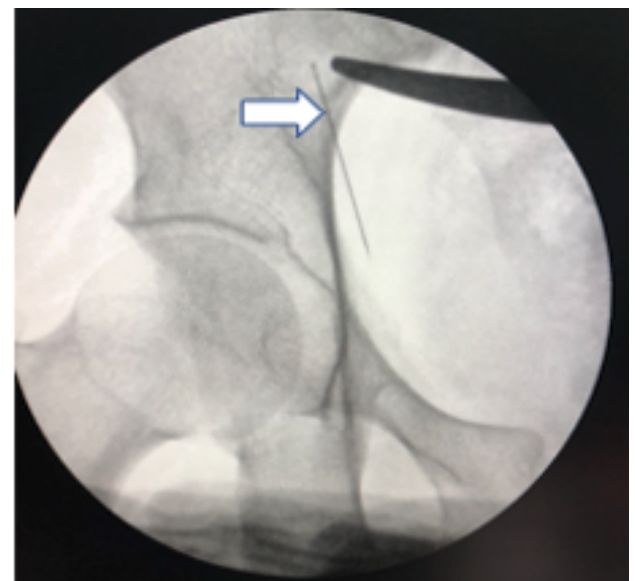


Figure 2. Foreign body in the right lower pelvis seen in C-arm (pointed in white arrows)

Intraoperatively, laparoscope visualized the needle along the mesocolon in right iliac fossa just lateral to caecum. It was exposed after meticulous dissection and retrieved by laparoscopic grasper Figure 3. There was no evidence of abscess or organ perforation. Patient was discharged on second post-operative day and followed up weekly for a month.

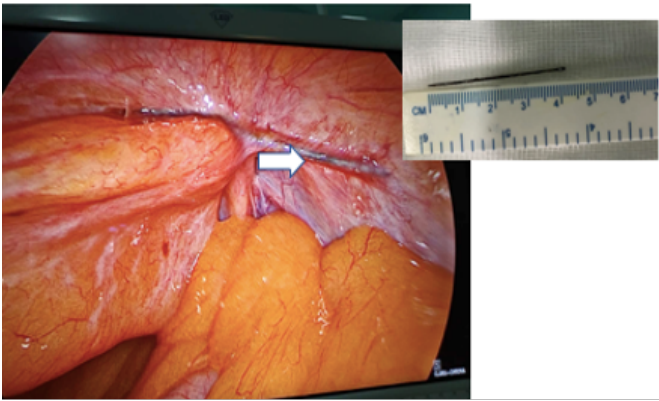


Figure 2. Needle (4cm) in the right lower pelvis embedded in mesocolon (pointed in white arrow)

DISCUSSION

Accidental or unintentional insertion of sharp metallic foreign bodies is an uncommon clinical occurrence. Abdominal foreign bodies usually come to clinical attention only if they cause a complication. The true incidence of asymptomatic abdominal foreign bodies is therefore unknown and may be higher than estimated.^{6,7} Predisposing factors for such incident include excessive alcohol intake, mental impairment and psychiatric illnesses in most of the cases. Four routes of entry of a FB into the peritoneal cavity has been described as percutaneous, penetration after swallowing, either by accident or intentionally, iatrogenic after surgery or examination, and via natural orifice.⁸ Gastrointestinal symptoms ranges from pain, vomiting as well as respiratory symptoms such as coughing and stridor are associated with FB ingestion. FB in the stomach and intestine are often spontaneously passed more frequently than at any other sites in the gastrointestinal system. Esophageal and gastric foreign bodies are often amenable to endoscopic removal whereas small bowel foreign bodies more often require surgical intervention in case they fail to pass spontaneously.⁸ It is difficult to obtain the history of insertion of foreign body among the patients.³ Intra-abdominal foreign body can lead to either to insidious unrelated presentation or more catastrophic events including perforation or obstruction of the bowel, migration to almost any intraabdominal or rarely to even extra abdominal sites. Migration to the distant organs such as liver, mesentery or the anterior abdominal wall is extremely rare.⁸ For the surgeons attempting to manage the needle migration, potential issue includes those inherent difficulties in seeking a small sharp object and morbidity due to puncture or laceration of vessels, pancreas and spleen and / or intrahepatic tissue.^{9,10}

Variable time periods ranging from months to years have been reported between the introduction of a foreign body and the occurrence of symptoms.⁵ It is extremely important to accurately detect radiopaque foreign bodies. Meticulous preoperative monitoring ingested needles is must and should done by serial abdominal X rays.¹ Based on serial X ray findings, management modality of the suspected foreign body can be managed by endoscopic, laparoscopic or open exploratory laparotomy. CT scan of abdomen is a modality of choice to localize the foreign bodies preoperatively, both radiopaque and radiolucent. Intraoperatively, C-arm fluoroscopy is a feasible, cost-effective modality with real-time images, which could accurately detect multiple radiopaque objects disseminated throughout the digestive tract.⁴⁻⁶

It has been recommended that sharp-pointed objects like needles should be removed even if the patient is asymptomatic, as the risk of hollow viscus perforation and peritonitis, intra-abdominal abscess, intestinal obstruction, fistulae formation, erosion of vessel wall and hemorrhage always remains.^{7,8} Surgery, though rarely required, is an alternative when endoscopic extraction fails in case of esophageal and gastric FB that fail to pass spontaneously or cause complications. There have been reports of laparotomy being done for such FB and some cases even requiring laparotomy.³⁻⁵ Considering the penetrating and migratory nature of foreign bodies, laparoscopic approach may reduce the unnecessary exploration of digestive tract, subsequently preventing possible complications. Herein, we suggest that exploration of intra-abdominal foreign bodies should be performed by an experienced team, which is able to deal with potential vascular, solid organ and hollow viscus complications. In our case, patient had abdominal pain and the sharp metallic object was in very close proximity to large bowel after its migration through anterior abdominal wall. We therefore decided to explore as the risk of leaving the foreign body in place outweighed the risk of removing it.

CONCLUSIONS

Sharp metallic intra-abdominal foreign bodies can remain asymptomatic but there always remain risks of complications and thus should be explored. Laparoscopic exploration is far better than open when possible as it is minimally invasive and augments post-operative recovery.

To cite this article: Basukala S, Thapa N, Magar SR, Rayamajhi BB, Ayer D, Gautam AR, et al. Successful Laparoscopic Retrieval of an Accidental Intra -Abdominal Sewing Needle - A Case Report. *MJSBH*. 2022;21(1):150-3.

Conflict of Interest: None declared

REFERENCES

1. Ahn SH, Mayo Smith WW, Murphy BL, Reinert SE, Cronan JJ. Acute nontraumatic abdominal pain in adult patients: abdominal radiography compared with CT evaluation. *Radiol*. 225(1):159-64. DOI: 10.1148/radiol.2251011282
2. Nasri B, Yuu K, Tada M. A case report of successful removal of multiples sewing needles in the gastrointestinal tract and pancreas using intraoperative C-arm fluoroscopy. *Int J Surg Case Rep*. 2016;24:166–71. DOI: 10.1016/j.ijscr.2016.05.043
3. Bulbuloglu E, Yuksel M, Kantarceken B, Kale IT. Laparoscopic removal of a swallowed sewing needle that migrated into the greater omentum without clinical evidence. *J Laparoendosc Adv Surg Tech A*. 2005 Feb 1;15(1):66-9. DOI: 10.1089/lap.2005.15.66
4. Harjai MM, Gill M, Singh Y, Sharma A. Intra-abdominal needles: an enigma (a report of two cases). *Int Surg*. 2000 Apr 1;85(2):130-2. DOI: 10.18203/2349-2902.isj20213605
5. Ma CJ, Jan CM, Hsieh JS, Huang YS, Wang WM, Chan HM, et al. Successful localization and surgical removal of ingested sewing needle under mini C arm fluoroscopy: A case report. *Kaohsiung J Med Sci*. 2006;22:457-60. DOI: 10.1016/s1607-551x(09)70338-9
6. Gonzalez-Ojeda A, Rodriguez-Alcantar DA, Arenas-Marquez H, Chavez-Perez R, Alvarez-Quintero R, Perea-Sanchez A. Retained foreign bodies following intra-abdominal surgery. *Hepato-gastroenterology*. 1999 Mar 1;46(26):808-12. DOI: 10.1080/089419301753435684
7. Lauwers PR, Van Hee RH. Intraperitoneal gossypibomas: the need to count sponges. *World j surg*. 2000 May;24(5):521-7. DOI:10.1007/s002689910084
8. Fujiwara T, Mitsunori Y, Kuramochi J. Laparoscopic removal of a foreign body (a piece of wire) from the abdominal cavity: A case report and review of thirty two cases in Japan. *J Jpn Endosc Surg*. 2007;12:415–9. DOI: 10.5180/jsgoe.23.169
9. Dominguez S, Wildhaber BE, Spadola L, Mehrak AD, Chardot C. Laparoscopic extraction of an intrahepatic foreign body after transduodenal migration in a child. *Journal of pediatric surgery*. 2009 Nov 1;44(11):e17-20. DOI: 10.1016/j.jpedsurg.2009.10.052
10. Uriupin AV, Brezhnev VP. Perforation of the small intestine by a foreign body in incarcerated hernia of the spigelian line. *Khirurgiia(Mosk)* 1991;128. DOI: 10.1007/s10029-004-0221-x