

# Broncho - Hepatic- Fistula: A Complication of Rupture Liver Abscess

Rajbhandary GL<sup>1</sup>

<sup>1</sup>Gambhir Lal Rajbhandary, Senior Consultant Cardio Thoracic Surgeon, Shree Birendra Hospital

## Introduction

Abscesses of liver are relatively more common in Tropical countries in comparison to temperate climatic countries. Liver Abscess may be Pyogenic or Amoebic in origin.

If not checked early and treated in time, Liver Abscess may expand and Liver Abscess may rupture in any direction. Peritoneal rupture results in wide spread peritonitis or in the formation of Sub-Phrenic Abscess.

Extension through the diaphragm lead to Thoracic Empyema or rupture into the bronchus with the expectoration of large volume of Anchovy-paste coloured pus from amoebic liver abscess and bile stained pus from cholangitic abscess pyogenic.

Rupture of a Liver Abscess into the lung and bronchus with persistent bronchus Broncho-Hepatic Fistula may require formal thoracotomy, decorticotomy of the lung for Empyema and diaphragm resection of severely damaged pulmonary tissue and repair of diaphragm.

## Case Report

A 24 years old serving soldier had fever and chest pain for the problem he went to Seti Zonal Hospital for the primary medical treatment. After antibiotic and analgesic treatment as his problem did not subside he was referred to Birendra Army Hospital 15/3/2063 (29th June 2006).

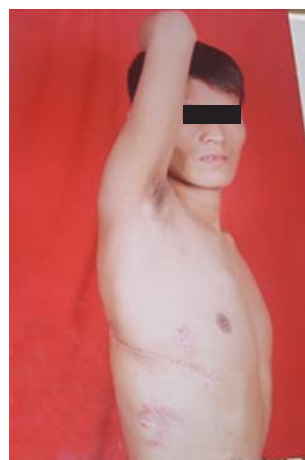At Birendra Hospital he was admitted in Medical ward. On his chest x-ray detected Rt. side pleural effusion. He had diagnostic Rt. pleural tap with thick

.....  
Address for correspondence: gambhirrb@hotmail.com



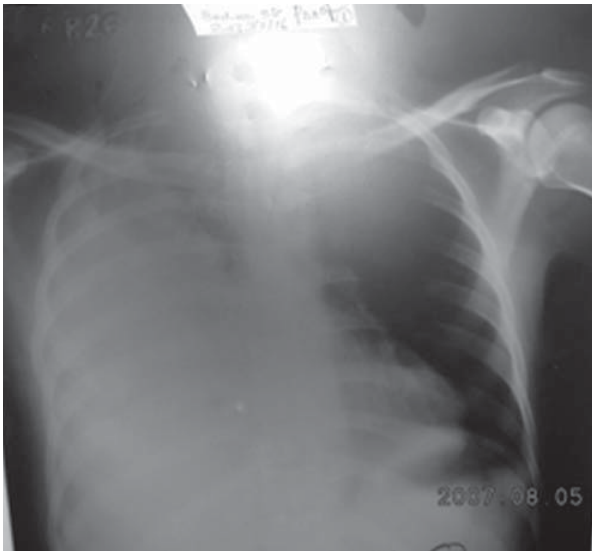
**Fig.1:** Shree Birendra Hospital

pus drained from Rt. pleural cavity. He was treated with injection antibiotics Taxim 1 gm TDS.

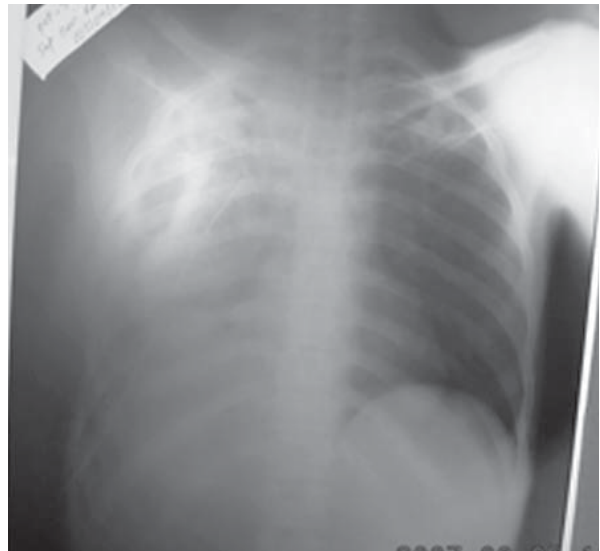


**Fig. 2:** Patient after surgery

He still continued to run high temperature with chest pain and clinically detected Hepatomegaly. On ultra sound abdomen large abscesses multiple were detected in Liver. Ultra sound guided Liver abscesses was aspirated pus from liver was found positive for



**Fig. 3:** Pre operative X-ray, Chest:



**Fig. 4:** Post operative X-ray, Chest:

E.Coli and pus from liver aspirate and pleural aspirate was negative for trophozoites of E.Histolytica.

Even with high dose of Inj. Antibiotics Taxim and Inj. Metronidazole. His condition continued to deteriorate.

On 05.04.2063 he started to cough with expectoration of purulent sputum mixed with bile.

Sputum was positive for Bile. Patient was suspected to have developed rupture of liver abscess with developments Rt. Emphyma thoracic, Lung abscess and formation of Rt. Broncho-Hepatic Fistula.

Patient was referred to cardio-thoracic surgery on 05.04.2063 he had Emergency Rt. Thoracostomy Chest Tube Drainage. Rt. chest tube was draining thick pyogenic fluid and air. The pleural fluid was positive for bile.

- In the pleural drain Air and bile leak was persistent.

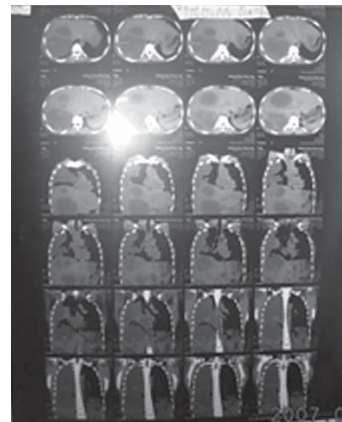
- CT scan of the patient's chest and abdomen was done with contract enhanced.

CT scan of chest and abdomen revealed.

1. Multiple huge abscesses in liver.
2. Rupture of one of the liver abscess.
3. Rupture of Rt. Diaphragm.
4. Liver abscess community with Rt. pleural cavity with Empyema formation.

5. Collapse of Rt. lung lower lobe.

6. Rt. lung lower lobe communicating with liver abscess with formation of Broncho-Hepatic-Fistula.



**Fig. 5:** Pre operative CT scan

- 11.04.2063 Rt. Thoracotomy operation was done.

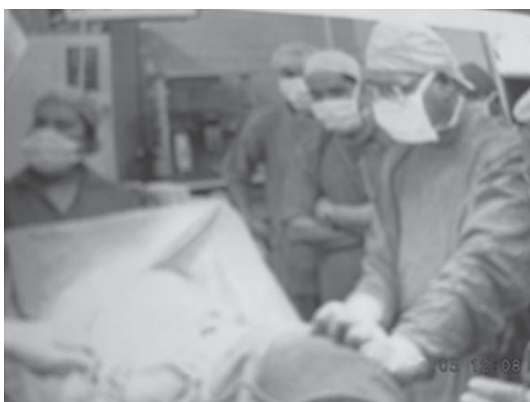- The operative findings were:

1. Huge multi loculated Empyema cavities over Rt. pleural cavity.
2. Collapse of Rt. lung upper and middle lobe with thicked pleura.
3. Rt. lung lower lobe destroyed and alherent to diaphragm.
4. There was large rupture in central tendon of Rt. diaphragm.

5. Large liver abscess cavity communicating to Rt. lung lower lobe.

## Operation

1. Rt. Thoracotomy
2. Cleaning of pus from Rt. Pleural cavity.
3. Decortiation of Thick pleura on Rt. lung upper and middle lobes.
4. Rt. lower lobe of Rt. lung dissected and Rt. Lower Lobectomy done Rt. Bronchial opening closed with Proline suture.
5. Liver abscess cavity closed after opening cholangitic ducts opening were closed, Haemostasis secured.
6. Rt. Diaphragmatic rupture closed in layer with silk suture.
7. After Haemostasis and Aero-stasis secured chest closed in layers with one chest tube drain.

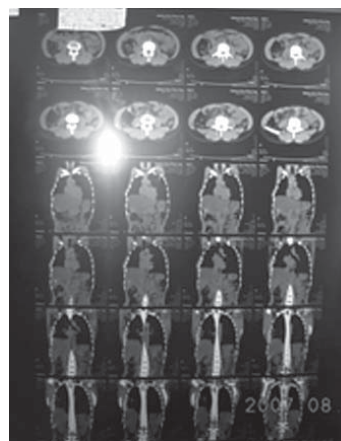


**Fig. 6:** During Operation

## Post Operative Period

- Patient had smooth post operative recovery.
- Chest drain was continued for long time for 6 weeks with chest physiotherapy for satisfactory Expansion of obliteration Rt. lung and of Empyema cavity.
- Patient had antibiotics and Metronidazole for 6 weeks.

Follow up: Follow up CT scan of chest and Abdomen shows:



**Fig. 7:** Post Operative CT Scan

## At 5 weeks post operative

1. Rt. lung expansion and decrease in Rt. Empyema cavity.
2. Reduction in size of liver abscesses.

## At 12 weeks

- Rt. lung was fully Expanded with obliteration of Rt. Empyema cavity
- All liver abscesses were fully resolved.
- Patient was discharged on 29/08/2063 (15<sup>th</sup> Dec. 2006)

## Follow up after one year of operation:

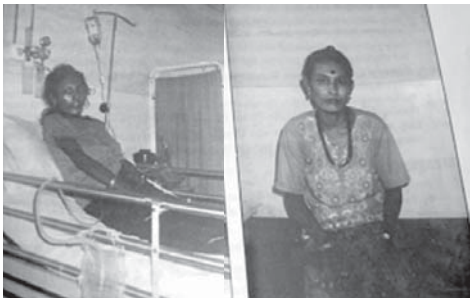Patient was healthy with normal pulmonary function. No hepatomegaly and no liver abscess detected on ultrasound examination

## Discussion

Liver abscess both pyogenic and Amoebic are still common in medical practices in Nepal. Most of the liver abscesses detected early do response well with Antibiotics and Metronidazole treatment.

Ultrasound and CT Scan picture of liver abscess may resemble with picture of CT scan of patient with hydatid cysts of liver. (Rajbhandary G.L.)

Early cases of Liver Abscess both amoebic and pyogenic do response well with conservative medical management with antibiotics and aspiration.



**Fig. 8:** Pre & Post Operative Photo of Patient of rupture of liver abscess with formation of Broncho-Pleural Fistula

But we still come across patients with complication of rupture of liver abscess. Liver abscess with rupture into Rt. Pleural cavity with formation with Broncho-Pleural Fistula has been reported by this author in Medical Journal of Birendra Army Hospital MJSBH, Vol III 2000. (Rajbhandary G.L)

Liver Abscess with rupture into Rt. Lung with direct communication of bronchial opening of Rt. lung with liver abscess cavity with formation of Broncho-Hepatic Fistula is not so common. Very few cases of rupture of liver abscess with formation of Broncho-Hepatic-Fistula has been published in Literature. (Sekar NN et al 1986, Kapoor OP 1990).

### Acknowledgement

I would like to thank Mrs. Sandya Rajbhandary for web search of literature and would like to thank T/ Sub. Balram Thapa & Sep Rabindra Raut for computer compilation of this original article.



**Fig. 9:** Patient Med Vac to Birendra Hospital

### Conclusion

1. Early detection of Liver Abscess by Ultra sound examination of abdomen in patient with fever and hepatomegaly is advised to prevent complication of rupture of liver abscess.
2. Late complication of rupture of liver abscess with Broncho-Hepatic- Fistula (Broncho-Biliary-Fistula) can be managed satisfactory with surgery and antibiotics.

### References

1. Sekar N.N. Chandra Mohan, SM, Kanna KK, Vekatarmus MS, Spontaneous Bronchus Biliary Fistula- An unusual complication of a acalculous cholecystitis ( a case report).
2. Rajbhandary G.L., Surgical Experience with Burst Liver Abscess complicating Empyema Thoracic and Broncho Pleural Fistula, MJSBH, Vol III, 27-30, 2000.
3. Kapoor OP, Amoebic Liver Abscess in surgical Amoebiasis treatment is often conservative, Bombay hospital Journal, Vol. 32 No 3, 1990 Page 128-133.
4. Ibara Peraz, C: Thoracic complication of Amoebic Abscess of Liver Report of 501 cases, Chest, 79:672, 1981.
5. Huang CI, Piff HA, Lipetf PA etal. Pyogenic Hepatic Abscess Changing trends over 42 years. Aun Sueg. 1996, (5), 223.
6. Rajbhandary G.L., Hydatid cyst of liver complete resolution following Albendazole treatment J. Nep. Med. Assoc. 1995, 33, 131-132.
7. Chau FF, Shem – Cheen - Cheen S.M., Chen YS. Single and multiple liver abscess rupture of pyogenic liver abscess. World J. Surg. 1997 May : 21 (4) : 384-8.
8. Peralta R, Lisgaris MV Salata RA etal, Liver abscess updated 2006 E-Medicine, WebMD, 1516 htm.