

Folliculitis Decalvans and Pyoderma Gangrenosum

Sudarshan LR★, Jagat S P◇

1. Folliculitis decalvans

Types of alopecia commonly observed in our Skin OPD are Androgenic, telogen, anagen, drug induced, endocrinal, systemic disease, alopecia areata, tinea capitis, bacterial, discoid lupus erythematosus, lichen planus, pseudopelade.

Folliculitis decalvans is a rare chronic progressive follicular pustular eruption that results in cicatricial alopecia of scalp or other area.

It usually occurs in females of 30-60 years and after adolescence in males.

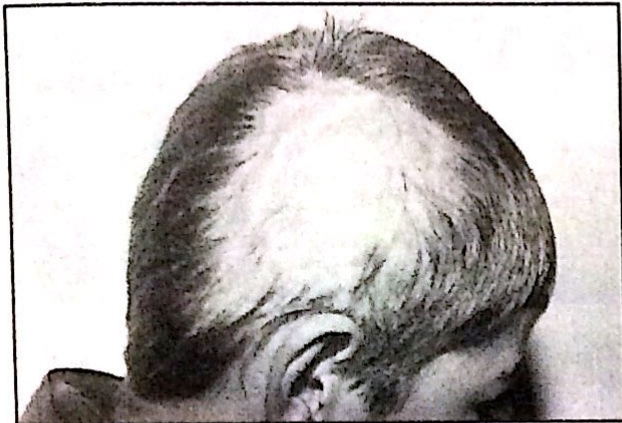


Figure 1: Alopecic patch 14 cm x 10 cm right temporal region with one linear bulla on one side of periphery

Case report

A 13 years old male child presented on 27th December 2003 with painful patchy hairless area over scalp of 6 month duration patient gives history of excessive wetting of scalp every 20-30 days each lasting for a few days.

There is no family history of similar illness

Patient has not been on treatment so far.

Examination revealed erythematous oedematous alopecic area of 12x10 cm on right temporal region.

★ Dr. Sudarshan Lal Rajbhandari, MBBS, MD
Col., Consultant Dermatologist

◇ Dr. Jagat Singh Pande, MBBS, MD
Lt Col., Consultant Pathologist
Shree Birendra Hospital, Chhauni

Surface at places show oozing. A linear bulla is seen at one side of periphery. Patch is tender, indurated and crusts felt. Other areas of scalp show severe seborrhoea.

Biopsy finding

Epidermis -- normal

Dermis -- sheets of lymphocytes, numerous plasma cells, a few macrophages, a few neutrophils and at places fibrosis in perifollicular areas in deep dermis consistent with folliculitis decalvans. No evidence of pseudopelade.

Sheets of, plasma cells, lymphocytes, a few neutrophils perifollicular region



Figure 2: (Microphotograph showing Sheets of, plasma cells, lymphocytes, a few neutrophils at perifollicular region)

Magnified view of perifollicular region

Treatment patient was treated with topical mupirocin, ketoconazole shampoo, ceftriaxone axetil for 10 days, Rifampicin for 60 days. On August, after 4 months of completion of treatment patients father says patient has regrowth of hair. Again in 1st of Nov patient's father says he went home a few days ago and he shaved the affected area according to doctor's instruction and notices pitted scars He was cautioned as a part of

counseling that the hair may restart falling and if so to inform the doctor at the earliest. Folliculitis decalvans is known to be recalcitrant to treatment.

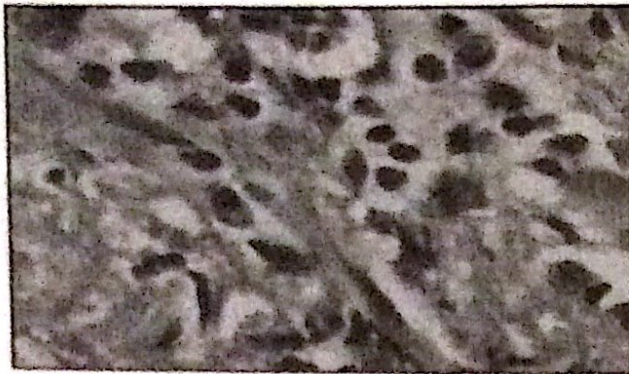

Figure 3: (Magnified view of perifollicular region)

References

1. Dawber, R.P.R., Ebling, F.J.G. and Wajnarowska.: Disorders of hair. In Champion, R.H., Burton, J.I. and Ebling, F.J.G eds. 'Textbook of Dermatology' 5 ed. iv vol. 1996 p.2600-1
2. Wadhwa, S.L., Khopker, U. and Mhaske, V.: Hair and scalp disorders. In Valia, R.G. and Valia, A.R. eds. 'Textbook and Atlas of Dermatology' 2nd ed; 1st vol. 2001 p.741. Bhalani Publishing House, Mumbai.

2. Pyoderma gangrenosum

It was first described by Brunsting and colleagues in 1930. It is a rare destructive, inflammatory, necrotic disorder of skin and presents with tender, erythematous pustule turning to blue, black and then progressively enlarging ulcer with undermined raised borders. It may remain single or develop in to multiple lesions mostly involving lower legs. Pathergy is common. Biopsy, insect bite and trauma may induce new lesions. May occur idiopathic or in association with systemic diseases like inflammatory bowel diseases, connective tissue diseases, hepatic, renal disorder, carcinoma, leukemia etc.

Case report

A 54 years old exserviceman from Pokhara presented with progressively growing ulcers with serous haemorrhagic discharges of 4 years duration on 2nd March 2004.

Initially patient had leech bite at right ankle, taken out by the patient which caused development of nonhealing ulcer. Similar lesions started appearing spontaneously at other sites like; dorsa both feet, ankles, fingers, toes, legs, elbows, forearms, upperarms, scrotum and both pinna.

Clinical findings

Each ulcer had raised undermined border, surface was covered with serous or haemorrhagic crusts, base was indurated and tender. Ulcers were polysized, distributed over dorsa feet, ankles, legs, knees, elbows, pinna and scrotum

Pulp of the fingers and toes had pustules, dorsa feet showed bluish pustules

Old healed scars were seen over all 4 limbs.

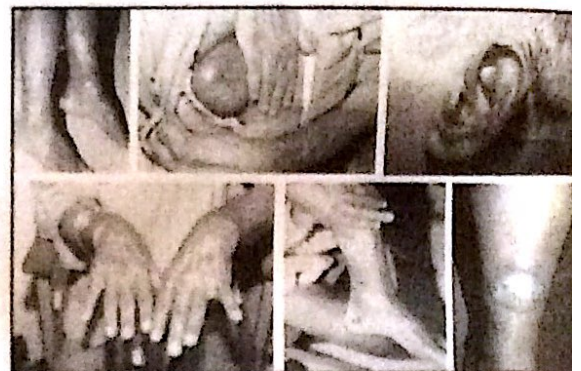

Figure 4: A= Old healed scars over both lower limbs
B= Ulcers over the scrotum, C= Nodules over pinna, D = Scars and ulcers over both hands, E = New pustules over ankle, F = Healing over shin of leg)

Biopsy findings

Date 12/3/004 from pustule (ankle) and ulcer (left hand)
Epidermis spongiosis

Dermis- suppurative abscess at upper dermis associated with abundant neutrophils, many neutrophils, many lymphocytes, a few plasma cells, a few macrophages. follicular structures not seen.

Date 27/7/004 from pustule knee

A nodular dermal infiltrate rich in neutrophils associated with perivascular lymphocytic infiltrates. Many arrector pili muscles remnant not associated with neighbouring follicles.

epidermis unremarkable.

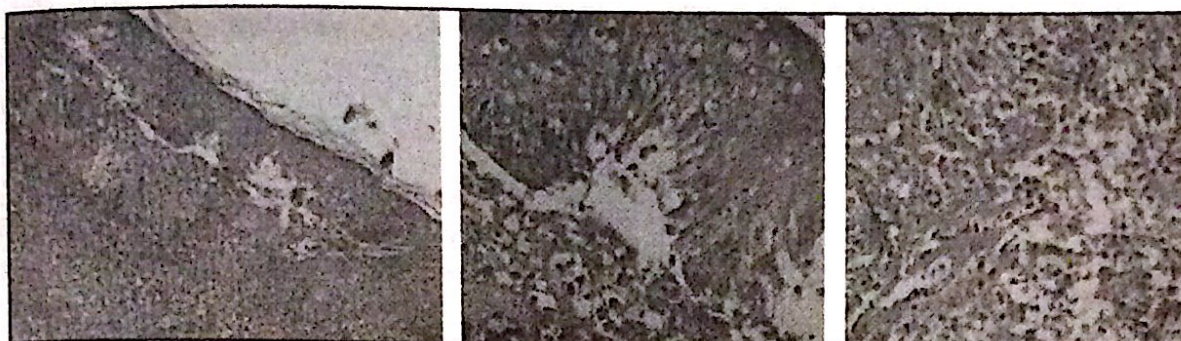

Figure 5: (A = Photomicrograph showing diffuse and nodular dermatitis with many neutrophils with lysis of superficial dermis, B = Magnified view of A showing intra-epidermal neutrophils, C = Nuclear dusts, the neutrophils and lymphocytes at the superficial dermis)

Drug response

As the disease belongs to neutrophilic disease spectrum, minocycline, dapsone, colchicine, zinc sulphate were first tried along with analgesics and topical antibiotic. Lesions remained progressively growing, then it was treated with 1 gm methylprednisolone IV once a day for 5 days, topical steroid as creams and local infiltration.

Drug response was dramatic, all lesions started healing, and tenderness disappeared. patient was discharged with Sulphasalazine tab 2 gm. once a day for 30 days.

One month later the patient was again readmitted for appearance of new ulcers associated with oozing, crusting, bleeding, bluish and blackish necrotic areas and oedema over both legs.

He was treated with 2nd pulse of methyl prednisolone, oral analgesic and proton pump inhibitor which showed slight improvement.

Clofazimine 100 mg three times a day was started followed by Cyclosporin 500 mg once a day.

After 1 month the lesions subsided. Cyclosporin was reduced to 200 mg but within the next 3 days new lesions started appearing, so again it was raised to 500 mg once a day and 200 mg Clofazimine once a day.

Cyclosporin was started on 2nd August till Nov 14, so administered for around 100 days, with much improvement but in view of its side effects like loss of appetite, diarrhoea, headache which developed in our patient, it was discontinued.

Presently, the patient is on Clofazimine 100 gm twice a day, Cyproheptadine, Prantoprazole, topical

Clobetasole and Silversulfadiazine. So, far, his lesions remain subsided.

Discussion

The objective of this study is to identify Pyoderma gangrenosum as a possible cause of this condition and recommend appropriate treatment accordingly.

Punch biopsy from ulcer (elbow) pustule (ankle) did not show follicular remnants supporting suppurative folliculitis as initiating event.

PG is fundamentally not a vasculitis but a suppurative folliculitis. Some authors believe it as primary vasculitis.

This condition has been described in literature available till date as occurring in 50% patients as an idiopathic condition and 50% as a systemic disease.

Abnormalities of humoral, cell mediated immunity, complement, neutrophil, monocyte function were noticed by others.

Defective neutrophil chemotaxis and neutrophil phagocytosis have also been reported.

It has been suggested that deposition of immune reactants in dermal vessel walls may be important in pathogenesis of diseases.

Spectrum of drugs used to treat this condition is wide. Immunosuppressants like Cyclosporine, Azathioprine and neutrophil phagocytic enhancers like Clofazimine are used.

Cyclosporine acts preferably on T cells probably by limiting production of Interleukin 2 and in

particular by preventing precursor TH cells from acquiring ability to respond to IL 2. This inhibit proliferation and maturation of TS cells.

The course and prognosis of this condition is chronic and progressive.

Conclusion

Our case study clearly illustrates that pulse steroid therapy is beneficial.

Continued need for suppression of inflammatory process following pulse therapy by use of Combination of clofazimine, cyclosporin and topical agents are required.

References

1. Cutaneous vascular disease Arnold, H.L., Odom, R.B. and James, W.D. 'Andrews' Diseases of the skin ed; 1990. p.986-8. W.B. Saunders Company
2. Pyoderma Gangrenosum. Histologic diagnosis of inflammatory skin diseases 2nd ed; p 677, A Bernard Ackerman 1997, Williams Wilkins
3. R.K. Curley, R.K., Macfarlane A.W. & Vick G.F.H. Pyoderma gangrenosum treated with cyclosporin. British Journal of Dermatology Nov 1985. Vol. 113 No. 5. 601 - 04.