

Stress Fractures in Female Officer Cadet Trainees

Jha R.¹, K.C. B.R.², Chand P.³

Abstract

Ten female officer cadet trainees (out of 70) presented with stress fractures, amongst which seven had pubic rami fractures while undergoing basic training. This high number of pubic rami fractures is considered to be caused by the introduction of mixed training of male and female cadets, thereby forcing women to increase their stride length when marching, as well as due to the peculiar morphological anatomy of the female pelvis.

The main presenting symptom was chronic persistent pain which failed to get relieved with NSAID and the clinical diagnosis was confirmed by radiographs in all except one which was diagnosed by magnetic resonance imaging (MRI).

Stress fractures of pelvic rami only, was seen in 7 trainees.

All fractures healed with rest and supportive therapy. One fracture neck of femur needed prophylactic internal fixation (CRIF).

Introduction

There are many studies done regarding the incidence, etiology and treatment of stress fractures¹. The incidence in military recruits has been reported to range from 12% in female Caucasian American recruits to less than 2% in male recruits². Factors known to increase the incidence include female gender^{3,4}, youth⁵, Caucasian race², lack of pre-entry physical conditioning⁶ and mixed training of men and women⁷.

Stress injuries in normal bone due to repeated cyclic loading are a well-recognized complication in military training⁸. Breilhaupt, a Prussian military surgeon, first described the symptoms of stress fractures in military recruits in 1855, and in 1897 Stechow identified these injuries radiologically⁹.

Stress fracture of the pubic ramus was first described in three male military recruits by Wachsmuth in 1937.

Materials and method

Ten female officer cadet trainees presented with stress fractures (Batch strength -70) at Birendra Hospital, Chhauni. Among them there were,

- | | |
|----------------------------|-------------------|
| a. Pelvic rami fractures | - 7 |
| b. Tibial fractures | - 3 (1 bilateral) |
| c. Fracture neck of femur | - 1 |
| d. 3rd metatarsal fracture | - 1 |




Fig. 1 Showing tibial stress fracture

The training; duration of 52 weeks, was designed to teach basic military skills such as weapon handling, discipline, field craft, battle craft and drill. It also aims to improve physical stamina with or without backpacks. Fitness was assessed by the compilation of distance. Covered by running within certain time as laid down in Army training directive. The intensity of training increased progressively until the cadets sat for their examination and took their physical tests.

All the cadets had met with the medical requirements for army entrances and were within the normal range for height and weight. All women had a normal menstrual history.

1. Dr. Raghavendra Jha, PG Resident (NAMS)
2. Dr. B.R. K.C., MBBS, MS
Col., Chief Post Accident Center, SBH
Associate Professor, NAMS
3. Dr. P. Chand, MBBS, MS
Lt. Col., Consultant Orthopaedic Surgeon, SBH
Clinical Tutor, NAMS

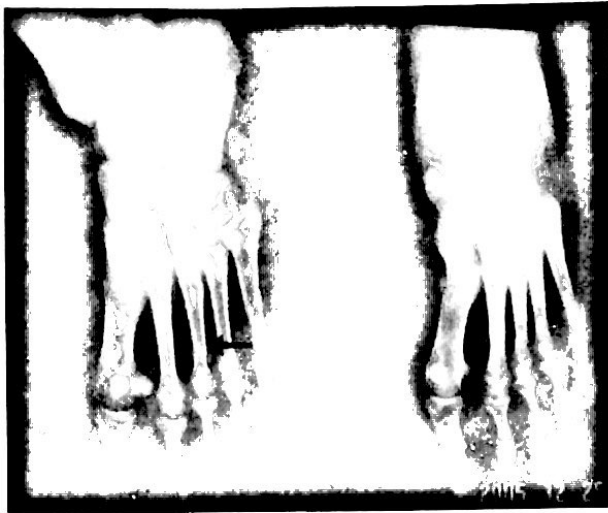


Fig. 2 showing 3rd metatarsal stress fracture

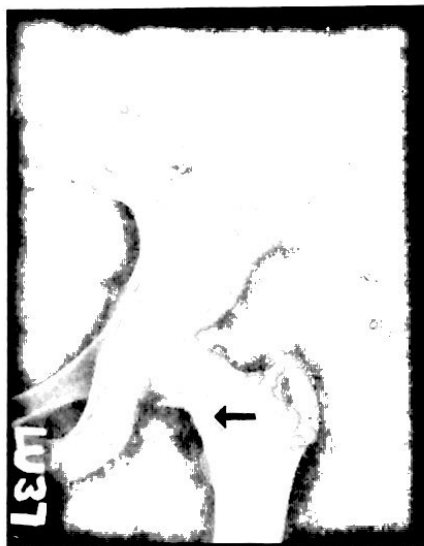

Fig. 3 Showing stress fracture of the femoral neck

Stress fractures of the pubic rami were diagnosed by finding tenderness over the inferior pubic rami and over the insertion of the adductor muscles along with a decreased range of abduction associated with pain. There was also pain on resisted adduction and external rotation of hip and an antalgic gait. Standard anteroposterior radiographs of the pelvis were taken and in one patient a MRI was performed to confirm the diagnosis when the initial radiographs were inconclusive. No bone scan was performed.

Results

Out of the 10 female officer cadets who presented with stress fractures, there were 8 stress fractures of pubic rami in 7 cadets. 5 had only inferior pubic rami fracture (left sided 3 and right sided 2). One had superior pubic ramus fracture of right side and

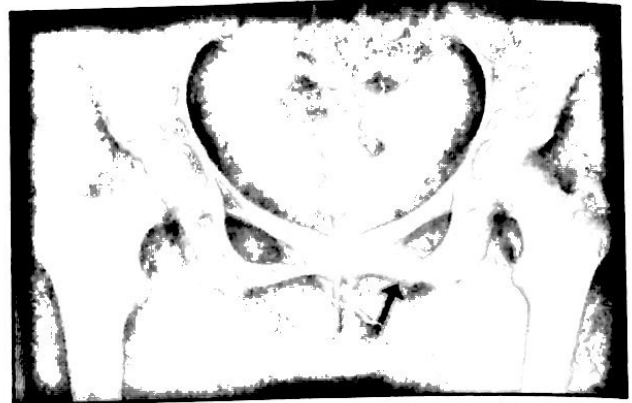

Fig. 4 Showing inferior ramus stress fracture.



Fig. 5 Showing inferior ramus stress fracture.



Fig. 6 Showing stress fractures of superior and inferior rami



Fig. 7 Showing internal fixation of fracture of neck of femur

one had both superior and inferior pubic rami fractures of left side. Involving 10% of all female cadets.

The mean onset of symptom was in 3rd week of training, and all presented within 6 weeks of training. The activities during training when the symptoms set in were speed marching with backpacks, running and assault courses.

Almost all the fractures were near the pubic symphysis. Radiographs usually showed some callus formation around the fracture sites indicating healing. Management included rest, physiotherapy and non-steroidal anti-inflammatory drugs. All patients had full resolution of all symptoms. Patient with fracture neck of femur needed internal fixation.

Discussion

Stress fracture are classically described in military recruits and athletes in which normal bone is exposed to repeated sub threshold cyclic loading. Majority occur in the bones of lower extremity mainly the tibia and fibula (50%), Femur (5-10%), metatarsals and pelvic rami follow in decreasing order.

Our series showed an incidence of 14% (10 out of 70) of the trainees suffering from stress fractures as compared to 12% reported in female American recruits². More surprisingly, pelvic rami fractures constituted the bulk (70% 7 trainees out of 10). The cluster of pelvic rami stress fractures almost exclusively in women within 6 weeks of training, prompted us to investigate the causes.

As there was a joint training programme of male and female cadets, the females had difficulty in keeping up with male counterparts when marching together in squads. Oxburn and Nicholas (1981) also found an increase in number of stress fractures of female pelvic rami during integrated training in the USA⁷. They considered that the relatively shorter females in mixed squads were obliged to overstretch and had to march at the front of the column to reduce over striding, needed to keep pace with their colleagues. This increased in loading around the inferior pubic ramus.

The increase in loading around the inferior pubic ramus by an unnatural gait due to overstriding is one of the primary mechanisms of stress fractures in female trainees.

In women, bones of pelvis are more cylindrical, the pubic symphysis is shallower, margins of ischiopubic rami are less everted with less ischium pubic index. They have less muscle mass than male thus absorbing shock less (as muscle acts as shock absorber). This peculiar morphological anatomy of

the female pelvis might also contribute to stress injuries of the pelvic rami.

According to Prozman and Griffis (1977) and Hulkko and Orava (1987) there is a female athlete triad 3,4; which leads to stress fractures.

- I. Irregular menstruation - increased estrogen levels lead to decreased bone mineral densities.
- II. Disorders of eating - food restriction/fasting, low calcium intake, eating disorder etc.
- III. Osteoporosis

Conclusion

Stress fractures occur in all age groups where repetitive activity is performed but females are specially at a higher risk.

In our series stress fractures of the pelvic rami were the commonest.

Proper conditioning, proper equipment and foot wear with well designed training programs might prevent many stress fractures.

Reference

1. Lancet stress fractures: editorial Lancet 1986; ii : 727
2. Brudvig T J, Gudger T D, Obermeyer L. stress fractures in 295 trainees: a one year study of the incidence as related to age, sex and race. Milit med 1983; 148: 666 -7.
3. Prozman RR, Griffis CG. stress fractures in men and women undergoing military training. J Bone and Joint surgery (Am) 1977;59-A:825.
4. Hulkko A, Orava S. stress fractures athletes. Int. J. sports med 1987; 8: 221- 6.
5. Milgrom C, Finestone A, Shlamkovitch N et al. Youth is a risk factor for stress fracture: a study of 783 infantry recruits. J bone joint surgery (Br) 1994; 76-B:20-2.
6. Gilbert RS, Johnson HA stress fractures in military recruits: a review of twelve years, experience. Milit med 1966; 131; 716-21.
7. Oxburn MS, Nichols JW. pubic ramus and adductor insertion stress fractures in female basic trainees milit med 1981; 146: 332-4.
8. Meurman KO. stress of the pubic arch in military recruits; Br. J. Radiol 1980; 53: 521-4.
9. Stoneham MD, Morgan NU. Stress fractures of the hip in Royal Marine recruits under training: a retrospective analysis. Br J sports med 1991;25:145-8.