

Bilateral Three Headed Biceps Brachii Muscle

Poonam Singh ¹, Aseem Tandon ², Rajan Bhatnagar ³, Rishi Pokhrel ¹

¹Department of anatomy, Armed Forces Medical College, Pune, India.

ABSTRACT:

During routine human cadaveric dissection for the purpose of teaching learning of medical undergraduates in our department, third head of the biceps brachii muscle was found bilaterally in a 67 years old male cadaver. Bilaterally symmetrical third head was found with fleshy proximal attachment on humerus between the insertion of the coracobrachialis and the upper part of the origin of the brachialis. This supernumerary head was deep to the other two heads of biceps and was inserted into the bicipital aponeurosis. A branch of musculocutaneous nerve could be traced upto the third head. Long and short heads of biceps were of usual anatomy.

KeyWords: biceps brachii, supernumerary head.

INTRODUCTION

Biceps brachii is a two-headed muscle, which consists of a long head and a short head. Long head arises from the supraglenoid tubercle and adjoining part of glenoid labrum of the scapula, passes through the synovial cavity of shoulder joint then emerges below the transverse humeral ligament and passes through the bicipital groove of the humerus covered by the synovial sheath. Short head has a tendinous origin from the coracoid process of the scapula lateral to the coracobrachialis. This expands into a fleshy belly which lies parallel to the fleshy belly of long head both merging with each other just above the elbow joint.

The combined tendon is inserted into the posterior border of the radial tuberosity. At the level of elbow joint it also forms bicipital aponeurosis, which is inserted into the subcutaneous border of the upper end of the ulna by way of the deep fascia of the forearm. Biceps brachii is innervated by the musculocutaneous nerve (root values: ant division of ventral primary rami of C5, C6) with one branch to each belly. Blood supply is from the Brachial and anterior circumflex humeral arteries.

It is one of the most variable muscles in human being, third head being a common variation, though

supernumerary heads up to 8 have been recorded in previous literature ^[1]. Most of the articles mention supernumerary head of biceps occurs unilaterally, and bilateral occurrence is rare. We report a case of bilateral three-headed biceps brachii muscle in an adult.

CASE REPORT

During routine human cadaveric dissection carried out in our department, a three headed biceps brachii muscle was found bilaterally in a 67-year-old male cadaver. In both the arms long and short heads were of usual anatomy i.e. proximal and distal attachments, and nerve supply.

Additional head in both arms arose from humeral shaft, between the insertion of the coracobrachialis muscle above and the upper part of the origin of the brachialis muscle below. Third heads were bilaterally symmetrical with fleshy origin. They lay deep to the other two heads of biceps and were inserted into bicipital aponeurosis. Separate branch was given from the musculocutaneous nerve to this additional head. No other accompanying variations were seen or found in the upper limb (figure 1-3).

The human cadaver used in the dissection was obtained through our department's body donation programme following all ethical guidelines.

.....
Correspondence:

Poonam Singh

Department of Anatomy, Armed Forces Medical College,
Pune, India.

Email id: poonam_37@hotmail.com

DISCUSSION AND REVIEW OF LITERATURE

Biceps brachii is one of the most variable muscles of the human body with an occurrence rate of variations ranging from seven to 37% of populations. Supernumerary heads are found more commonly in males². Extra heads may present as a belly similar to usual heads or may be present as a group of accessory fascicles arising from either of these:- Head of the humerus, shaft of the humerus, coracoid process, pectoralis major and pectoralis minor tendon, capsule of the shoulder joint or V- Shaped insertion of deltoid muscle in humerus. The commonest origin is from the proximal part of humerus as in our case, hence also called as humeral head. Bilateral occurrence is less common³⁻⁶. Occurrence of this variation is population specific and has been compared with the findings of various researchers in table 1.

Table 1: Incidence of supernumerary heads of biceps brachii muscles in various populations as reported in literature.

Author & Year	Population	% Occurrence of third head of biceps
Bergman RA, 1984 ^[7]	Europeans	10
Kosugi K, 1992 ^[8]	Japanese	18
Asvat R, 1993 ^[9]	South African Whites	8.3
	South African black	20.5
Kopuz, 1999 ^[10]	Turkish	15
Rincon F, 2002 ^[11]	Columbians	37.5
Rai R, 2007 ^[5]	Indian	7.1
Poudel R, 2009 ^[12]	Nepalese	12.5

This extra third or humeral head can sometimes continue inferiorly deep or medial to the main tendon of biceps brachii and cause compression of neurovascular structures because of its close relation to the brachial artery and the median nerve. Although such an extra head definitely confers additional strength to the biceps brachii muscle, it possibly represents a phylogenetically degenerating structure and does not perform any significant function. Hence plastic and reconstructive surgeons, in various auto grafting procedures, can use this independently innervated and vascularized muscular tissue valuably.

Presence of such an extra head may also influence the course and branching pattern of the Musculocutaneous nerve. Such an extra structure, however, can be very

easily confused with pathological conditions such as soft tissue tumors in absence of the knowledge of existence of the variation^{2,4,6}.

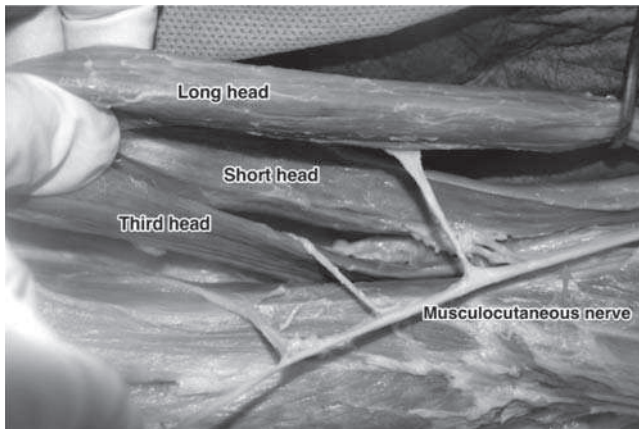
Prevalence of supernumerary heads of biceps brachii muscle is not rare. Knowledge of the variations of the biceps brachii muscle is important in numerous fields ranging from physical anthropology studying human evolution, basic medical sciences like human anatomy studying the normal structure of human body as well as more applied specialties like oncology, general, orthopedic or reconstructive surgery. Ignorance of presence of such a variation can inadvertently lead to iatrogenic injuries during surgery and invasive procedures.

Figure 1: A. Right arm showing three heads with third head arising from approximately the middle of shaft of humerus. B. Right arm showing the insertion of third head into the bicipital aponeurosis.

Forceps pointing at the belly of third head and *: bicipital aponeurosis.

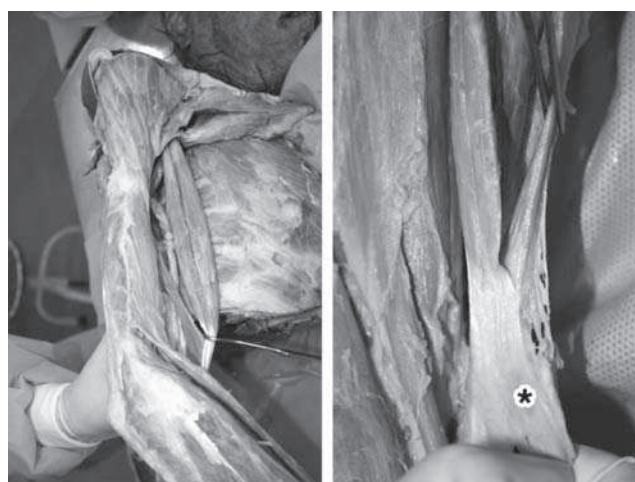

Figure 2: Individual branches from musculocutaneous nerve to each of three heads.



REFERENCES

1. Hollinshead WH. Anatomy for surgeons: Hoeber-Harper; 1958.
2. Vijayabhaskar P, Baral P, R Vaishya, Shrestha R. Supernumerary head of Biceps brachii” A rare occurrence in the Nepalese population. Kathmandu University Medical Journal. 2008;6(22):225-7.
3. Kumar H, Das S, Rath G. An anatomical insight into the third head of biceps brachii muscle. Bratisl Lek Listy. 2008;109(2):76-8.
4. Shashikala RL, Ashwini SJ. Case report: Third head of biceps brachii muscle a case study Biomedical Research. 2011;22(3):387-9.
5. Rai R, Ranade AV, Prabhu LV, Pai MM, Prakash. Third head of biceps brachii in an Indian population. Singapore Medical Journal. 2007;48(10):929-31. PMID:17909679
6. Lee JH, Choi IJ, Kim DK. The third head of the biceps brachii muscle originated from the pectoralis major muscle. The Korean Journal Anat. 2008;41(4):231-2.
7. Bergman RA, Thompson SA, Afifi AK. Catalog of human variation: Urban & Schwarzenberg Baltimore; 1984.
8. Kosugi K, Shibata S, Yamashita H. Supernumerary head of biceps brachii and branching pattern of the musculocutaneous nerve in Japanese. Surgical and Radiologic Anatomy. 1992;14(2):175-85. <http://dx.doi.org/10.1007/BF01794898>. PMID:1641744
9. Asvat R, Candler P, Sarmiento EE. High incidence of the third head of biceps brachii in South African populations. J Anat. 1993;182:101-4. PMID:8509293
10. Kopuz C, Sancak B, Ozbenli S. On the incidence of third head of biceps brachii in Turkish neonates and adults. Kaibogaku zasshi Journal of anatomy. 1999;74(3):301-5. PMID:10429374
11. Rincon F, Rodriguez ZI, Sanchez A, Leon A, Gonzalez LF. The anatomic characteristics of the third head of biceps brachii muscle in a Colombian population. Rev Chil Anat. 2001;20(2):197-200.
12. Poudel P, Bhattarai C. Study on the supernumerary heads of biceps brachii muscle in Nepalese. Nepal Medical College Journal. 2009;11(2):96-8. PMID:19968147