

## Schwartz - Jampel syndrome

Bastola P<sup>1</sup>

<sup>1</sup>Department of Ophthalmology,  
Gandaki Medical College, Pokhara, Nepal

### Corresponding author

Dr Pradeep Bastola

Department of Ophthalmology

Gandaki Medical College and Research Centre,  
Pokhara, Nepal.

Email: pbs\_dinku@yahoo.com

Kathmandu Univ Med J 2010;8(31):348-51

### ABSTRACT

This is a report of a very rare case of Schwartz Jampel syndrome, with few unusual findings, in a 13 years girl from Nepal, who concurrently also had superotemporal subluxation of the crystalline lens along with blepharophimosis syndrome.

### Key Words

*blepharophimosis, genetic mapping, schwartz and jampel, subluxation of lens,*

## INTRODUCTION

The first described cases of Schwartz Jampel Syndrome (SJS) were reported in 1962 by Oscar Schwartz and Robert S. Jampel in the Archives of Ophthalmology in an article titled "Congenital blepharophimosis associated with a unique generalized myopathy."<sup>1</sup> These described cases typically had congenital blepharophimosis (ie, decreased palpebral fissure with normal eyelid development), unusual facies characterized by a puckered facial appearance, Small muscle mass and joint deformities (eg, coxa valga, irregularity of the capital femoral epiphyses, pectus carinatum ("pigeon breast"), hypertrichosis of the eyelids, slightly elevated serum aldolase level. Electromyographic changes pattered in muscle is also a distinguishing feature of this syndrome; very few cases have been reported world wide since the first two cases have been reported by Schwartz and Jampel. It is an autosomal recessive disease, with history of consanguinity in the family in few reported cases.<sup>2</sup>

## CASE REPORT


A 13 years girl presented to us with complaints of diminution of vision in both the eyes since 8 years duration, mild muscle stiffness and an unusual facial expression gradually worsening since 8 years duration. A thorough ocular examination revealed an impaired visual acuity (unaided), which improved to 6/18 in both the eyes with pin hole, with refraction the patient was found to have compound myopia which was high, though vision improved to 6/12. External ocular examination revealed blepharophimosis syndrome, hypertrichosis. Conjunctiva, cornea looked normal. Anterior chamber depth was deep, in the centre. The crystalline lens was subluxated superotemporally in both the eyes (Figure 1). Vitreous cavity showed myopic vitreous degeneration and similarly the retina showed severe choroidal sclerosis and myopic changes in both the eye. Optic disc when seen from the aphakic portion was hypermetropic type, while when seen from the phakic portion it was of myopic type. A typical facial appearance micrognathia; unusual flattened facies with a puckered facial appearance; and small muscle mass was evident (Figure 2, 3). Various differential diagnosis was kept in mind and a thorough past history and past treatment as well as hospital records were seen. A medical past history revealed there was no consanguinity in the family and the patient was the only child in the family. The patient had a normal hospital delivery with antenatal, intranatal and post natal periods all uneventful. Baby after birth was fully vaccinated and was

achieving all the milestones in time. It was when the baby was 4 years of age the patient's mother noticed somekind of difficulty in walking, with a slight change in facial appearance. Then the baby was taken to various hospitals in Nepal as well as abroad. Ophthalmologists regularly saw the growing baby as she was having difficulty in seeing far, and was prescribed spectacles accordingly. At the same time the baby started having mild grade muscle stiffness and myotonia, while weight and the height of the baby for her age was normal. The baby was having progressively increasing muscle stiffness for which she was given some muscle relaxants by the neurologist. The patient is still taking the treatment, as per the informant though the dose was adjusted according to her growing height and weight. The patient had history of a slight delay in mental status, while growth was normal. Other investigations in the past revealed a pigeon like chest as evident by X – Ray chest, while other investigative findings done in Nepal were not pointing towards any conclusive diagnosis. Old documents revealed differential diagnosis of Marfan's syndrome, Homocystinuria, Weil Marchesani Syndrome etc, but the investigations done to rule out these diseases came out negative. The patient then was taken abroad to India and United Kingdom, for further evaluation. In United Kingdom, a genetic mapping, and Electromyography was carried out, the genetic mapping showed a defect in Chromosome number 1, and a clinically correlating Electromyographic (EMG) finding, then a conclusive diagnosis of Schwartz Jampel Syndrome was made, though the concurrent occurrence of subluxation of crystalline lens supero temporally was not described in detail.

## DISCUSSION

The Schwartz-Jampel syndrome also known as Chondrodystrophic myotonia or Aberfeld Syndrome or Schwartz Syndrome (SJS) was first described in 1951 by Cat et al. and was better defined in 1962 by Schwartz and Jampel.<sup>2</sup> It is a term now applied to 2 different autosomal recessive inherited conditions, sometimes termed SJS type I and SJS type II. Both are very rare. SJS type I has 2 recognized subtypes, IA and IB, which are similar except that type IB manifests earlier and with greater severity. The most commonly recognized and described type is IA, which exhibits muscle stiffness, mild (and largely nonprogressive) muscle weakness, and a number of minor morphological abnormalities.<sup>3</sup> Type IA is the classic type described by Schwartz and Jampel. Types IB and a type II have also been delineated. Type IA becomes apparent later in childhood and is less severe. Type IB is apparent immediately at birth and is more severe clinically, although typically compatible with life and even long-term survival.

Types IA and IB derive from mutations of the same gene, the HSPG2 gene, which codes for perlecan, a heparin sulfate proteoglycan. The case which is been reported in this particular case note is, Type IA. Hence, indicating a longer survival of the patient, as well as a delayed manifestation of the disease process. Type II, like type IB, is apparent immediately at birth. The patients look similar to those with type IB. However, it was known for many years that type II does not map to the same chromosome as types IA and IB. It is now known that type II relates to a mutation in a different gene, the gene for the leukemia inhibitory factor receptor (LIFR).<sup>4</sup> This is the same disease as Stuve-Wiedemann Syndrome (SWS), which has been known separately, mainly in the rheumatologic and orthopedic literature, rather than the neurologic literature. The great similarity between SJS type II and SWS points to a single entity, a hypothesis supported by the occurrence of progressive bone dysplasia in patients with SJS type II or with SWS who survive beyond infancy.<sup>5</sup> Linkage of SJS to human chromosome 1p34-p36 has been shown in families of different ethnic backgrounds where probands presented during infancy or early childhood so a history of consanguinity is very important in such cases. Missense as well as splicing mutations of the gene encoding perlecan was described in three SJS families. Perlecan is a large heparin sulfate proteoglycan, that is found in the basement membrane of the extracellular matrix and that is essential in maintaining cartilage integrity and in regulating muscle excitability. However, in well documented families with severe neonatal SJS studied with microsatellite markers, no demonstrable linkage to chromosome 1 was found, suggesting that a second locus is responsible for the severe form of neonatal SJS. In cases of SWS, cytogenetic analyses have identified mosaicism for a supernumerary marker chromosome that was shown to be derived from chromosome 5 and to contain euchromatin. The significance of this finding for the etiology of SWS and possibly to the correlated SJS-type II is unknown. The genetic heterogeneity of the SJS can also be supported by the occurrence of sporadic reports of dominant autosomal inheritance. Recently, five new mutations in the perlecan gene (HSPG2) resulting in various forms of perlecan secreted to the extracellular matrix in reduced levels and that are likely partially functional were identified in unrelated patients with SJS. Genetically in 1995, Virjoen, Fardeaul et al. has mapped SJS locus on chromosome 1 (1p34 – p36.1) in a 8 cm interval. Even now the conclusive diagnosis is made based on genetic mapping and clinical features.<sup>2</sup> The case described in the case note had gene mutation involving the chromosome 1. In a previous study done by Fontaine et al., showed a reduced interval for SJS, of 3 cm in gene mapping. Regarding muscular activity it was Aberfeld in 1970 and Pavone in 1978, who found



▲ **Figure 1. Subluxated crystalline lens.**

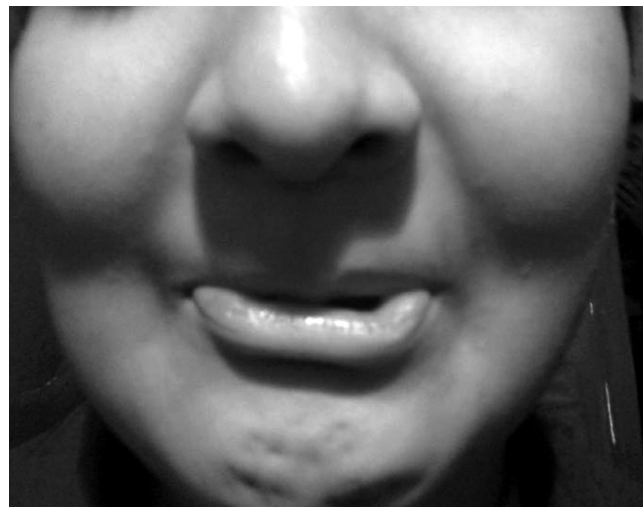
continuous electrical activity in cases of SJS type II. The typical clinical presentations in Schwartz Jampel syndrome from Ophthalmic perspective are blepharophimosis syndrome, hypertrichosis, myopia, juvenile cataract.<sup>6</sup> While till date no case of Schwartz Jampel Syndrome has been reported to have subluxated crystalline lens. Which was present in our case, it can not be conclusively told that, it can occur in cases of SJS as no such associations have been related till date, though it would be a point to note that, cases of SJS can have subluxation of the crystalline human lens, as it was present in the case described here. This can be a concurrent finding or a finding of SJS itself. This needs to be investigated in detail both genetically as well as histopathologically. Ophthalmologic management of Schwartz Jampel syndrome is indicated in cases with very narrow palpebral fissure, Juvenile cataract, and high myopia. The management includes levator muscle resection, cataract surgery with posterior chamber intraocular lens implantation, spectacles for refractive error. In the case described here spectacles correction was done, while levator resection was not indicated, though patient was advised to take muscle relaxant, which she has been taking from her childhood only. Patient is advised to follow up every 6 monthly for ocular examination.

### CONCLUSIONS

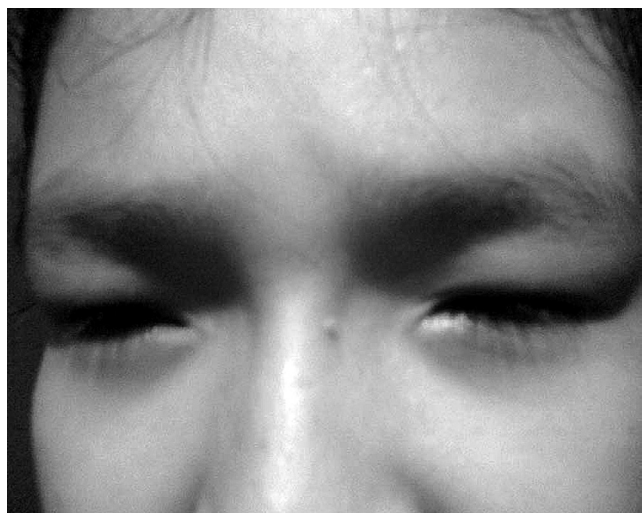
Schwartz Jampel Syndrome is a very very rare disorder, mostly affecting the eye and musculoskeletal system. To diagnose a case of SJS a multidisciplinary approach is needed. Genetic mapping, electromyography and clinical presentation are the main stay of diagnosis. As the disease has various types, Type IA, has the best prognosis both for life span as well as clinical manifestations. An Ophthalmologist always plays an important role in diagnosing a case of Schwartz Jampel syndrome as they always present with ocular signs.

### ACKNOWLEDGEMENT

I would like to acknowledge Mr. Laxman Timilsena (Ophthalmic Assistant) for helping, to make this case report. It would never have been possible to report this case without an informed consent by the care takers of the patient and the patient, I am grateful to them. Finally I would like to acknowledge various faculties from Nepal and the Professors from United Kingdom, without their effort, this case would never have been diagnosed.



▲ **Figure 2. Puckered facial appearance**



▲ **Figure 3. Congenital blepharophimosis syndrome**

## REFERENCES

1. Schwartz O, Jampel RS. Congenital blepharophimosis associated with a unique generalized myopathy. *Arch Ophthalmol* 1962;68:52-7.
2. Berardinelli. A, Ferrari. O, Lanzi. G, Lanzi Ginevra. The Schwartz Jampel Syndrome. A minireview. *Basic Appl Myol* 1997;7:363-7.
3. Di Rocco M, Stella G, Bruno C. Long-term survival in Stuve-Wiedemann syndrome: a neuro-myo-skeletal disorder with manifestations of dysautonomia. *Am J Med Genet A* 2003;118:362-8.
4. Nicole S, Ben H C, Beighton P. Localization of the Schwartz-Jampel syndrome (SJS) locus to chromosome 1p34-p36.1 by homozygosity mapping. *Hum Mol Genet* 1995;4:1633-6.
5. Umbertina C R, Rubens R, Adriana Á E, Fernando K, Lúcio G F, Maria B D R. et al. Schwartz-Jampel syndrome. *Arq Neuro-Psiquiatr* 2002 Sep; 60 (3B)
6. Viljoen D, Beighton P. Schwartz-Jampel syndrome (chondrodystrophic myotonia). *J Med Genet* 1992;29:58-62.