

Prevalence of Significant Tricuspid Regurgitation in Patients Planned for Mitral Valve Surgery in a Tertiary Center of Nepal

Sharma Parajuli S,¹ Rajbhandari N,² Panthee N,² Timshina A¹

¹Department of Cardiac Anaesthesia,

²Department of Cardiac Surgery,

Shahid Gangalal National Heart Centre (SGNHC),

Bansbari, Kathmandu, Nepal.

Corresponding Author

Nivesh Rajbhandari,

Department of Cardiac Surgery,

Shahid Gangalal National Heart Center (SGNHC),

Bansbari, Kathmandu, Nepal.

E-mail: niveshrajbhandari@gmail.com

Citation

Sharma Parajuli S, Rajbhandari N, Panthee N, Timshina A. Prevalence of Significant Tricuspid Regurgitation in Patients Planned for Mitral Valve Surgery in a Tertiary Center of Nepal. *Kathmandu Univ Med J.* 2022;80(4):431-3.

ABSTRACT

Background

Tricuspid regurgitation is frequently present in patients with mitral valve disease and most of this tricuspid regurgitation present are significant.

Objective

To find out the prevalence of tricuspid regurgitation in adult patients present in our hospital who are planned for isolated mitral valve surgery for mitral stenosis, mitral regurgitation or both. Patients with moderate and severe tricuspid regurgitation were considered as significant.

Method

This was the retrospective cross-sectional study performed at Shahid Gangalal National Heart Center of Nepal. All cardiac surgical patients scheduled for isolated mitral valve surgery during the 3 years' period from 2017 to 2020 were enrolled in the study and presence or absence of significant tricuspid regurgitation were recorded and analysed.

Result

Out of total patients 65% (663) of the cases with mitral valve pathology had significant tricuspid regurgitation. Out of the total mitral stenosis cases 70% were associated with significant tricuspid regurgitation, 62.6% of the cases of mitral regurgitation had significant tricuspid regurgitation and 64.8% of patients with combined mitral stenosis and regurgitation were associated with significant tricuspid regurgitation.

Conclusion

Significant tricuspid regurgitation is present in most of the cases with isolated mitral valve pathology. So routine tricuspid valve evaluation and repair if needed during mitral valve surgeries is recommended.

KEY WORDS

Mitral, Regurgitation, Stenosis, Tricuspid

INTRODUCTION

Tricuspid regurgitation (TR) means backflow of blood into the right atrium when leaflets of the tricuspid valve (TV) do not coapt properly during ventricular systole. The pathogenesis is intricate because of the heterogeneity of etiology, and much research indicates that TR severity is related to pulmonary artery hypertension (PAH) and impaired left ventricular ejection fraction (LVEF).^{1,2} It is estimated that tricuspid regurgitation occurs in 8-35% of patients with several studies demonstrating that severe tricuspid regurgitation is associated with higher morbidity and mortality, independent of age or biventricular systolic function.^{3,4}

Tricuspid regurgitation is frequently present in patients with mitral valve disease, and more than one-third of the patients with mitral stenosis have at least moderate TR.⁵ Mitral valve disease (usually rheumatic or ischemic) leads to mitral stenosis or regurgitation, which in turn leads to increased left atrial pressure and, if severe enough, to secondary pulmonary hypertension. Long-standing pulmonary hypertension might lead to Right Ventricular dysfunction and remodeling, which leads to tricuspid annular dilation, papillary muscle displacement, and tethering of the TV leaflets, leading to TR.^{6,7}

The aim of this study is to find out the prevalence of TR in adult patients present in our hospital who are planned for isolated mitral valve surgery for mitral stenosis, mitral regurgitation or both. Patients with moderate and severe TR were considered as significant.

METHODS

After obtaining institutional review board approval all the adult patients who underwent isolated mitral valve cardiac surgery at Shahid Gangalal National Heart Center from 2017 to 2020 were selected for this study.

This was a retrospective cross-sectional study performed at Shahid Gangalal National Heart Center (SGNHC). All cardiac surgical patients scheduled for isolated mitral valve surgery during the 3 years period, from 2017 to 2020 were enrolled in the study and their data including age, sex, body mass index, presence or absence of significant tricuspid regurgitation were recorded from the hospital record book.

The recorded data were analyzed to look for the total prevalence of significant TR and their prevalence in mitral regurgitation, mitral stenosis and combined mitral stenosis and regurgitation cases. Collected data were analysed by means of statistical software SPSS-22.

RESULTS

During the study period of 3 years, 1020 patients were included in the study. The demographic details of the

patients are shown in table 1. There was predominant female patient in this study of 676 (66.28%) compared to only 344 (33.72%) male patient. Out of total patients 663 (65%) of the cases with mitral valve pathology had significant TR and 357 (35%) of cases didn't have tricuspid valve involvement. Out of the total mitral stenosis cases 70% were associated with significant TR, 62.6% of the cases of mitral regurgitation had significant TR and 64.8% of patients with combined mitral stenosis and regurgitation were associated with significant TR as shown in table 2.

Table 1. Demographic data of the patients

Variables	Median (Range)
Age(Years)	37(2-75)
Weight (kg)	49(15-88)
BSA (m ²)	1.43(0.66-2.05)
Sex (M/F)	344/676

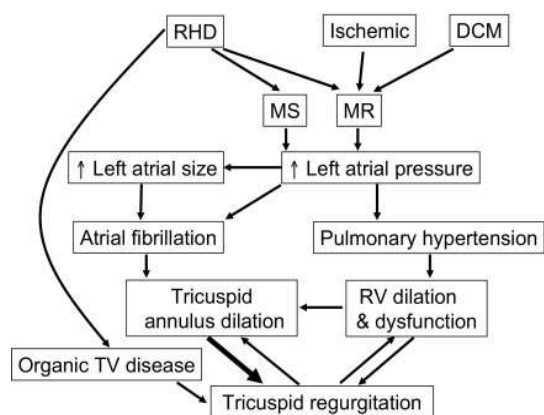
Table 2. Prevalence of TR

	Mitral Stenosis	Mitral Regurgitation	Mitral stenosis and regurgitation
No. of patients with TR n (%)	147 (70%)	267(62.6%)	249(64.8%)
No. of patients without TR n (%)	63(30%)	159(37.4)	135(35.2%)

DISCUSSION

Tricuspid regurgitation in patients with mitral valve disease is associated with poor outcome and predicts poor survival, heart failure, and reduced functional capacity. It might appear many years after surgery and might not resolve after correcting the Mitral valve lesion. Most often TR is functional, secondary to right ventricular dilation and dysfunction and tricuspid annular dilation. Mitral valve disease (usually rheumatic or ischemic) leads to mitral stenosis or regurgitation, which in turn leads to increased left atrial pressure and, if severe enough, to secondary pulmonary hypertension. Long-standing pulmonary hypertension might lead to Right Ventricular dysfunction and remodeling, which leads to tricuspid annular dilation, papillary muscle displacement, and tethering of the tricuspid valve leaflets, leading to TR (Figure 1).⁸

In patients with rheumatic valve disease, organic tricuspid valve involvement might also cause TR. Tricuspid valve leaflet thickening and restriction had been reported in about one-third of the patients with moderate or severe TR with associated rheumatic mitral valve disease.⁹ In our study almost two thirds of the patients with mitral valve pathology either stenosis, regurgitation or both were associated with significant TR with the maximum prevalence of 70% with mitral stenosis cases. Similar was the finding of the study done by Sagie et al. and Boyaci et al. who also found that mitral stenosis was associated



DCM = dilated cardiomyopathy, MR = mitral regurgitation, MS = mitral stenosis, RHD = rheumatic heart disease, RV = right ventricle, TV = tricuspid valve

Figure 1. Pathogenesis of Tricuspid Regurgitation in Mitral Valve Disease

with significant TR.^{10,11} The echocardiographic incidence of moderate to severe TR in patients with rheumatic heart disease was found to be 68% in a study done by Porter et al. which was in consistent to our study findings.⁹

The incidence of Rheumatic heart disease leading to mitral valve pathology was more common in female compared to male in our study. In a study done by Negi et al. the prevalence of Rheumatic Heart Disease was more than two-fold higher in female gender than male (71.4% vs. 29.6%, $p < 0.0001$).¹² The female preponderance could be because Rheumatic Heart Disease is an autoimmune-mediated valvular injury triggered by group A beta-hemolytic streptococcus pharyngitis. Therefore, the autoimmune response may differ between genders, leading to differences in valvular damage and severity.¹³

The major limitation of our study was that this study was a retrospective study so we couldn't retrieve the echocardiographic findings regarding presence of pulmonary artery hypertension or any underlying organic tricuspid valve pathology. So we recommend for further studies with those findings to differentiate whether the cause of TR was due to pulmonary hypertension secondary to mitral valve pathology or due to organic pathology in the tricuspid valve itself.

CONCLUSION

Significant tricuspid regurgitation is present in most of the cases with isolated mitral valve pathology out of which mitral stenosis was even more associated with significant tricuspid regurgitation. Prevalence of mitral valve pathology is more common in female patients compared to male patients. So we recommend for routine tricuspid valve evaluation and repair if needed during mitral valve surgeries.

ACKNOWLEDGEMENT

We acknowledge all the OT and ICU staff of Shahid Gangalal National Heart Centre, Kathmandu, Nepal for their valuable inputs and support in data collection.

REFERENCES

- Mascherbauer J, Kammerlander AA, Zotter-Tufaro C, Aschauer S, Duca F, Dalos D, et al. Presence of 'isolated' tricuspid regurgitation should prompt the suspicion of heart failure with preserved ejection fraction. *PLoS One*. 2017 Feb;12(2):e0171542.
- Chen L, Larsen CM, Le RJ, Connolly HM, Pislaru SV, Murphy JG, et al. The prognostic significance of tricuspid valve regurgitation in pulmonary arterial hypertension. *Clin Respir J*. 2018 Apr;12(4):1572-80.
- Antunes MJ, Barlow JB. Management of tricuspid valve regurgitation. *Heart*. 2007 Feb;93(2):271-6.
- Nath J, Foster E, Heidenreich PA. Impact of tricuspid regurgitation on long-term survival. *J Am Coll Cardiol*. 2004 Feb 4;43(3):405-9.
- Boyaci A, Gokce V, Topaloglu S, Korkmaz S, Goksel S. Outcome of significant functional tricuspid regurgitation late after mitral valve replacement for predominant rheumatic mitral stenosis. *Angiology*. 2007;58:336-42.
- Ubago JL, Figueroa A, Ochoteco A, Colman T, Duran RM, Duran CG. Analysis of the amount of tricuspid valve annular dilation required to produce functional tricuspid regurgitation. *Am J Cardiol*. 1983;52:155-8.
- Sagie A, Schwammenthal E, Padiyal LR, Vazquez de Prada JA, Weyman AE, Levine RA. Determinants of functional tricuspid regurgitation in incomplete tricuspid valve closure: Doppler color flow study of 109 patients. *J Am Coll Cardiol*. 1994;24:446-53.
- Roberts WC, Eways EA. Clinical and anatomic observations in patients having mitral valve replacement for pure mitral regurgitation and simultaneous tricuspid valve replacement. *Am J Cardiol*. 1991 Oct 15;68(10):1107-11.
- Porter A, Shapira Y, Wurzel M, Sulkes J, Vaturi M, Adler Y, et al. Tricuspid regurgitation late after mitral valve replacement: clinical and echocardiographic evaluation. *J Heart Valve Dis*. 1999 Jan;8(1):57-62.
- Sagie A, Freitas N, Chen MH, Marshall JE, Weyman AE, Levine RA. Echocardiographic assessment of mitral stenosis and its associated valvular lesions in 205 patients and lack of association with mitral valve prolapse. *J Am Soc Echocardiogr*. 1997 Mar 1;10(2):141-8.
- Boyaci A, Gokce V, Topaloglu S, Korkmaz S, Goksel S. Outcome of significant functional tricuspid regurgitation late after mitral valve replacement for predominant rheumatic mitral stenosis. *Angiology*. 2007 Jun;58(3):336-42.
- Negi PC, Kandoria A, Asotra S, Ganju NK, Merwaha R, Sharma R, et al. Gender differences in the epidemiology of Rheumatic Fever/Rheumatic heart disease (RF/RHD) patient population of hill state of northern India; 9 years prospective hospital based, HP-RHD registry. *Indian Heart J*. 2020 Nov-Dec;72(6):552-556.
- Eaton WW, Rose NR, Kalaydjian A, Pedersen MG, Mortensen PB. Epidemiology of autoimmune diseases in Denmark. *J Autoimmun*. 2007 Aug;29(1):1-9.