

Oral and Craniofacial Anomalies of Fraser Syndrome: Prosthetic Management

Amornvit P,¹ Rokaya D,² Sapkota D,³ Sanohkan S⁴

¹Maxillofacial Prosthetic Clinic, Golden Jubilee Medical Centre, Mahidol University, Salaya, Nakhon Pathom 73170, Thailand.

²Department of Clinical Dentistry, Walailak University International College of Dentistry, Walailak University, Phayathai, Bangkok 10400, Thailand.

³Department of Oral Biology, Faculty of Dentistry, University of Oslo, Oslo, Norway.

⁴Department of Prosthetic Dentistry, Faculty of Dentistry, Prince of Songkla University, Hat Yai, Songkhla 90110, Thailand.

Corresponding Author

Pokpong Amornvit
Maxillofacial Prosthetic Clinic,
Golden Jubilee Medical Centre, Mahidol University,
Salaya, Nakhon Pathom 73170, Thailand.
E-mail: pokpong_am@yahoo.com

Citation

Amornvit P, Rokaya D, Sapkota D, Sanohkan S. Oral and Craniofacial Anomalies of Fraser Syndrome: Prosthetic Management. *Kathmandu Univ Med J.* 2022;79(3):391-5.

ABSTRACT

Fraser syndrome (FS, MIM 219000) is a rare autosomal disorder characterized by systemic and oro-facial malformation, usually comprising cryptophthalmos, laryngeal malformations, syndactyly, and urogenital defects. We presented a 21-year-old FS case with partial missing teeth seeking aesthetic dental treatment. Clinical examination revealed bilateral cryptophthalmos, extensive syndactyly of hands and feet broad nose with the depressed nasal bridge, and surgically corrected bilateral cleft lip. She presented class III jaw relation and reduced the vertical height of the face. Prosthetic rehabilitation of the patient was done with upper and lower overlay dentures made from acrylic resin (VIPI BLOCK TRILUX®, VIPI Industria, Pirassununga, SP, Brazil) using computer-aided design (CAD) and computer-aided manufacturing (CAM) process. At the follow-up visit, the patient presented improved aesthetics and function. Proper management and rehabilitation of FS patients are challenging, but standard guidelines for oral health management are currently lacking. This article presents a case of Fraser syndrome presenting oral and craniofacial anomalies, and prosthetic rehabilitation was done. We also provided recommendations for the optimal oral health care for the FS patients. Functional adaptation and rehabilitation have significant roles in the various functions, survival, and quality of the life of FS patients. Integrated medical-dental care is needed in such patients with support from family members, friends, and colleagues.

KEY WORDS

Cryptophthalmos, Fraser syndrome, Overlay denture, Syndactyly

INTRODUCTION

Fraser syndrome (FS, MIM 219000) is a rare autosomal recessive disorder (ARD) which is a present systemic and craniofacial malformation, usually comprising cryptophthalmos, laryngeal malformations, syndactyly, and urogenital defects.¹⁻³ The presence of both cryptophthalmos and syndactyly in most cases results due to abnormal interactions between the mesenchyme and epithelium.⁴ The Majority of FS cases show a mutation in the FRAS 1 gene on chromosome 45 and abnormalities of ear, nose and skeletal.¹ At present, FS cases have been increasing worldwide.⁶⁻⁹ The life expectancy of FS cases was presumed to be less than one year, but some cases have been reported where the patients have survived over the age of 20 years, and 1 case has survived till the age of 96 years.¹⁰ Often, FS cases die due to central nervous system malformations, respiratory insufficiency, laryngeal stenosis or atresia, bilateral renal agenesis of obstructive uropathy. Missing teeth present esthetic and functional

problems. This article reports a case of dental problems. We presented a 21-year-old FS case with her clinical findings, oral manifestation, and prosthetic rehabilitation was done with recommendations.

CASE REPORT

A 21-year-old female patient presented to the University hospital with a chief complaint of the aesthetic problem and missing teeth. She gave a medical history that she underwent surgery to correct a cleft lip and palate when she was a child. She was not under any regular medications, and there was no family history of such abnormalities. Regarding her dental history, she had done prosthetic crowns five years back.

Clinical examination reveals bilateral cryptophthalmos, low hairline, a depressed nasal bridge with a broad

nose, and surgically corrected bilateral cleft lip (Fig. 1). Extensive syndactyly in both hands and feet was seen (Fig. 2). On examination by the physician, she had no evident neurological deficits, and her external genitalia was normal. She also presented class III jaw relations and reduced the vertical height of the face (Fig. 1).

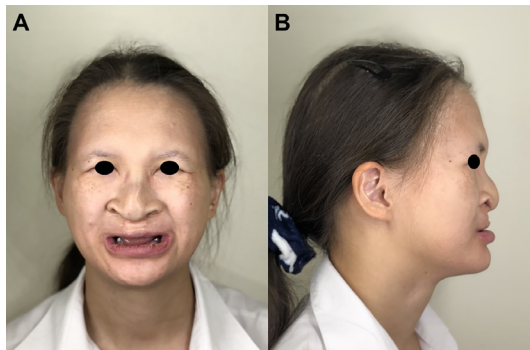


Figure 1. Photographs of the face revealing bilateral cryptophthalmos, depressed nasal bridge, broad nose, and surgically corrected bilateral cleft lip. (A) front view and (B) lateral view.

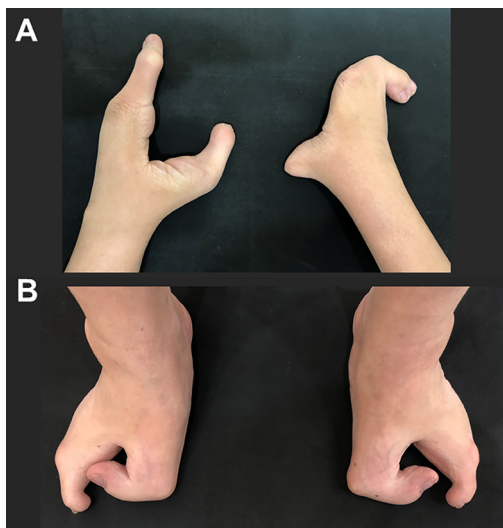


Figure 2. Syndactyly (webbing/fusion) of fingers and toes. (A) hands and (B) feet.

On intraoral examination, it showed surgically corrected cleft palate, teeth present were #11, #16, #26, #27 (Fig. 3). In the lower arch, metal crowns were present on #33, #36, #43, and #46.

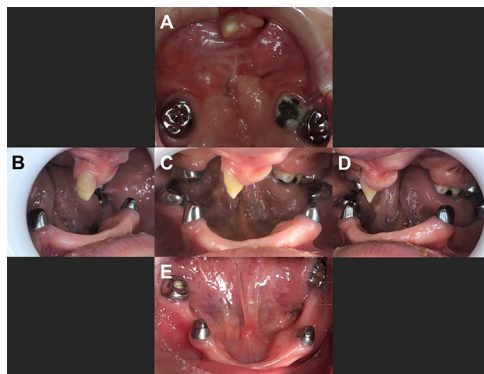


Figure 3. Intraoral photographs showing, surgically corrected cleft palate, reduced mouth opening, few teeth present, and class III jaw relation. (a) upper arch, (b) interarch right view, (c) interarch front view, (d) interarch left view, (e) lower arch.

On frontal and lateral radiographs, she presented class III jaw relation reduced mouth opening and reduced vertical height of the face (Fig. 4). On panoramic radiograph, it revealed few teeth present (#11, #16, #26, #27, #33, #36, #43, and #46), and a class III jaw relation (Fig. 5).

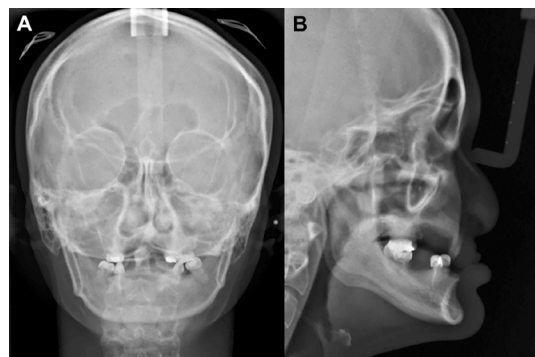


Figure 4. Extraoral radiograph showing reduced vertical height of face and class III jaw relation. (a) frontal view (PA) (b) later view.

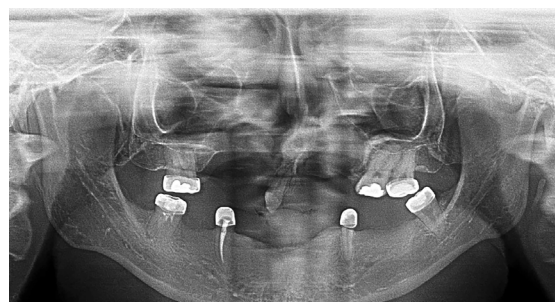


Figure 5. Panoramic radiograph showing few teeth present (#11, #16, #26, #27, #33, #36, #43, and #46).

After complete clinical examination of the patient, removable overlay dentures both in the upper and lower arch were planned. Due to microsomia, digital impressions of the upper and lower arch were made with an intraoral scanner (TRIOS 3Shape, Copenhagen, Denmark). All molars were restored with semi-anatomical zirconia-reinforced lithium silicate ceramic crowns (Celtra Press, Dentsply, Sirona, Dental GmbH, USA) with more contour on the buccal surface for the retention of the overlay denture. The upper and lower overlay dentures were made from high strength acrylic resin (VIPI BLOCK TRILUX®, VIPI Industria, Pirassununga, SP, Brazil) using computer-aided design (CAD) and computer-aided manufacturing (CAM) manufacturing (Fig. 6). The patient's esthetics was improved after the insertion of overlay dentures (Fig. 7). At the follow-up visit, the patient presented improved aesthetics and function.

DISCUSSION

FS presents distinct major and minor criteria, as shown in Table 1.¹ Diagnosis of FS requires one of the two combinations of the major and minor criteria: two major + one minor (at least) or one major + four minor (at least) criteria are required. In our female case, the patient had two major criteria (cryptophthalmos and syndactyly) + five

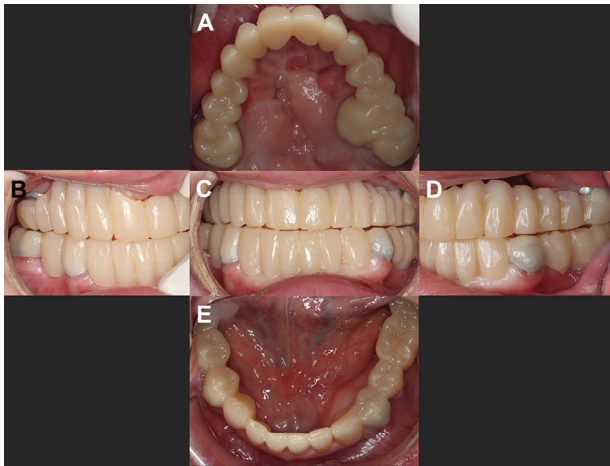


Figure 6. Intraoral photographs showing following prosthetic rehabilitation of the patient with upper and lower overlay dentures made from acrylic resin using CAD/CAM processing. (a) upper arch, (b) interarch right view, (c) interarch front view, (d) interarch left view, (3) lower arch.

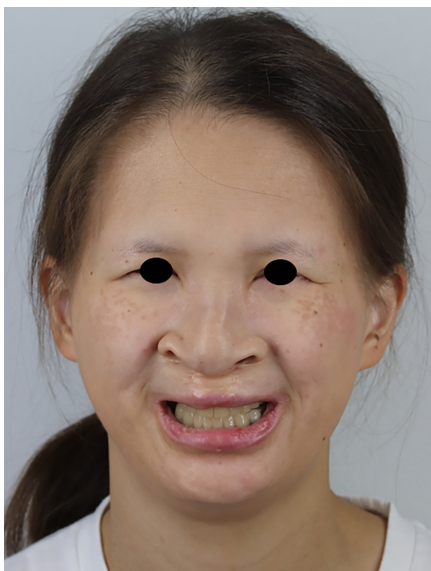


Figure 7. Patient's improved esthetic following prosthetic rehabilitation.

minor criteria (nose and ears malformations, cleft lip and palate, skeletal defects, and larynx malformation). FS can be diagnosed prenatally from ultrasound which can show renal abnormalities or agenesis and cryptophthalmos, polyhydramnios or oligohydramnios, echogenic lungs, that are pathognomonic of the FS.¹¹

In our case, implants were not planned for the replacement of teeth as soft tissue alignment was required. If used implants, bar type of attachment is preferred as only mild to moderate retention is preferred for easy removal of the dentures. Microsomia was present, which made it difficult for the impression, so we used an intraoral scanner for the digital impression.

FS presents various craniofacial anomalies. Slavotinek et al. mentioned that FS might show genetic heterogeneity and clinical variability.¹² Cutaneous syndactyly typically occurs

Table 1. Criteria for the diagnosis of Fraser syndrome.¹

Criteria for the diagnosis of Fraser Syndrome (FS)	
Major	Minor
Cryptophthalmos	Congenital nose malformation
Syndactyly	Congenital ears malformation
Abnormal genitalia	Congenital larynx malformation
Sibling with Fraser syndrome	Cleft lip with/ without cleft palate
	Skeletal defects
	Umbilical hernia
	Renal agenesis
	Mental retardation

in both the hands and the feet in FS. In most people with this feature, the skin between the middle three fingers and toes are fused. In our case, the four fingers and four toes were fused abnormally. FS patients may present ocular abnormalities, such as retinal dysplasia, microphthalmia, and Peters anomaly.² Prasun et al. reported a FS in a family having 2 FS cases with noticeable clinical heterogeneity; lethal phenotype with agenesis of both kidneys (in 1st case) and mild phenotype with normal kidneys (in 2nd case).⁷ Prenatally, FS cases mortality may be due to laryngeal atresia, pulmonary hypoplasia, and renal agenesis.¹³ Table 2 shows the multidisciplinary approach in the management of FS.

Table 2. Multidisciplinary approach in management of Fraser syndrome.

Craniofacial features	Management Aspects
Cryptophthalmos	Ophthalmologist and oculoplastic surgeon
Syndactyly	Orthopedic surgeon and plastic Surgeon
Abnormal genitalia	Gynecologist and plastic surgeon
Nose and ears defect	Otolaryngologists, plastic surgeon, and maxillofacial surgeon
Larynx defect	Otolaryngologists
Cleft lip and cleft palate	Nurses, feeding specialists, pediatrician, maxillofacial surgeon, otolaryngologists, orthodontist, prosthodontist, dentist, speech therapist, psychologists, and plastic surgeons.
Skeletal defects	Orthopedic surgeon and plastic surgeon
Umbilical hernia	General surgeon
Renal agenesis	Internal medicine and urologist
Mental retardation	Psychologists and psychiatrists
Dental anomaly	Dentist, maxillofacial surgeon, orthodontist, and prosthodontist

Cryptophthalmos: A periocular surgical management systematic approach may be planned in FS cases for cosmetic ocular rehabilitation. Saleh et al. described a multisystem periocular surgical management of FS cases to optimize visual potential.⁴ This involved the creation of fornices and reconstruction of upper and lower lids with local skin/muscle flaps.

Syndactyly: It can be corrected by surgical reconstruction by the plastic surgeons to create an anatomically normal webspace and fingers.¹⁴⁻¹⁶

Abnormal genitalia: Abnormal genitalia can be managed in the newborn requires, which requires a multidisciplinary team for the choice of sex assignment and treatment approach.^{17,18}

Nose and ears defect: Nasal ala and ear reconstruction are challenging due to 3D structures with thick and sebaceous skin. Nose defects can be repaired using reconstructive procedures ranging from skin grafts, locoregional flaps, and composite grafts for improving aesthetics and preserving the nose function.^{19,20} Various implant materials can be used for the rhinoplasty and ear reconstruction.²¹

Larynx defect: The laryngeal apparatus defects affect human communication.²² In the case of congenital inspiratory collapse, internal stabilization is necessary for laryngeal respiratory function.²³ Neuroorrhaphy, neural grafting, and electrostimulation can be done for the functioning of the paralyzed larynx.

Cleft lip and cleft palate: The clefts can be treated by a surgeon with the participation of a multidisciplinary team including orthodontists, maxillofacial surgeons, otolaryngologists, prosthodontists, speech therapists, and plastic surgeons.^{24,25} Various protocols exist for the management of unilateral cleft lip-palate, isolated cleft palate, and bilateral cleft lip-palate.²⁶⁻²⁸

Skeletal defects: FS cases often present various skeletal defects, such as craniofacial skeleton, hands, and legs.⁹ Recent management include modeling of craniofacial disorders with primary and patient-derived pluripotent stem cells.²⁹

Renal agenesis: Renal agenesis can be diagnosed during fetal ultrasonography. The most common abnormality includes vesicoureteral reflux in the contralateral kidney.³⁰ The prognosis of individuals with isolated unilateral renal agenesis is good but needs long-term follow-up due to the risk of proteinuria and/or hypertension.

Umbilical hernia: Repair of the umbilical hernia in FS infants can be postponed due to a low complication rate as the majority of the umbilical defects will be closed spontaneously within two years.³¹ But, it is advised to repair any umbilical hernias with the defect of > 1.5 cm in a child with > 2 years of age because of a low chance of spontaneous closure.³²

Mental Retardation: Depression and mental retardation are seen in over 80% of FS cases.³³ The patient may be referred to a mental health team made up of psychologists and psychiatrists as effective psychological and pharmacological treatments are available. It can be done in short-term or longer-term modes.^{34,35}

Dental anomaly: Specific dental treatments may be done according to the age and presence of specific abnormalities. Surgical treatment may be an appropriate option to correct some of the malformations associated with FS.³⁶ Restorative treatments should be done for caries. Orthodontic alignment can be done for the malaligned teeth, and prosthetic rehabilitation is done for the missing teeth. Dental implants may be done for compromised retention of the dentures. Bar type of attachments is preferred.

Proper management and rehabilitation of FS patients are challenging, but standard guidelines for oral health management are currently lacking. Functional adaptation and rehabilitation play an important role in the various functions, survival, and quality of the life of FS patients. Integrated medical-dental care is emphasized with support from family members, friends, and colleagues.

FS is a rare congenital abnormality, and well-documented major and minor criteria help in the diagnosis of FS. Although it was believed that FS causes death at typically < 1 year of age, some cases have been lived. Functional adaptation and rehabilitation with integrated medical-dental care play an important role in the various functions, survival, and quality of the life of FS patients. Prosthetic rehabilitation can be done to improve the esthetic and function of the case with FS. Support from family members, friends, and colleagues is needed.

REFERENCES

1. Thomas IT, Frias JL, Felix V, Sanchez de Leon L, Hernandez RA, Jones MC. Isolated and syndromic cryptophthalmos. *Am J Med Genet.* 1986 Sep;25(1):85-98.
2. Saal HM, Traboulsi EI, Gavaris P, Samango-Sprouse CA, Parks M. Dominant syndrome with isolated cryptophthalmos and ocular anomalies. *Am J Med Genet.* 1992 Jul 15;43(5):785-8.
3. De Jong A, Warren M, Rehrauer W, Harter J, Baraboo M, Chandra S, et al. Fraser syndrome: affected siblings born to nonconsanguineous parents and diagnosed at autopsy. *Pediatr Dev Pathol.* 2008 May-Jun;11(3):220-5.
4. Saleh GM, Hussain B, Verity DH, Collin JR. A surgical strategy for the correction of Fraser syndrome cryptophthalmos. *Ophthalmology.* 2009 Sep;116(9):1707-1712.e1.
5. Smyth I, Scambler P. The genetics of Fraser syndrome and the blebs mouse mutants. *Hum Mol Genet.* 2005 Oct 15;14 Spec No. 2:R269-74
6. Saleem AA, Siddiqui SN. Fraser Syndrome. *J Coll Physicians Surg Pak.* 2015 Oct;25 Suppl 2:S124-6.
7. Prasun P, Pradhan M, Goel H. Intrafamilial variability in Fraser syndrome. *Prenatal diagnosis.* 2007;27(8):778-782.
8. Gattuso J, Patton MA, Baraitser M. The clinical spectrum of the Fraser syndrome: report of three new cases and review. *J Med Genet.* 1987 Sep;24(9):549-55.
9. Boyd PA, Keeling JW, Lindenbaum RH. Fraser syndrome (cryptophthalmos-syndactyly syndrome): a review of eleven cases with postmortem findings. *Am J Med Genet.* 1988 Sep;31(1):159-68.
10. Impallomeni M, Subramanian D, Mahmood N, Illes J. Fraser syndrome in a 96-year-old female. *Age Ageing.* 2006 Nov;35(6):642-3.
11. De Bernardo G, Giordano M, Di Toro A, Sordino D, De Brasi D. Prenatal diagnosis of Fraser syndrome: a matter of life or death? *Ital J Pediatr.* 2015 Nov 9;41:86.

12. Slavotinek AM, Tiftt CJ. Fraser syndrome and cryptophthalmos: review of the diagnostic criteria and evidence for phenotypic modules in complex malformation syndromes. *J Med Genet.* 2002 Sep;39(9):623-33.
13. Konrad H, Merriam JC, Jones IS. Rehabilitation of a child with partial unilateral cryptophthalmos and multiple congenital anomalies. *Trans Am Ophthalmol Soc.* 1995;93:219-244.
14. Braun TL, Trost JG, Pederson WC. Syndactyly Release. *Semin Plast Surg.* 2016;30(4):162-70.
15. Yildirim C, Sentürk S, Keklikçi K, Akmaz I. Correction of syndactyly using a dorsal separated V-Y advancement flap and a volar triangular flap in adults. *Ann Plast Surg.* 2011 Oct;67(4):357-63.
16. Jordan D, Hindocha S, Dhital M, Saleh M, Khan W. The epidemiology, genetics and future management of syndactyly. *Open Orthop J.* 2012;6:14-27.
17. Sultan C, Paris F, Jeandel C, Lumbroso S, Galifer RB. Ambiguous genitalia in the newborn. *Semin Reprod Med.* 2002 Aug;20(3):181-8.
18. Sowande OA, Adejuyigbe O. Management of ambiguous genitalia in Ile Ife, Nigeria: challenges and outcome. *Afr J Paediatr Surg.* 2009;6(1):14-18.
19. Chen C, Patel R, Chi J. Comprehensive Algorithm for Nasal Ala Reconstruction: Utility of the Auricular Composite Graft. *Surg J (N Y).* 2018;4(2):e55-e61.
20. Ortins-Pina A, Teixeira AI, Sanches M, Gouveia AI, Filipe PL, Silva JM. Nasal Ala Reconstruction: Surgical Conundrum. *J Cutan Aesthet Surg.* 2017 Jan-Mar;10(1):55-8.
21. Berghaus A. Implants for reconstructive surgery of the nose and ears. *GMS Curr Top Otorhinolaryngol Head Neck Surg.* 2007;6:Doc06-Doc06.
22. Tabler JM, Rigney MM, Berman GJ, Gopalakrishnan S, Heude E, Al-Lami HA, et al. Cilia-mediated Hedgehog signaling controls form and function in the mammalian larynx. *Elife.* 2017 Feb 13;6:e19153.
23. Müller A. Reconstructive procedures for impaired upper airway function: laryngeal respiration. *GMS Curr Top Otorhinolaryngol Head Neck Surg.* 2005;4:Doc09-Doc09.
24. Nahai FR, Williams JK, Burstein FD, Martin J, Thomas J. The Management of Cleft Lip and Palate: Pathways for Treatment and Longitudinal Assessment. *Semin Plast Surg.* 2005;19(4):275-85.
25. Habel A, Sell D, Mars M. Management of cleft lip and palate. *Arch Dis Child.* 1996;74(4):360-66.
26. Schnitt DE, Agir H, David DJ. From birth to maturity: a group of patients who have completed their protocol management. Part I. Unilateral cleft lip and palate. *Plast Reconstr Surg.* 2004;113(3):805-17.
27. David DJ, Anderson PJ, Schnitt DE, Nugent MA, Sells R. From birth to maturity: a group of patients who have completed their protocol management. Part II. Isolated cleft palate. *Plast Reconstr Surg.* 2006 Feb;117(2):515-26.
28. David DJ, Smith I, Nugent M, Richards C, Anderson PJ. From birth to maturity: a group of patients who have completed their protocol management. Part III. Bilateral cleft lip-cleft palate. *Plast Reconstr Surg.* 2011 Aug;128(2):475-84.
29. Neben CL, Roberts RR, Dipple KM, Merrill AE, Klein OD. Modeling craniofacial and skeletal congenital birth defects to advance therapies. *Hum Mol Genet.* 2016 Oct 1;25(R2):R86-R93.
30. Robson WL, Leung AK, Rogers RC. Unilateral renal agenesis. *Adv Pediatr.* 1995;42:575-92.
31. Heifetz CJ, Bilsel ZT, Gaus WW. Observations on the disappearance of umbilical hernias of infancy and childhood. *Surg Gynecol Obstet.* 1963;116:469-73.
32. Haller JA Jr, Morgan WW Jr, White JJ, Stumbaugh S. Repair of umbilical hernias in childhood to prevent adult incarceration. *Am Surg.* 1971 Apr;37(4):245-6.
33. Ford GR, Irving RM, Jones NS, Bailey CM. ENT manifestations of Fraser syndrome. *J Laryngol Otol.* 1992 Jan;106(1):1-4.
34. Janowsky DS, Davis JM. Diagnosis and treatment of depression in patients with mental retardation. *Curr Psychiatry Rep.* 2005;7(6):421-8.
35. Bouras N, Jacobson J. Mental health care for people with mental retardation: a global perspective. *World Psychiatry.* 2002;1(3):162-5.