

# Toothbrush, an Unusual Foreign Body

Bhattarai A, Adhikari D, Paudyal N, Giri P, Khadka A, Devkota Y

Department of General and Laparoscopic Surgery

Nobel Medical College Teaching Hospital,

Kanchanbari, Morang, Biratnagar.

## Corresponding Author

Nabin Paudyal

Department of General and Laparoscopic Surgery

Nobel Medical College Teaching Hospital,

Kanchanbari, Morang, Biratnagar.

E-mail: Paudyal.nabin@gmail.com

## Citation

Bhattarai A, Adhikari D, Paudyal N, Giri P, Khadka A, Devkota Y. Toothbrush, an Unusual Foreign Body. *Kathmandu Univ Med J.* 2021;76(4):522-4.

## ABSTRACT

Accidental consumption of foreign body is a common presenting complain among patients especially in young age group. Majority of patients can be discharged safely after reassurance while a fraction of patient requires observation and further management. Here we report a case of a 35-year-old gentleman who presented to the out-patient department of our hospital in June 2021 for accidental ingestion of toothbrush. After detailed history and physical examination upper gastrointestinal endoscopy was planned for the patient. Failed endoscopic removal was considered the indication for surgery. A supraumbilical midline incision was used to remove the toothbrush. Following the surgical removal, he was managed conservatively and was discharged without significant complications. We describe this case in detail in addition to reviewing the pertinent literature.

## KEY WORDS

*Endoscopy, Foreign body, Surgery*

## INTRODUCTION

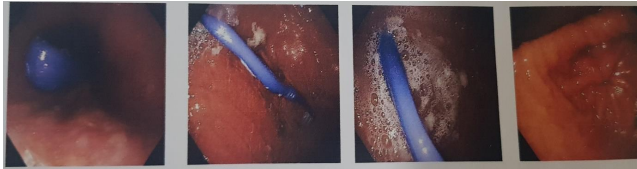
Accidental consumption of foreign body is a common presenting complain among patients especially in young age group.<sup>1</sup> Majority of the patients that arrive to the emergency department or outpatient department can be discharged safely after reassurance.<sup>2</sup> A small fraction of the patient is detained for observation and further management.<sup>2</sup> However, when the ingested foreign body is long and slender like toothbrush, it will rarely pass through the bowel loops and require endoscopic or open surgical removal.<sup>3</sup> Here we describe an asymptomatic adult male presenting to out-patient clinic with a history of unintentional toothbrush ingestion.

## CASE REPORT

A 35 year old gentleman presented to the out-patient department of our hospital in June 2021 for accidental ingestion of toothbrush. The patient was in his state of usual health when he ingested a toothbrush while brushing his teeth. Patient mentioned that the toothbrush slipped from his hand while attempting to clean base of the tongue

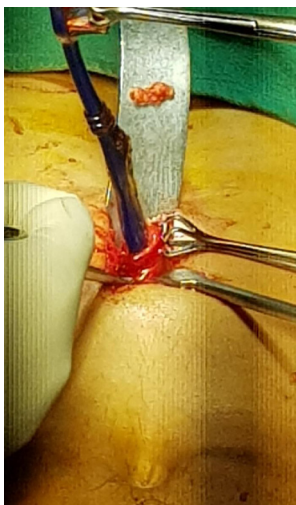
using the bristles. As per the patient, he had been brushing for 15 minutes before the accident happened. Patient described of having a transient retrosternal pain for which he took few sips of water. He however had no dysphagia, shortness of breath, vomiting and upper GI bleeding immediately after ingestion. He had no neurological and mental illnesses.

Following the incident, the patient visited to a nearby medical store. He was referred to our center for further management. The patient then presented to the outpatient department of general surgery. Upon arrival, pertinent medical history was taken. Detailed physical examination was done. All his vitals and physical examination findings were normal at the time of presentation. Based on preliminary examination UGI endoscopy was planned for the patient. With help from an endoscopist, an effort was made to remove the brush. Failed attempt to remove such a huge foreign body via endoscope was considered as an indication for open surgery. The picture showing toothbrush in-situ is shown in figure 1.

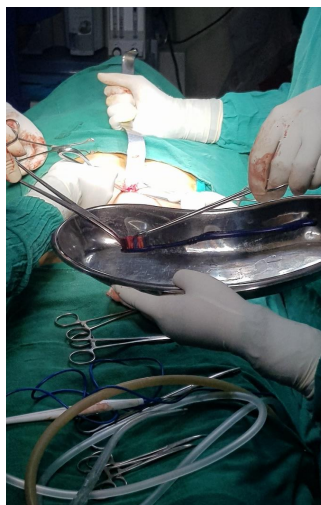


**Figure 1.** Endoscopic view of toothbrush in the stomach

An emergency surgery to remove the toothbrush was planned and after all pre-operative preparation patient was operated within six hours from the time of presentation. Operation was done using general anesthesia. A supraumbilical midline incision measuring six cm was given. Standard surgical technique was used to enter into the peritoneum dissecting across the anterior abdominal wall after which the pyloric antrum was identified. A three cm straight incision was given along the anterior border of the pylorus. Toothbrush was found to be lodged within the lumen at the pyloric antrum. Using forceps, the toothbrush was removed which measured 15 cm in length. After removal, the gastric lumen was examined for any injury and no active hemostasis was noted. Incised segment of the bowel wall was tied using 3-0 vicryl suture. Abdomen wall was closed in layers after ensuring adequate hemostasis. The process described above is shown in figures 2 and 3.



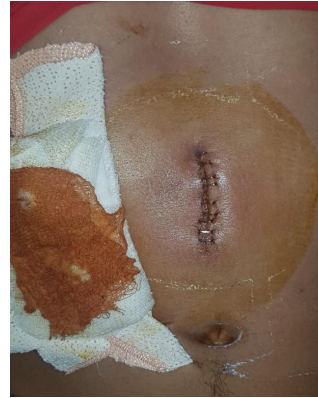**Figure 2.** Removal of toothbrush using supraumbilical incision.



**Figure 3.** Complete removal of the toothbrush.

Post-operatively patient had an uneventful recovery. He was kept nil per oral overnight and was allowed sips of water next morning. The patient resumed his normal bowel function two days after the surgery. The incision site was examined on the third day which is shown in figure 4. The patient was discharged on the third day of operation.

The patient visited to the OPD for follow up two weeks after the date of surgery. His skin staplers were removed. The patient has been performing his works of daily living normally and has no issues currently.



**Figure 4.** Fully healed incision site prior to removal of stapler.

## DISCUSSION

Foreign body ingestion is a common presenting complaint of patients in outpatient and emergency department. Many factors are associated with the ingestion of these indigestible bodies. Especially in children, ranging from age groups six months to three years, who have a curious nature, swallowing occurs mostly due to carelessness.<sup>3,4</sup> In adults underlying mental illness, poor vision, substance abuse, dentures and rapid eating are common etiologic agents responsible for foreign body ingestion.<sup>5-7</sup> In our case, the patient did not have any underlying mental illness and had no history of substance abuse. The ingestion was due to carelessness during brushing.

Approximately 80-90% of the ingested foreign body pass through the gastrointestinal tract spontaneously. Only 10-20% require endoscopic removal while < 1% require open surgery. Possibilities of complications like impaction, obstruction and perforation can be seen with foreign body ingestion.<sup>4</sup> Fulminant sepsis is the major cause of death in foreign body ingestion.<sup>5,8,9</sup> In addition, perforation of the gastrointestinal tract due to toothbrush may involve adjacent structures producing fistulae to another organ.<sup>5-7,10,11</sup> In a review of 31 cases of toothbrush ingestion, no episodes of spontaneous passage were reported.<sup>12</sup> Therefore, urgent efforts should be made to remove the ingested foreign bodies if they cannot pass through the gastrointestinal tract spontaneously.

An initial extraction strategy to consider is endoscopy by a skilled endoscopist/gastroenterologist. Endoscopy offers different advantages like being minimally invasive, freedom from burden of incisional surgery and early resuming of activities of daily living. The first successful performance of this procedure was reported by Ertan et al.<sup>13</sup> Therefore, an opinion of an experienced endoscopist is necessary for non-operative removal than going with surgical removal.<sup>2</sup> Equally, however, it has also been seen in number of studies regarding failure in endoscopic removal of the toothbrush that have resulted in esophageal perforation.<sup>14,15</sup> Factors like geometric shape of toothbrush can make it difficult to orientate the long axis of the brush with the gastroesophageal junction. In addition, if the

object is longer than 6-10 cm, surgical removal of them should be considered because object can have difficulty in passing the duodenal sweep.<sup>16</sup> The toothbrush in our case measured 15 cm and impacted within the pyloric lumen. Hence, surgical intervention was planned for the definitive management in our case.

Although the laparoscopic removal of the foreign bodies from the stomach has been reported in number of cases, laparotomy has traditionally been employed.<sup>11</sup> In addition, in many cases where endoscopic removal of toothbrush

failed, laparotomy has been performed with a great success.<sup>17</sup>

An ingested toothbrush will not pass spontaneously and has a significant risk of causing pressure necrosis or perforation which can result in life-threatening abdominal sepsis. Unlike smaller foreign bodies within the stomach, a trial of conservative therapy should not be employed. The best course of action is early endoscopy by a skilled operator. If this is unsuccessful either laparotomy or laparoscopy can be performed depending on local expertise.

## REFERENCES

- Klancnik M, Grgec M, Perkovic N, Ivanisevic P, Poljak NK. A Foreign Body (Toothbrush) in the Esophagus of a Patient with Hiatal Hernia. *Case Rep Gastroenterol*. 2017;11(1):184-9.
- Mughal M. Accidental ingestion of a toothbrush! *Arch Emerg Med*. 1986;3(2):119-23.
- Jamal K, Shaunak S, Kalsi S, Nehra D. Successful laparoscopic removal of an ingested toothbrush. *J Surg Tech Case Rep*. 2013;5(2):99-102.
- Chao HH, Chao TC. Perforation of the duodenum by an ingested toothbrush. *World J Gastroenterol*. 2008;14(27):4410-2.
- Velitchkov NG, Grigorov GI, Losanoff JE, Kjossev KT. Ingested foreign bodies of the gastrointestinal tract: retrospective analysis of 542 cases. *World J Surg*. 1996;20(8):1001-5.
- Webb WA. Management of foreign bodies of the upper gastrointestinal tract: update. *Gastrointest Endosc*. 1995;41(1):39-51.
- Mosca S, Manes G, Martino R, Amirano L, Bottino V, Bove A, et al. Endoscopic management of foreign bodies in the upper gastrointestinal tract: report on a series of 414 adult patients. *Endoscopy*. 2001;33(8):692-6.
- Budnick LD. Toothpick-related injuries in the United States, 1979 through 1982. *JAMA*. 1984;252(6):796-7.
- Bee DM, Citron M, Vannix RS, Gunnell JC, Bridi G, Juston G, Jr., et al. Delayed death from ingestion of a toothpick. *N Engl J Med*. 1989;320(10):673.
- Ginsberg GG. Management of ingested foreign objects and food bolus impactions. *Gastrointest Endosc*. 1995;41(1):33-8.
- Selivanov V, Sheldon GF, Cello JP, Crass RA. Management of foreign body ingestion. *Ann Surg*. 1984;199(2):187-91.
- Kirk AD, Bowers BA, Moylan JA, Meyers WC. Toothbrush swallowing. *Arch Surg*. 1988;123(3):382-4.
- Ertan A, Kedia SM, Agrawal NM, Akdamar K. Endoscopic removal of a toothbrush. *Gastrointest Endosc*. 1983;29(2):144-5.
- Conway WC, Sugawa C, Ono H, Lucas CE. Upper GI foreign body: an adult urban emergency hospital experience. *Surg Endosc*. 2007;21(3):455-60.
- Weiland ST, Schurr MJ. Conservative management of ingested foreign bodies. *J Gastrointest Surg*. 2002;6(3):496-500.
- Eisen GM, Baron TH, Dominitz JA, Faigel DO, Goldstein JL, Johanson JF, et al. Guideline for the management of ingested foreign bodies. *Gastrointest Endosc*. 2002;55(7):802-6.
- Ayantunde AA, Oke T. A review of gastrointestinal foreign bodies. *Int J Clin Pract*. 2006;60(6):735-9.