

Peak Systolic Velocity in Middle Cerebral Artery in Patients with Severe Traumatic Brain Injury as an Indicator of Detrimental Rise in Intracranial Pressure

Shrestha B,¹ Lakshmipathy G²

¹Department of Surgery, Neurosurgery Unit
Dhulikhel Hospital, Kathmandu University Hospital,
Kathmandu University School of Medical Sciences,
Dhulikhel, Kavrepalanchowk, Nepal.

²Department of Neurosurgery
Upendra Devkota Memorial National Institute
of Neurological and Allied Sciences,
Bansbari, Kathmandu, Nepal.

Corresponding Author

Bibhusan Shrestha
Department of Surgery, Neurosurgery Unit
Dhulikhel Hospital, Kathmandu University Hospital,
Kathmandu University School of Medical Sciences,
Dhulikhel, Kavrepalanchowk, Nepal.
E-mail: sbibhusan@hotmail.com

Citation

Shrestha B, Lakshmipathy G. Peak Systolic Velocity in Middle Cerebral Artery in Patients with Severe Traumatic Brain Injury as an Indicator of Detrimental Rise in Intracranial Pressure. *Kathmandu Univ Med J.* 2021;76(4):481-5.

ABSTRACT

Background

Intracranial pressure (ICP) is the major concern for neurosurgeons while treating patients with severe traumatic brain injury, as any troublesome escalation in intracranial pressure heralds feared complications leading to definite morbidity or even mortality.

Objective

This study focuses on analyzing the correlation between peak systolic velocity in middle cerebral artery derived from transcranial doppler ultrasonographic spectral analysis and intracranial pressure values derived from invasive intracranial pressure monitoring system in a patient with severe traumatic brain injury.

Method

A prospective observational study was performed using a convenience sample technique including all adult patients with severe traumatic brain injury who had invasive intracranial monitors placed as part of their clinical care. Transcranial doppler ultrasonography was performed with a 2 MHz linear probe of ACUSON X300 ultrasound system while simultaneous intracranial pressure readings were obtained directly from invasive intracranial pressure monitoring. The association between peak systolic velocity in the middle cerebral artery and invasive intracranial pressure was assessed with Pearson's correlation coefficient.

Result

One hundred one transcranial doppler ultrasound spectral analysis was performed on 26 individual patients. The mean age of the population involved in this study is 43.57 years \pm S.D. 19.95 (range 18-78 years), with male preponderance in a ratio of 5.5:1. Pearson's correlation coefficient of peak systolic velocity in middle cerebral artery and intracranial pressure was 0.715 ($p < 0.000$) demonstrating a significant positive correlation. With further evaluation of area under curve characteristics, peak systolic velocity in middle cerebral artery of 39.6 cm/s yielded the most favorable balance of test characteristics to diagnose elevation of intracranial pressure, with a resulting sensitivity of 82.1% and specificity of 84.4%.

Conclusion

Peak systolic velocity in middle cerebral artery can be explored further as a dependable screening tool to evaluate intracranial pressure among patients with severe traumatic brain injury in settings with unavailability of invasive intracranial pressure monitoring facilities.

KEY WORDS

Intracranial pressure, Peak systolic velocity, Screening, Trauma

INTRODUCTION

Among various techniques used to monitor intracranial pressure, transcranial doppler analysis have come up as a probable alternative to ventriculostomy.¹ However, tangible evidence to establish their credibility as an alternative to invasive techniques is yet missing.² Spectral doppler ultrasound velocimetry involves a systematic analysis of the spectrum of frequencies that constitute the doppler signals. Various works of literature utilized these noninvasive tools for investigating cerebrovascular hemodynamics.^{3,4} A correlation between pulsatility index, resistivity index, and intracranial pressure have been noted from various experimental studies on head injury and hydrocephalus.^{5,6} However, very little have been done to search for the impact of inherent parameters constituting pulsatility index or resistivity index in regards to intracranial pressure.

METHODS

We performed a prospective observational study among patients over 18 years who were admitted to neurosurgical intensive care unit with invasive intracranial monitoring placed as part of their clinical care in accord to British Trauma Foundation (BTF) guideline.⁷ Sample size was calculated using G*Power ver. 3.1.9.4. Correlational bivariate normal model statistics test and a priori type power analysis tool were considered to calculate the sample size. With input parameters as alpha error of 0.05, hypothetical effect size of 0.3, and power of 0.8, the sample size was derived. Patients were enrolled between May 1, 2017, to Feb 29, 2020, as a convenience sample, based on availability to treating surgeons. Informed consent was obtained from patients' family members before enrollment. With an intention to treat the primary condition, patients were only observed while they were undergoing their treatment. Hence both operated (i.e., decompressive hemicraniectomy status) and non-operated cases were considered. Exclusion criteria included patients less than 18 years of age or patients on whom temporal insonation of middle cerebral artery couldn't be performed.

Measurements were obtained when possible within 1st 72 hours of intracranial pressure monitoring. Doppler study of bilateral middle cerebral artery was performed on ACUSON X300 machine with a 2 MHz linear probe using a standard technique described in the literature.¹ For each subject, the principal investigator performed a doppler spectral analysis on middle cerebral artery through insonation of the artery via the trans-temporal window. The angle and position of probe through the exposure area was adjusted in order to enable the highest quality signal from middle cerebral artery. Bilateral tracings of flow velocity were recorded, and necessary calculations were made from inbuilt program to obtain the peak systolic velocity. Continuous intracranial pressure measurements were also recorded electronically

during the period of transcranial doppler spectral analysis. The intracranial pressure measurements were averaged to yield a mean intracranial pressure for each subject during the time required to perform doppler ultrasonographic spectral analysis for both middle cerebral arteries. Single reading on each side was taken on day 1 and day 3 in nearly all patients included, accounting for total of 4 readings per patient in average, except for 2 patients in whom repeat scans could not be performed. Data acquired were analyzed with Statistical Package for the Social Sciences (Version 16, Chicago, IL). The Pearson's correlation coefficient with a two-tailed p-value was used to assess for an association between the two measurements. A receiver operator characteristic (ROC) curve was constructed to determine the optimal peak systolic velocity in middle cerebral artery to detect intracranial pressure > 15 cm of H₂O. This study was approved by the institutional review board of Upendra Devkota Memorial National Institute of Neurological and Allied Sciences, Bansbari.

RESULTS

One hundred one transcranial doppler ultrasonographic spectral analysis were performed on 26 patients, 22 male and 4 females, with an average age of 43.57 years \pm S.D. 19.95 (range 18–78 years). Among those considered, 92.3% of them had an alleged history of road traffic accidents resulting in traumatic brain injury, and the remaining 7.7% were cases with head injury due to fall. All patients considered had Glasgow coma scale (GCS) less than eight at presentation. Mean duration between event of injury and time to presentation was noted to be 5.27 hours \pm S.D. 3.8 (range 0.5–16 hours). Mean time to first doppler spectral analysis from event of injury was found to be 9.30 hours \pm S.D. 3.78 (range 4.5–20 hours). Pearson's correlation coefficient between intracranial pressure and peak systolic velocity in middle cerebral artery was noted to be 0.715 ($p < 0.000$) (Fig 1).

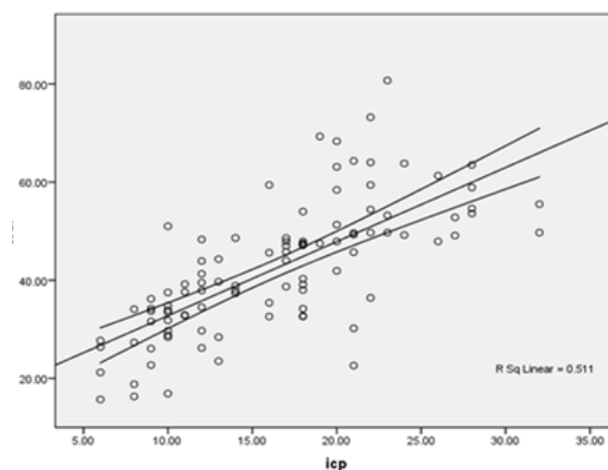


Figure 1. Scatter plot showing the correlation between peak systolic velocity in middle cerebral artery and invasive intracranial pressure readings.

Mean intracranial pressure among the study population is noted to be 16.45 cm of H₂O \pm S.D. 6.29 (range 6-32 cm of H₂O). Among all readings, 57 readings were noted to be during period of raised intracranial pressure i.e., values greater than 15 cm of H₂O. Rest cases were deemed negative for assessment to attain cut off value for peak systolic velocity in middle cerebral artery to recognize state of raised intracranial pressure. Mean of intracranial pressures considered for obtaining cutoff value was 21 cm of H₂O \pm S.D. 4.03 (range 16-32 cm of H₂O). Further, we created a receiver operative characteristics curve (Fig. 2). The receiver operative characteristic curve demonstrated an area under the curve of 0.893 (95% CI=0.83-0.96). With the evaluation of area under curve characteristics, peak systolic velocity in middle cerebral artery of 39.6 cm/s yielded the most favorable balance of test characteristics, with a resulting sensitivity of 82.1% and specificity of 84.4%.

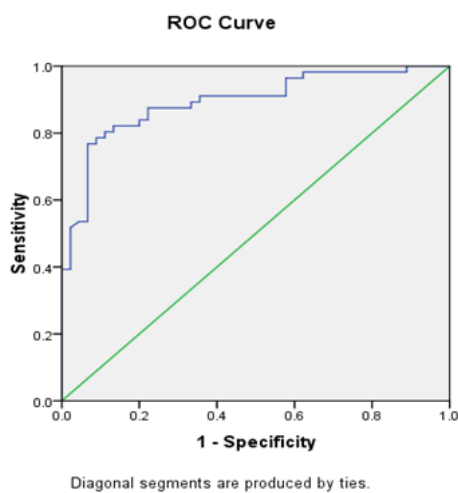


Figure 2. ROC curve created between peak systolic velocity in middle cerebral artery and raised intracranial pressure readings.

DISCUSSION

Considering scenario of traumatic brain injury, presence of altered autoregulation in cerebral blood flow causes significant hemodynamic changes in the homeostatic milieu of brain.⁸ Hence, role of maintenance of normal intracranial pressure to serve adequate blood flow for minimal metabolic requirement for repair is of paramount importance.⁹ Mamarou et al. in his paper mentioned that in early stages of injury, there are two vascular mechanisms that are responsible for increase in intracranial pressure.¹⁰ Increased intracranial pressure results either from vascular engorgement owing to impaired autoregulation or by brain edema.¹⁰ With this background, it can be expected that apart from the share of pressure exerted by brain edema, alteration in cerebral blood flow during period of altered autoregulation directly affects measured intracranial pressure.

Following recommendation of British trauma foundation guidelines 2016 and looking into the conclusion of

RESCUEicp trial it is known that in cases of severe traumatic brain injury, intracranial pressure monitoring and management plays important role.^{7,11} Among various ways as yet, an invasive intraventricular catheter to monitor intracranial pressure is considered the gold standard.¹² But it is not without its problems. Various non-invasive techniques have been tried to provide an alternative method to overcome such complications.¹² Among all methods, various works of literature have supported transcranial doppler ultrasonography of major cerebral vessels as a good alternative to invasive techniques.^{13,14} With an upsurge in use of ultrasonography, thought of using the instrument as management tool for severe head injury, in an emergency or a rural based setting, is not unimaginable.¹⁵ As transcranial doppler ultrasonography is reproducible, easy to perform, and doesn't have steep learning curve with acceptable intra- and inter-observer variation, it is a good tool to be utilized further to help in management of patients with severe traumatic head injury in our settings as well.¹⁶

To substantiate these findings in our study, we considered 26 patients, 22 male and 4 females, with an average age of 43.57 years \pm S.D. 19.95 (range 18-78 years). Kafle et al. in his paper gave insight about demographic distribution concerning recent situation of traumatic brain injury in Eastern Nepal which is concordant with our study population as well.¹⁷ Similar demographic patterns were also noted in study by Khadka et al. from one of the tertiary centers for neurosurgical service in Kathmandu.¹⁸ Considering the statistical relationship between peak systolic velocity in middle cerebral artery acquired through transcranial doppler spectral analysis and invasive intracranial pressure, it was noted that two parameters have moderate positive correlation ($r=0.715$ ($p < 0.000$)) (Fig. 1). Similar to our study, Goodman et al. in his prospective study conducted at a level 1 trauma center at Cincinnati, Ohio including 135 patients also concluded transcranial doppler ultrasonography spectral analysis as a potential tool to estimate and follow intracranial pressure among patients with severe traumatic brain injury. Among those included as his sample population, there were diversity among the grades of severity of traumatic brain injury. Further his team also noted that there was not much of a difference among various other spectral analysis parameters among different grades of severity of brain injury. Notably, middle cerebral artery peak systolic velocity and carotid flow velocity performed well and correlated with the intracranial pressure among these patients.¹⁹

As noted by Bishop et al. from London in 1986 in his landmark paper the resting middle cerebral artery peak systolic velocity has wide normal range from 36 cm/sec to 140 cm/sec and also that any change in middle cerebral artery peak systolic velocity reliably correlate with change in cerebral blood flow.²⁰ Similar to the noted conclusion, in our study also all measured middle cerebral artery peak

systolic velocity came to lie within this proposed normal range irrespective of state of intracranial pressure. As in our study, patients were enrolled as intention to treat basis, all the recordings were taken after required treatment procedures. So, extremes of state where intracranial pressure is extremely high were not much of avail for the study. This might be the reason for the normalization of the velocity within corresponding middle cerebral artery.

Considering the calculation to attain cut off value to recognize state of raised intracranial pressure, peak systolic velocity in middle cerebral artery of 39.6 cm/s showed most favorable balance of test characteristics, with a resulting sensitivity of 82.1% and specificity of 84.4%. This parameter also happens to lie within normal considered flow velocity of blood in middle cerebral artery. However, many studies in likes of Gupta et al. from India when studied patients with idiopathic intracranial hypertension, with mean ICP of 30.7 ± 46.8 cm H₂O, noted that the baseline blood flow velocities in the middle cerebral artery were directly proportional to increased intracranial pressure.¹⁵ Similar, idea in relation to peak systolic velocity in middle cerebral artery and intracranial pressure was also stated by Wu et al. when they studied peak systolic velocity measurements with transcranial doppler ultrasound as a predictor of stroke among the general population in China.²¹ The difference in results between both of our study might have been due to variation in sample population characteristics especially mean intracranial pressure considered which is low in our study compared to theirs and also the operative treatment i.e., decompressive hemicraniectomy received by the patients in our study beforehand, altering CSF dynamics. Also point to be noted in study by Wu et al. was

that in this study they studied blood flow velocity in setting of normal intracranial pressure with acute development of intravascular stenosis.²¹ However, it is yet unknown in which extreme of raised intracranial pressure, arterial diameter narrows down and by what extent such that changes in blood flow velocity is evident.

The study is performed at a single center by a single investigator. Owing to the limited patient flow of such grave injury to the single-center, result of this study is limited by its small sample size. Further, biases that can influence the result such as hematocrit, arterial blood gas parameters were not considered in this study as it would surmount to additional expenses to the patient, if done only for research purpose. As patients were only observed while they were undergoing their treatment for best possible outcome, use of drugs, surgical status and their effect on the results of the study were also not considered.

A multicenter study with a much larger study population with severe traumatic brain injury should be considered to increase our understanding of the matter.

CONCLUSION

It is learned that there exists a noteworthy positive association among peak systolic velocity in middle cerebral artery and invasive intracranial pressure measured concurrently ($r=0.715$ ($p < 0.000$)). Hence, doppler spectral analysis can be explored further as a screening tool to evaluate elevated intracranial pressure in the emergency setting as and when required.

REFERENCES

- Purkayastha S, Sorond F. Transcranial Doppler ultrasound: technique and application. *Semin Neurol.* 2012;32(4):411-20. doi:10.1055/s-0032-1331812
- Rasulo FA, Bertuetti R, Robba C, Lusenti F, Cantoni A, Bernini M, et al. The accuracy of transcranial Doppler in excluding intracranial hypertension following acute brain injury: a multicenter prospective pilot study. *Critical care.* 2017 Dec;21(1):1-8. doi:10.1186/s13054-017-1632-2
- Archer LN, Evans DH, Paton JY, Levene MI. Controlled hypercapnia and neonatal cerebral artery doppler ultrasound waveform. *Pediatr Res.* 1986; 20:218-21.
- Lindgaard KF. Indices of pulsatility. In: Newell OW, Aaslid R, eds. *Transcranial Doppler.* New York: Raven Press, 1982:67-82
- Seibert JJ, McCowan TC, Chaddock WM, Adamez JR, Glasier C, Williamson SL, et al. Duplex pulsed Doppler US versus intracranial pressure in the neonate: clinical and experimental studies. *Radiology.* 1989 Apr;171(1):155-9.
- Goh D, Minns RA, Pye SO. Transcranial Doppler (TCD) ultrasound as a noninvasive means of monitoring cerebrohaemodynamic change in hydrocephalus. *Eur J Pediatr Surg.* 1991; 1: 14-17
- Carney N, Totten AM, O'Reilly C, Ullman JS, Hawryluk GW, Bell MJ, et al. Guidelines for the Management of Severe Traumatic Brain Injury, Fourth Edition. *Neurosurgery.* 2017 Jan 1;80(1):6-15. doi: 10.1227/NEU.0000000000001432. PMID: 27654000.
- Armstead WM. Cerebral Blood Flow Autoregulation and Dysautoregulation. *Anesthesiol Clin.* 2016 Sep;34(3):465-77. doi: 10.1016/j.anclin.2016.04.002. PMID: 27521192; PMCID: PMC4988341.
- Rangel-Castilla L, Gopinath S, Robertson CS. Management of intracranial hypertension. *Neurol Clin.* 2008 May;26(2):521-41, x. doi: 10.1016/j.ncl.2008.02.003. Erratum in: *Neurol Clin.* 2008 Aug;26(3): xvii. Rangel-Castilla, Leonardo [corrected to Rangel-Castilla, Leonardo]. PMID: 18514825; PMCID: PMC2452989.
- Marmarou A. Increased intracranial pressure in head injury and influence of blood volume. *Journal of neurotrauma.* 1992 Mar 1;9:S327-32.
- Chester AN, Purdie GL, Dennett ER, Parker AJ. A survey of neurosurgical management and prognostication of traumatic brain injury following the RESCUEicp trial. *British journal of neurosurgery.* 2021 May 4;35(3):329-33.
- Raboeel PH, Bartek J Jr, Andresen M, Bellander BM, Romner B. Intracranial Pressure Monitoring: Invasive versus Non-Invasive Methods- A Review. *Crit Care Res Pract.* 2012; 2012:950393. doi: 10.1155/2012/950393. Epub 2012 Jun 8. PMID: 22720148; PMCID: PMC3376474.
- Bellner J, Romner B, Reinstrup P, Kristiansson KA, Ryding E, Brandt L. Transcranial Doppler sonography pulsatility index (PI) reflects intracranial pressure (ICP) Surgical Neurology. 2004;62(1):45-51.

14. Moreno JA, Mesalles E, Gener J, Tomasa A, Ley A, Roca J, et al. Evaluating the outcome of severe head injury with transcranial Doppler ultrasonography. *Neurosurgical focus*. 2000 Jan 1;8(1):1-7.
15. Pradeep R, Gupta D, Shetty N, Bhushan AK, Haskar K, Gogineni S, et al. Transcranial Doppler for Monitoring and Evaluation of Idiopathic Intracranial Hypertension. *J Neurosci Rural Pract*. 2020 Apr;11(2):309-314. doi: 10.1055/s-0040-1710086. Epub 2020 May 2. PMID: 32405187; PMCID: PMC7214091
16. Baumgartner RW, Mathis J, Sturzenegger M, Mattle HP. A validation study on the intraobserver reproducibility of transcranial color-coded duplex sonography velocity measurements. *Ultrasound in medicine & biology*. 1994 Jan 1;20(3):233-7.
17. Kafle P, Khanal B, Yadav DK, Poudel D, Karki T, Cherian I. Head Injury in Nepal: An Institutional Based Prospective Study on Clinical Profile, Management and Early Outcome of Traumatic Brain Injury in Eastern Part of Nepal. *Birat J. Health Sci*. [Internet]. 2019 Sep. 4 [cited 2021 Aug. 14];4(2):750-4.
18. Khadka NK, Karmacharya BG, Jha R, Adhikary DR, Sharma GR, Bista P, et al. An Audit of Head Injury at Bir Hospital. *Nepal journal of Neuroscience*. 2013 Jul 1;10(2).
19. Singer KE, Wallen TE, Jalbert T, Wakefield D, Spuzzillo A, Sharma S, et al. Efficacy of Noninvasive Technologies in Triaging Traumatic Brain Injury and Correlating with Intracranial Pressure: A Prospective Study. *Journal of Surgical Research*. 2021 Jun 1;262:27-37. <https://doi.org/10.1016/j.jss.2020.12.042>.
20. Bishop CC, Powell S, Rutt D, Browse NL. Transcranial Doppler measurement of middle cerebral artery blood flow velocity: a validation study. *Stroke*. 1986;17:913-5. <https://doi.org/10.1161/01.STR.17.5.913>
21. Wang HB, Laskowitz DT, Dodds JA, Xie GQ, Zhang PH, Huang YN, et al. Peak systolic velocity measurement with transcranial doppler ultrasound is a predictor of incident stroke among the general population in China. *PLoS one*. 2016 Aug 11;11(8): e0160967.