

# Vaginal Atresia with Cervical Agenesis, a Rare Congenital Malformation

Regmi DR,<sup>1</sup> Dangal G,<sup>2</sup> Karki A,<sup>2</sup> Pradhan HK,<sup>2</sup> Shrestha R,<sup>2</sup> Bhattachan K,<sup>2</sup> Tiwari KD,<sup>2</sup> Bharati S,<sup>2</sup> Manandhar P,<sup>2</sup> Maharjan S<sup>2</sup>

<sup>1</sup>Paropakar Maternity and Women's Hospital,  
Thapathali, Kathmandu.

<sup>2</sup>Department of Obstetrics and Gynecology,  
Kathmandu Model Hospital,  
Kathmandu, Nepal.

## Corresponding Author

Dharma Raj Regmi  
Paropakar Maternity and Women's Hospital,  
Thapathali, Kathmandu.  
E-mail: rdharma861@gmail.com

## Citation

Regmi DR, Dangal G, Karki A, Pradhan HK, Shrestha R, Bhattachan K, et al. Vaginal Atresia with Cervical Agenesis, a Rare Congenital Malformation. *Kathmandu Univ Med J.* 2021;75(3):390-2.

## ABSTRACT

Congenital vaginal atresia and cervical agenesis is a rare congenital abnormality of the female genital tract. Here we report a case of 15-year old girl with primary amenorrhea with hematometra, presented with lower abdominal mass. She was symptomatic since 5 months and visited local hospital after 4 months of onset of her symptoms when it became severe, where diagnostic laparotomy was performed for suspected Adnexal mass. Intraoperatively adnexal mass was adhered with and extended up to the uterus with 16 weeks size of uterus. Abdomen was closed without any further intervention and was referred to higher center for needful. When she presented to Kathmandu Model Hospital, she was asymptomatic on her 5<sup>th</sup> post-operative day of laparotomy. We planned for surgical intervention after examination and investigation. Drainage with vaginoplasty with amnion graft with placement of mould was done.

## KEY WORDS

*Congenital cervical agenesis, Hematometra, Vaginal atresia, Vaginoplasty.*

## INTRODUCTION

Mullerian duct anomalies occur due to the non-development or defective fusion or failure of resorption of the paramesonephric (Mullerian) ducts. The prevalence of female genital tract anomalies is 4-7% in general population and up to 8-10% in women who have recurrent pregnancy loss.<sup>1</sup> Incidence of Mullerian duct anomaly is approximately 1% in general population and it is approximately 3% in patients with infertility. Cervical agenesis or atresia or dysgenesis is an extremely rare congenital anomaly with an occurrence of about 1 in 80,000 to 100,000 births.<sup>2</sup> It may be isolated or associated with partial or complete agenesis of vagina. Diagnosis of cervical atresia is a difficult entity but the possibility of making a correct diagnosis prior to surgery do exists with the help of ultrasound and MRI.<sup>3</sup>

For many decades, the mainstay of treatment for congenital cervical malformations was hysterectomy. However, as a consequence of the evolution of surgery and growing experience in the field of reconstructive techniques, conservative surgical management has become an option, with improved long-term outcomes in cases with congenital cervical malformations. Some reviews summarize that

contemporary knowledge in the field of conservative surgical restoration of the reproductive tract in women with congenital cervical agenesis/ dysgenesis.<sup>4</sup>

The combination of partial cervical agenesis and complete vaginal atresia is a rare variation of obstructive Mullerian abnormalities that could present with primary amenorrhea and cyclical pelvic pain. The challenges of accurate diagnosis of complete or partial cervical agenesis by using magnetic resonance imaging, and subsequent complexity of balancing surgical and non-surgical management, can lead to delay in definitive diagnosis and consequent significant morbidity and mortality.<sup>5</sup>

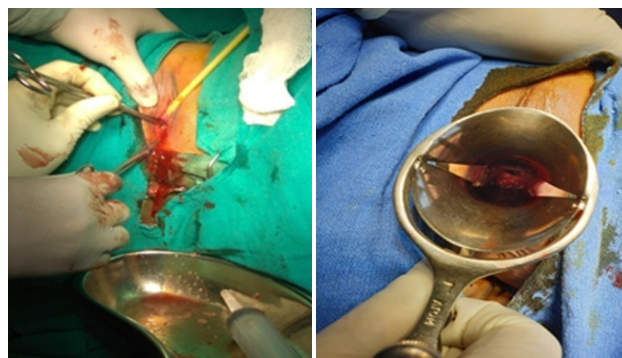
Vaginal atresia, a rare Müllerian anomaly, with an incidence of 1/4000 to 1/10000 persons, is frequently characterized by a normal lower vagina or the absence of a vagina.<sup>6</sup> Vaginal atresia can present as distal or total vaginal atresia, and in the latter case, the uterus always has an anatomically normal corpus and cervical aplasia, except in sporadic patients, in whom a rudimentary horn accompanies the uterus.<sup>7</sup>

## CASE REPORT

A 15-year old girl presented to Kathmandu Model Hospital with chief complain of primary amenorrhea with abdominal mass associated with lower abdominal pain for 5-6 months. She was symptomatic since 5 months at that time she used to have abdominal pain in cyclical manner which relieved by taking some oral medication however since one month before the presentation abdominal pain was severe enough to seek for health checkup, went to local medical shop where advised to go district hospital. At district hospital she was examined, investigated and planned for diagnostic laparotomy for lower abdominal mass. During laparotomy procedure they found adnexal mass with enlarged uterus, there was no active bleeding, abdomen was closed without any intervention and referred to higher center for needful.

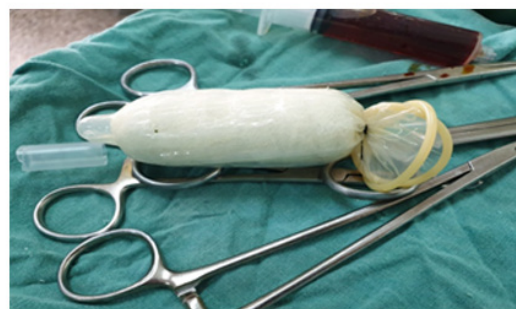When she arrived to Kathmandu Model Hospital on her 5<sup>th</sup> postoperative day of diagnostic laparotomy there was no complaint however she was having abdominal discomfort. After taking thorough history, she was examined and investigated. On examination the girl had normal secondary sexual characteristics on pelvic examination there was blind vagina without any opening. Her blood parameters were in normal limit and Trans-abdominal pelvic ultrasound revealed the uterus with internal endometrial collection showing low level internal echoes with non-visualization of the cervix and vaginal canal with normal bilateral adnexa. CT abdomen and Pelvis, showed grossly distended uterus with gross collection measuring 10 cm x 8 cm x 8.4 cm (volume: 336 ml), elevated uterus and anteriorly compressing the urinary bladder posteriorly displacing rectum, no uterine anomaly noted, vaginal morphology could not be assessed. After all investigation and evaluation diagnosis was made to be primary amenorrhea with hematometra due to vaginal atresia with suspected cervical agenesis and planned for drainage with vaginoplasty.

She had undergone Drainage and Vaginoplasty with placement of mould in situ, in which the neovagina was created after dissecting space between urinary bladder anteriorly and anorectal canal posteriorly through which lower end of the uterus can be seen without any opening. A small nick was given at the lowest middle of the bulged part of the uterus and dilator inserted through it and hole is created (figure 2). Coffee brown color of collection as shown in figure 1, drained about 200 ml, cleaning of the cavity with warm normal saline was done at the end. Then intermediate thickness amnion graft taken was grafted in vagina over soft mould (figure 3). A foleys drain was also kept from the center of the mould for drainage of collection from uterine cavity. Patient was kept under catheterization with the drain and mould in situ for 8 days. The graft was taken up well by 9<sup>th</sup> postoperative day and the mould was change on that day, foley catheter and foley drain removed, planned for discharge on the next day. Patient was explained to use soft mould or dilator for next 15 days followed by hard mould/dilator.



**Figure 1.** Creating a space between the urinary bladder and the rectum and drainage of hematometra.

**Figure 2.** Showing hole at lower pole of uterus.



**Figure 3.** Condom covering foam piece rapped with gauze piece.

## DISCUSSION

We described a case of genital anomaly, which is rare one. The classification systems of the American Fertility Society do not include this condition however it is classified by the European Society of Human Reproduction and Embryology and the European Society for Gynecological Endoscopy system released in 2013 as U2bc4V4.<sup>8,9</sup>

The confirmation of the diagnosis is inevitably a psychological shock for the patient and her family. The absence of a vagina has a profound impact on the young woman's sense of femininity. Aesthetically and functionally inadequate correction can result in major psychological problems in adolescent age and even result in marital disputes. Counselling the parents and making them a part of the treatment team helps in promoting long term satisfaction. The treating surgeon must keep in mind to be practical and not give too many assurances to the patient and family. Vaginoplasty is considered as the major therapeutic strategy for these patients. The main reason for the creation of a neo vagina is to make sexual intercourse possible for these patients. Ideally, the creation of a neo vagina should be simple, safe, and most importantly, should allow for satisfactory sexual intercourse. In some cases with a normal uterus, it might even be possible to have a child.

Cervical agenesis with vaginal atresia, this kind of congenital malformations are very rare entities that currently can be managed with conservative surgical treatment. The postoperative results are usually satisfactory: menstruation and sexual activity are established in the majority of the

patients. Fecundity may be preserved as well in many cases, although the number of reported pregnancies has been small. Extirpation surgery may be preserved for surgical failures after initial restoration of the continuity of uterus-cervix-vagina or in cases with more complex anatomy.

In conclusion, such a case is significant for clinical management and emerges as a novel anomaly that

supports one embryologic concept. It may be necessary to determine the malformation during sterile operation. Also it is of crucial importance for us to observe the patient well into reproductive and obstetric outcomes in future. The postoperative results are usually satisfactory: menstruation and sexual activity are established in the majority of the patients. Fecundity may be preserved as well in many cases.

## REFERENCES

1. Stray Pedersen B, Stray Pedersen S. Etiologic factors and subsequent reproductive performance in 195 couples with a prior history of habitual abortion. *Am J Obstet Gynecol.* 1984;148:140-6.
2. Raga F, Bauset C, Remohi J, Bonilla Musoles F, Simón C, Pellicer A. Reproductive impact of congenital Müllerian anomalies. *Hum Reprod.* 1997;12:2277-81.
3. Dwivedi D, Jain M, Jain S, Jain S. A rare case report on complete cervical agenesis with vaginal atresia and suspended didelphys uterus with hematometra and left haematosalpinx. *Int J Reprod Contracept Obstet Gynecol.* 2020 Mar;9(3):1274-7. DOI: doi.org/10.18203/2320-1770.ijrcog20200914.
4. Mikos T, Gordts S, Grimbizis GF. Current knowledge about the management of congenital cervical malformations: a literature review. *Fertility and sterility.* 2020 Apr 1;113(4):723-32.
5. Kimble R, Molloy G, Sutton B. Partial cervical agenesis and complete vaginal atresia. *Journal of pediatric and adolescent gynecology.* 2016 Jun 1;29(3):e43-7. DOI: 10.1016/j.jpag.2015.11.004
6. Karapınar OS, Özkan M, Okyay AG, Şahin H, Dolapçioğlu KS. Evaluation of vaginal agenesis treated with the modified McIndoe technique: a retrospective study. *Journal of the Turkish German Gynecological Association.* 2016;17(2):101-5.
7. Han TT, Chen J, Wang S, Zhu L. Vaginal atresia and cervical agenesis combined with asymmetric septate uterus: A case report of a new genital malformation and literature review. *Medicine.* 2018 Jan;97(3).
8. The American Fertility Society classifications of adnexal adhesions, distal tubal occlusion, tubal occlusion secondary to tubal ligation, tubal pregnancies, mullerian anomalies and intrauterine adhesions. *Fertil Steril.* 1988;49:944-55.
9. Grimbizis GF, Gordts S, Di Spiezio Sardo A, et al. The ESHRE/ESGE consensus on the classification of female genital tract congenital anomalies. *Hum Reprod.* 2013;28:2032-44.