

Endoscopic stapes surgery: How I do it?

Shrestha BL

Department of ENT-HNS
Dhulikhel Hospital, Kathmandu University Hospital,
Kathmandu University School of Medical Sciences,
Dhulikhel, Kavre, Nepal.

Corresponding Author

Bikash Lal Shrestha
Department of ENT-HNS
Dhulikhel Hospital, Kathmandu University Hospital,
Kathmandu University School of Medical Sciences,
Dhulikhel, Kavre, Nepal.
E-mail: bikashotology@kusms.edu.np

Citation

Shrestha BL. Endoscopic stapes surgery: How I do it?.
Kathmandu Univ Med J. 2021;75(3):387-9.

ABSTRACT

The use of endoscope in the field of ear surgery has done the revolutionary changes. The optical advantage of endoscope helps the otologist to perform the stapes surgery very conveniently. The main advantage of the endoscope in stapes surgery over the microscope is; the better preservation rates of the chorda tympani nerve (CTN), minimal curetting of the outer attic wall, hence minimizing the iatrogenic injury to the CTN. Apart from that, the audiometric results following the endoscopic stapes surgery is comparable with the microscopic surgery. We had performed the stapes surgery with the rigid nasal endoscopes (Karl Storz) of 4-mm diameter and 18-cm length. Our preliminary results showed that transcanal endoscopic stapedotomy is a reliable and safe technique for the surgical management of otosclerosis.

KEY WORDS

Endoscope, Microscope, Otosclerosis, Stapes surgery

INTRODUCTION

Stapedotomy surgery is known as the king of all the otological surgeries because it is technically difficult and challenging due to anatomic variations in size, shape, configuration, or irregularity of the external ear canal, and the position of stapes and oval window niche (OWN) which can be obscured by the scutum. Since the otosclerosis disease description by Valsalva in 1704, the surgery for the otosclerosis has evolved from removal of ossicles as described by Kessel to modern day small fenestra stapedotomy described by Ugo Fisch.¹⁻³ Similarly, recently developed technique of endoscopic assisted stapedotomy by Poe in 2000 also done the revolutionary changes in stapes surgery.⁴

The 0 degree nasal endoscope of 4 mm diameter and 18 cm in length provide the panoramic view and amplified image on the monitor, thus making the surgeon comfortable for performing the surgery.

Our experience with over 1000 endoscopic ear surgeries since 2012 showed that a transcanal endoscopic approach to the middle ear allows to obtain the adequate access to the stapes and OWN without dividing the CTN. This view

point describes our endoscopic stapes surgical technique and preliminary results of the first 3 transcanal endoscopic stapedotomies in our institution. We highly recommended that otologists who are interested to adapt the endoscope in stapedotomy should acquire adequate experience in all aspects of total endoscopic ear surgery for middle ear disorders.

Surgical procedure (endoscopic stapes surgery)

Preparation of the external auditory canal

The patient is kept on supine position with the head turned towards opposite side. The operating ear is examined by 0 degree nasal endoscope. The ear canal is slowly infiltrated with 1:2,00,000 lignocaine with adrenaline solution in all the four quadrants. It is necessary to perform the infiltration slowly to avoid blistering formation in the canal skin. After infiltration, the ear canal is packed with cottonoids soaked in 1:1000 adrenaline to reduce bleeding. The surgery is performed under general anesthesia.

Elevation of the tympano-meatal flap (fig. 1)

Following sterile preparation and draping, the nasal

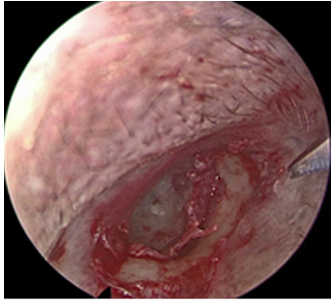


Figure 1. Elevation of tympanomeatal flap (left ear)

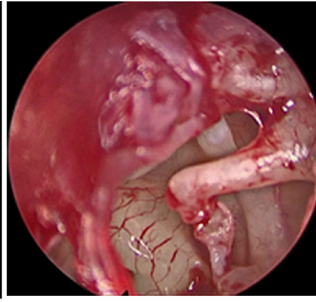


Figure 2. Showing crucial middle ear structures.

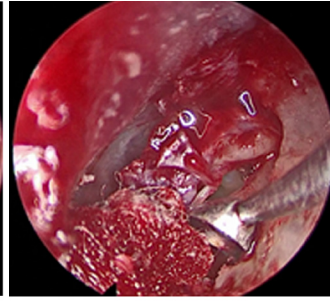


Figure 3. Bone curette of overhang scutum (medial to lateral direction).

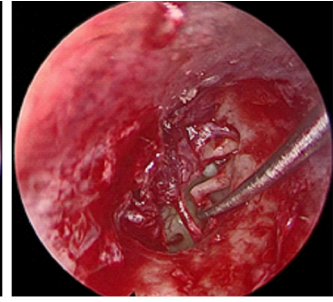


Figure 4. Disarticulation of incudostapedial joint with joint knife.

endoscope (0 degree, 4 mm) is used to examine the ear. The canal incision is given at 6 O'clock and 12 O'clock position with Plester knife. Then the two incisions are joined with Rosen knife and tympanomeatal flap is elevated upto the annulus. Once the annulus is identified, the middle ear is entered, making sure that the chorda tympani nerve is well preserved.

Exposure of the crucial middle ear structures (fig. 2)

After the middle ear is entered, the landmarks that have to be clearly under vision are; the facial nerve, short process of malleus, pyramid, stapedius tendon, incudostapedial joint and the stapes footplate (fig. 2). If the assess is limited because of bony overhang of the scutum, it is required to curette (fig. 3).

Confirmation of the diagnosis and removal of the stapes suprastructure

After the proper visualization of all crucial structures, the incudostapedial joint is disarticulated with joint knife (fig. 4) and the mobility of the incudomalleolar joint is assessed first to rule out the malleus head fixation followed by stapes mobility.

Using a stapes measuring rod, the piston length is measured from the footplate to the medial surface of the incus long process (fig. 6) and 0.25 -0.5 mm added to this distance.

Creation of fenestration and placement of piston

Footplate fenestration is performed with manual perforator of 0.6mm size between middle and inferior third of the footplate (fig. 7). The perforator is rotated back and forth between the thumb and index finger of right hand.

Utmost care is taken to avoid any direct suction over the footplate area. Titanium piston of 3.5 mm length and 0.5mm diameter is placed in the oval window in this particular case and crimped onto the long process of the incus (fig. 8). The sealing of the oval window is performed with small pieces of connective tissues. The ossicular chain mobility is checked and the TM flap is repositioned. Absorbable gel foam is placed in the ear canal.

Surgical video: <https://youtu.be/sEatvrG4aQo>

Audiological Results:

The average time taken for the surgery was 55 minutes with maximum being 70 minutes and minimum being 45 minutes. The pure tone audiogram done at 6 weeks post-

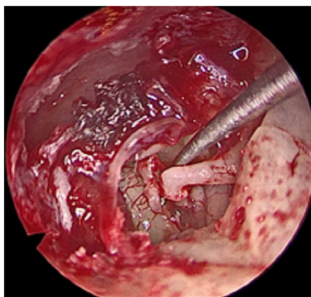


Figure 5. Down fracturing of the stapes towards promontory with 2.5 mm, 45 degree hook.

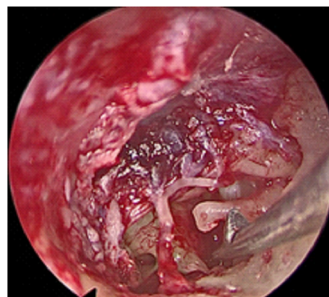

Figure 6. Measurement of piston length with stapes measuring rod.

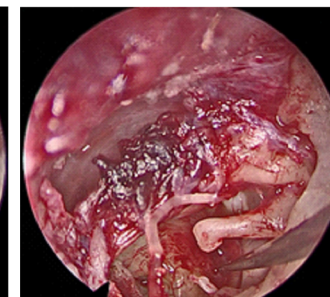


Figure 7. Footplate fenestration with manual perforator.

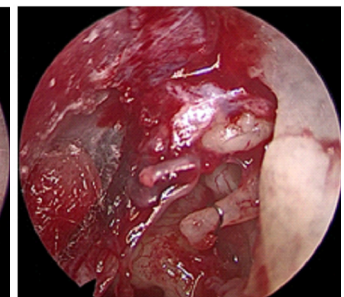


Figure 8. Placement of titanium piston (3.5 mm length and 0.5 mm diameter) on the long process of incus.

Once the diagnosis is confirmed, the stapedius tendon is divided with the small tympanoplasty microscissor, posterior crurotomy is performed with crurotomy scissor and then stapes suprastructure is removed by down fracturing the stapes towards promontory with 2.5 mm, 45 degree hook (fig. 5).

surgery showed complete air-bone gap closure within 10dB in all the 3 cases.

One patient developed vertigo post-operatively which subsided after taking medication. We are following these patients for the long term results.

CONCLUSION

Our preliminary results showed that it is comfortable and easy to do the stapedotomy with 0 degree nasal endoscope. The advantages are: Good quality panoramic image of the middle ear anatomy, limited need to curette the outer attic and posterior superior canal wall, minimal handling of

chorda tympani nerve. The disadvantages are: One handed technique and lack of depth perception.

So the surgeons who want to perform the endoscopic stapedotomy should gain in depth knowledge and experience in all forms of endoscopic middle ear surgery before performing the stapes surgery.

REFERENCES

1. Meirelles RC, Neves-Pinto RM, Potsch AA. Antonio Maria Valsalva-biographical profile of a pioneer of otology. *Int Arch Otorhinolaryngol.* 2008;12(2):274–79.
2. Howard HP. The evolution of otosclerosis surgery. *Otolaryngol Clin N Am.* 1993;26:323–33.
3. Fisch U. Stapedotomy versus Stapedectomy. *Am J Otol.* 1992;4:112–7.
4. Poe DS. Laser-assisted endoscopic stapedectomy: a prospective study. *Laryngoscope.* 2000;110 (5 Pt 2 Suppl 95):1–37.

Link for Surgical Video: <https://youtu.be/sEatvrG4aQo>