

Role of Magnetic Resonance Cholangiopancreatography in the Evaluation of Obstructive Jaundice

Karki S, Phuyal A, Paudel RC, Bhandari A, Dahal MR

Department of Radiodiagnosis and Imaging
Kathmandu University School of Medical Sciences,
Dhulikhel Hospital, Kathmandu University Hospital,
Dhulikhel, Kavre, Nepal.

Corresponding Author

Subindra Karki
Department of Radiodiagnosis and Imaging,
Kathmandu University School of Medical Sciences,
Dhulikhel Hospital, Kathmandu University Hospital,
Dhulikhel, Kavre, Nepal.
E-mail: subindrakarki@gmail.com

Citation

Karki S, Phuyal A, Paudel RC, Bhandari A, Dahal MR. Role of Magnetic Resonance Cholangiopancreatography in the Evaluation of Obstructive Jaundice. *Kathmandu Univ Med J.* 2021;73(1):35-40.

ABSTRACT

Background

Magnetic Resonance Cholangiopancreatography is a reliable and highly sensitive imaging modality in the diagnosis of Obstructive jaundice.

Objective

To evaluate the diagnostic accuracy of Magnetic Resonance Cholangiopancreatography as compared to Endoscopic Retrograde Cholangiopancreatography.

Method

A prospective, analytical study was conducted in the Department of Radiodiagnosis and Imaging at Dhulikhel Hospital between October 2018 and December 2020. Altogether 100 patients of all ages with obstructive jaundice undergoing Magnetic Resonance Cholangiopancreatography and Endoscopic Retrograde Cholangiopancreatography were included. The causes of obstructive jaundice as identified by Magnetic Resonance Cholangiopancreatography were compared to that of Endoscopic Retrograde Cholangiopancreatography considering Endoscopic Retrograde Cholangiopancreatography as gold standard for the diagnosis.

Result

Magnetic Resonance Cholangiopancreatography revealed choledocholithiasis in 60 (60%) patients, benign stricture – 14(14%), malignant stricture-11(11%), peri-ampullary carcinoma in 8(8%) and normal study in 4(4%) patients. Endoscopic Retrograde Cholangiopancreatography showed choledocholithiasis in 59(59%) patients, strictures (benign in 13%, malignant in 10%), ascariasis in 3(3%) and normal findings in 5(5%) patients. The sensitivity, specificity, positive predictive value and negative predictive value of Magnetic Resonance Cholangiopancreatography in detecting choledocholithiasis were 96.6%, 92.3%, 95%, and 95%. The same values for benign strictures were 92.3%, 97.7%, 85.7% and 98.9%, whereas those for malignant strictures were 90.9%, 98.8%, 90.9% and 98.8%. All values were 100% for peri-ampullary carcinoma and ascariasis. Hence, Magnetic Resonance Cholangiopancreatography showed good accuracy for detecting causes of obstructive jaundice ($p < 0.05$) as compared to Endoscopic Retrograde Cholangiopancreatography.

Conclusion

Magnetic Resonance Cholangiopancreatography is an accurate, non-invasive technique in evaluation of obstructive jaundice and offers similar diagnostic value compared to Endoscopic Retrograde Cholangiopancreatography.

KEY WORDS

Endoscopic retrograde, Magnetic resonance cholangiopancreatography, Obstructive jaundice

INTRODUCTION

Obstructive jaundice occurs due to obstruction of drainage of bile from liver into intestine. It can be evaluated by noninvasive modalities like Ultrasonography (USG), Computed tomography (CT), Magnetic resonance cholangiopancreatography (MRCP) or invasive modalities like Percutaneous Transhepatic Cholangiogram (PTC), Endoscopic ultrasonography (EUS) and Endoscopic Retrograde Cholangiopancreatography (ERCP).

MRCP is an established diagnostic technique used for detection of pancreaticobiliary disorders.¹ Its sensitivity and specificity are higher than other non-invasive techniques and comparable with that of ERCP.¹

Although considered gold standard for diagnosis, ERCP is highly operator dependent and loaded with complications.²⁻⁶ However, its diagnostic and therapeutic role cannot be denied.

Dhulikhel Hospital is the main tertiary referral center for ERCP in Nepal. To date, there have been very few studies highlighting the diagnostic accuracy of MRCP and ERCP in Nepal. Our study aims to evaluate and compare the diagnostic accuracy of MRCP with ERCP in patients with obstructive jaundice.

METHODS

This was a prospective, analytical study conducted in the Department of Radiodiagnosis and Imaging at Dhulikhel Hospital between October 2018 and December 2020. The study was approved by Kathmandu University School of Medical Sciences Institutional Review Committee.

A total of 100 patients of all age groups diagnosed as obstructive jaundice by clinical assessment, biochemical studies or imaging modalities (abdominal ultrasonography and Computed tomography scanning of abdomen) who underwent MRCP and subsequently ERCP were included in this study. Convenient sampling technique was used.

The laboratory findings were considered indicative of Obstructive jaundice when alkaline phosphatase or glutamyl transpeptidase values were more than twice the normal and serum bilirubin exceeded a value of 2 mg/dl.

Patients fit to undergo both MRCP and ERCP, patients with pneumobilia or normal findings in MRCP who eventually undergo ERCP were included in the study. However, patients with obstructive jaundice who don't undergo ERCP (choledochal cyst, metastatic compression) were excluded. Similarly, patients with obstructive jaundice who had undergone prior ERCP with stent in situ in the biliary tree and patients with obstructive jaundice contraindicated for ERCP or failed ERCP were also not enrolled in our study.

The patient was first explained in detail about the MRCP procedure. Written informed consent was taken from each patient or patient's attendant following a detailed

explanation of the objectives and protocol of the study. A clinical data proforma was filled up.

MRCP was performed in Philips - Ingenia 1.5 Tesla MR System. The patient undergoing MRCP was kept on 6 hours of fasting state prior to performing the procedure in order to reduce peristalsis and gastroduodenal fluid before imaging. The patient was asked to drink 300 ml of pineapple juice 15 minutes before the procedure so as to suppress the signal intensity from the gastroduodenal secretions and hence signals of only bile flowing structures were appreciated as high signals. The patient was then placed in Magnetic Resonance (MR) Scanner. Body coil and Respiratory gating was used. The following sequences were taken-a)T2WI – Axial, b)T2 SPAIR – Axial, c)T1WI – Axial (Inphase and Outphase), d)T2 SPAIR – Coronal, e)3D MRCP (HD) and Diffusion weighted Image(DWI) (b value 800) – if needed. Images were obtained, saved, studied and reports were printed.

The patient was followed up in the Department of Gastroenterology where ERCP was to be performed. MRCP was done a day prior to ERCP. Finally, the MRCP report was compared with ERCP, taking the ERCP as a reference. In addition, whenever biopsy was performed under ERCP guidance, the reports of patients were traced from the Department of Pathology and included as the final diagnosis.

Statistical analysis was carried out by using the Statistical Package for Social Science software (IBM SPSS Statistics 21, Chicago, USA). Descriptive, inferential and comparative statistics were measured. Fisher's exact test was used to compare groups. A p-value < 0.05 was considered to be statistically significant.

RESULTS

Sixty eight percent were females and 32% were males. The minimum age was 19, and the maximum was 83 years (mean age 49.3 years). Obstructive jaundice was found to be most prevalent in the age group of 30-60 years (69%). Twenty one percent of the patients were more than 60 years and rest were less than 30 years. With both MRCP and ERCP, choledocholithiasis was predominantly seen in female patients. Also benign strictures were more prevalent in females than in males.

Comparison of MRCP with ERCP in Causes of Obstructive Jaundice

Choledocholithiasis

Out of 100 patients, choledocholithiasis was by far the most common cause of obstructive jaundice. MRCP showed choledocholithiasis (fig. 1) in 60 (60%) patients. ERCP revealed stone in 57 out of 60 patients. Also 2 of the 4 patients that were found to be essentially normal (pneumobilia) by MRCP, were diagnosed as choledocholithiasis in subsequent ERCP. Hence, the

sensitivity, specificity, Positive predictive value (PPV) and Negative predictive value (NPV) of MRCP in the diagnosis of choledocholithiasis were 96.6%, 92.6%, 95.0% and 95.0% respectively.

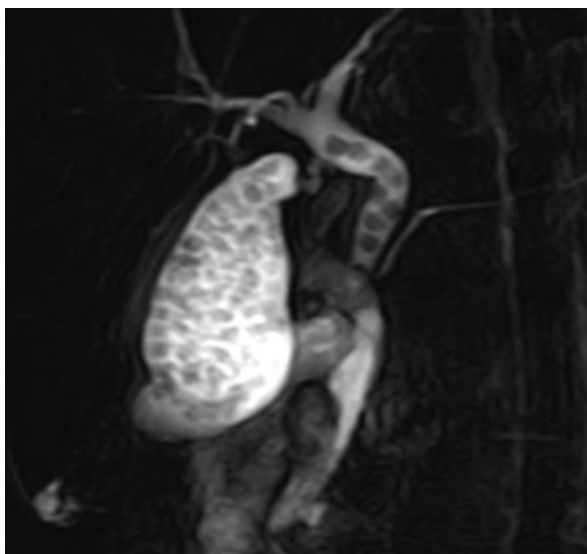

Figure 1. MRCP showing multiple cholecystolithiasis and choledocholithiasis

Benign Strictures

MRCP showed benign stricture (fig. 2) as cause of obstructive jaundice in 14 patients. ERCP however showed that 2 of these 14 patients had malignant rather than benign strictures. Also, one of the malignant strictures misdiagnosed by MRCP was found as benign in ERCP. Hence, the sensitivity, specificity, PPV and NPV of MRCP for the diagnosis of benign strictures were 92.3%, 97.7%, 85.7% and 98.8% respectively.

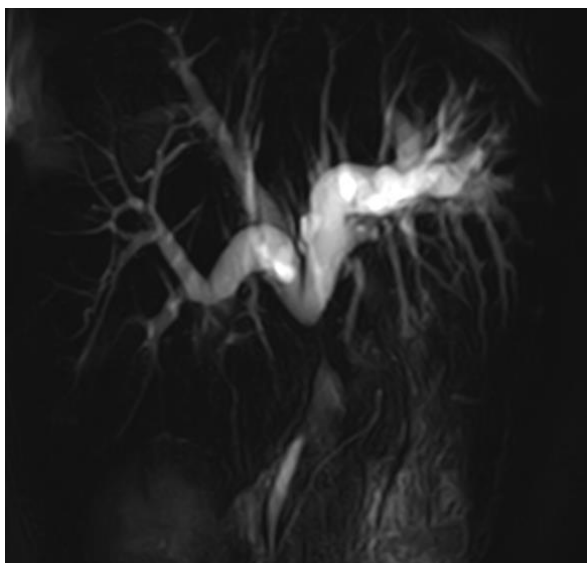


Figure 2. MRCP showing post-operative benign stricture

Malignant Strictures

Out of 11 patients suspected as malignant strictures (fig. 3) by MRCP, one turned out to be benign by ERCP. Again, findings of two patients predicted as benign in MRCP

were found to be malignant in ERCP. Thus, the sensitivity, specificity, PPV and NPV of MRCP compared to ERCP in diagnosis of malignant stricture were 90.9%, 98.8%, 90.9% and 98.8%.

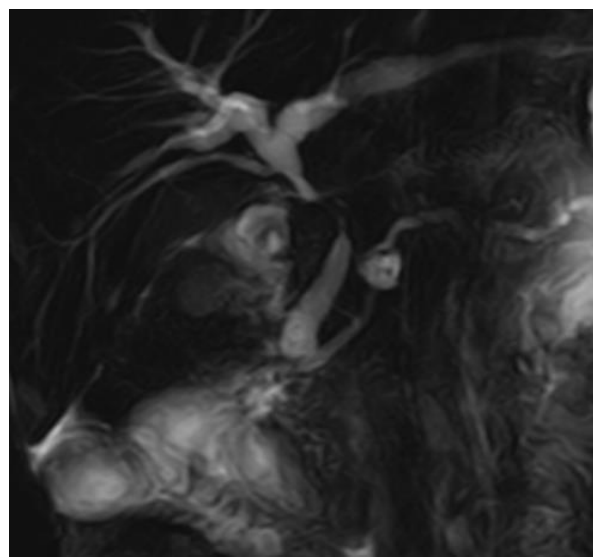


Figure 3. MRCP showing malignant CBD stricture with pancreatic duct cyst

Peri-ampullary Carcinoma

Eight patients were diagnosed as peri-ampullary carcinoma by both MRCP and ERCP making MRCP 100% sensitive and specific in its diagnosis.

Biliary Ascariasis

Both MRCP and ERCP found biliary ascariasis (fig. 4) as cause of obstructive jaundice in 3 patients making MRCP 100% sensitive and specific in its diagnosis.

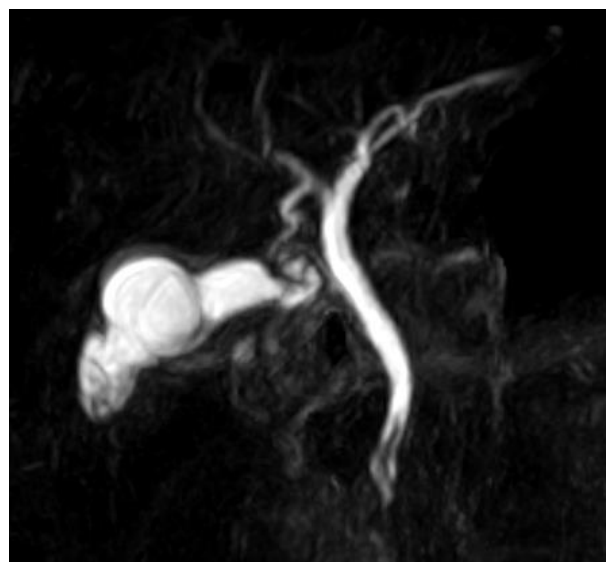


Figure 4. MRCP showing worm in CBD (biliary ascariasis)

Our results demonstrate that Magnetic Resonance Cholangiopancreatography had good accuracy for detecting causes of obstructive jaundice ($p < 0.05$) as compared to Endoscopic Retrograde Cholangiopancreatography.

The sensitivity, specificity, PPV and NPV of MRCP for the diagnosis of individual causes of obstructive jaundice taking ERCP as reference has been illustrated in Table 1.

Table 1. Diagnostic value of MRCP in obstructive jaundice (n = 100)

MRCP Findings	Sensitivity (%)	Specificity (%)	PPV (%)	NPV (%)
Choledocholithiasis	96.6	92.6	95.0	95.0
Benign Stricture	92.3	97.7	85.7	98.8
Malignant Stricture	90.9	98.8	90.9	98.8
Periampullary Carcinoma	100	100	100	100
Ascariasis	100	100	100	100

Histopathological findings in relation to neoplastic causes of Obstructive Jaundice

MRCP revealed malignant causes in 19 patients (19%) and ERCP detected malignancy in 20 patients (20%). However, histopathological analysis concluded 15 patients (15%) to be positive for malignancy. Eight out of these had cholangiocarcinoma as the cause of malignant strictures. In 7 patients with peri-ampullary carcinoma, histology revealed 3 to have distal cholangiocarcinoma and 2 each had pancreatic and ampullary carcinoma. However, in 2 cases of malignant strictures, no definite conclusion of benignity or malignancy could be derived due to sample inadequacy. Two of the cases of malignant strictures were not sent for histopathological analysis due to excessive intraoperative bleeding. Moreover, one patient suspected as peri-ampullary carcinoma in both MRCP and ERCP turned out to be pancreatic head tuberculosis.

DISCUSSION

It is important to diagnose obstructive jaundice timely in order to prevent secondary pathological changes that can occur as a result of biliary obstruction. In the present study, majority of patients were female and belonged to an age group of 30 to 60 years.

Based solely on MRCP and ERCP findings, benign causes of obstruction constituted of 75(75%), malignant constituted 20(20%) and 5(5%) of the patients showed normal findings. The predominance of benign causes was largely because of choledocholithiasis being the most frequent cause of obstruction in our study. This finding is consistent with other studies.^{7,8}

Choledocholithiasis accounted for 59% with female predominance and was by far the most frequent cause of obstructive jaundice. Majority of the cases of choledocholithiasis are secondary occurring as a result of migration from the gall bladder and bile duct stones are found in 13.7% of patients with symptomatic gall stones.^{9,10} Because gall stones are more frequent in females, choledocholithiasis with female predominance was the

most common cause of obstructive jaundice. This finding is supported by other studies.^{7,8}

Of the 60 patients diagnosed of having choledocholithiasis by MRCP, ERCP found stones in 57 patients. Also 2 of the 4 patients who were said to have normal findings by MRCP had stones in ERCP. Hence, the sensitivity, specificity, PPV and NPV of MRCP in the diagnosis of choledocholithiasis were respectively 96.6%, 92.6%, 95.0% and 95.0%. Hintze et al. found out the sensitivity and PPV of MRCP in the diagnosing choledocholithiasis to be 86% and 100% respectively.¹¹ All of these mentioned findings are similar to the findings of present study and in contrast with some of the others.¹²

Three patients who were falsely diagnosed of having choledocholithiasis in MRCP (false positive) could have been because of mimickers of choledocholithiasis like pulsation of flow artifacts, pneumobilia and pseudocalculus at the ampulla. Also spontaneous passage of the calculus that were initially detected by MRCP could be possible.^{13,14} Two patients with choledocholithiasis that were missed in MRCP (false negative) could have been because of the aforementioned mimickers or because of the calculus being too small to be detected by the spatial resolution of MRCP.

MRCP detected benign strictures in 14 patients. Findings of ERCP however, demonstrated that two of these 14 patients had malignant rather than benign strictures. Also, in one of the patients misdiagnosed as malignant stricture in MRCP was visualized as benign in ERCP. This resulted in sensitivity, specificity, PPV and NPV of MRCP for the diagnosis of benign strictures in our study to be 92.3%, 97.7%, 85.7% and 98.8% respectively. In a study by Sutharet al. the authors reported that the sensitivity, specificity of MRCP for detection of benign strictures 91.7%, specificity 96.1%.¹⁵

In the present study, 11 patients supposedly had malignant strictures in MRCP of which one case was suspected as benign in ERCP. Also two patients that were reported benign in MRCP turned out malignant in ERCP. Thus the sensitivity, specificity, PPV and NPV of MRCP compared to ERCP in diagnosis of malignant stricture were respectively 90.9%, 98.8%, 90.9% and 98.8%. Similar findings were seen in a meta-analysis of 67 studies, including 4711 patients with suspected biliary obstruction; found that MRCP had a sensitivity and specificity of 88% and 95% in for diagnosing malignant strictures.¹⁶

In present study, the criteria used for differentiation of benign and malignant strictures were length of the stricture, margins and symmetry in narrowing. We found that malignant strictures were long (2.5 cm or more), with irregular margin and asymmetric narrowing. Benign strictures on the other hand were short (1.5 cm or less) with regular margin and symmetric narrowing. These findings were also used for differentiation of benign and malignant strictures in the previously published reports.^{17,18}

Eight patients were predicted of having peri-ampullary carcinoma by MRCP and this finding was confirmed by ERCP as well, rendering MRCP 100% sensitive and specific in the detecting the same. Our findings are in agreement with study performed by Kaltenthaler et al.¹⁹ In the present study, 7 of 8 patients with the diagnosis of peri-ampullary carcinoma had double duct sign. One patient had abrupt narrowing of the peri-ampullary bile duct with gross upstream dilatation without dilatation of the pancreatic duct who was confirmed to have cholangiocarcinoma.

Histopathological analysis were carried in all of these eight patients which confirmed three patients to be suffering from distal cholangiocarcinoma, two patients each had pancreatic head carcinoma and ampullary carcinoma. One patient however was pathologically diagnosed of having pancreatic head tuberculosis. Pancreas is an uncommon site for tuberculosis to occur and its true incidence is not yet well studied.²⁰

MRCP correctly diagnosed three patients with biliary ascariasis making it 100% sensitive and specific compared to ERCP for detection of worm within the biliary tree. Hwang et al. had similar findings in MRCP in two patients who were diagnosed of having biliary ascariasis.²¹

We would also like to highlight the strengths of our study. Dhulikhel Hospital, Kathmandu University Hospital is the main tertiary referral center for evaluation and management of obstructive jaundice in Nepal because of which sample size in our study is relatively larger.

Our study also has some limitations. Observational bias could have occurred both in MRCP and ERCP. Artifacts

including patient's motion, at times interrupted the detailed evaluation of MRCP sections. In addition, ERCP was taken as a reference tool for evaluation of obstructive jaundice in neoplastic lesions as well. However, histopathology is the only definitive diagnostic tool and all the neoplastic lesions weren't sent for histological analysis. Moreover, time delay in performing MRCP and subsequent ERCP after the diagnosis of obstructive jaundice might have some effect specially in the presence of choledocholithiasis. Some very small calculus might have migrated and reached the intestine in this time interval. Similarly, not all cases of obstructive jaundice diagnosed in MRCP were evaluated with ERCP. Patients with obstructive jaundice who were diagnosed of choledochal cysts and gall bladder carcinoma infiltrating the biliary tree were referred for surgical management.

CONCLUSION

MRCP is an accurate, non-invasive imaging modality in the evaluation of obstructive jaundice and offers similar diagnostic value compared to ERCP. Due to its non-invasive nature and ability to avoid complications, it has got the potential to replace diagnostic ERCP in evaluation of obstructive jaundice.

ACKNOWLEDGEMENT

We would like to thank Mr. Sitaram Parajuli for his excellent assistance during the study.

REFERENCES

- Griffin N, Charles-Edwards G, Grant LA. Magnetic resonance cholangiopancreatography: the ABC of MRCP. *Insights Imaging*. 2012;3(1):11-21.
- Patel HT, Shah AJ, Khandelwal SR, Patel HF, Patel MD. MR cholangiopancreatography at 3.0 T. *Radiographics*. 2009 Oct;29(6):1689-706.
- Bor R, Madácsy L, Fábíán A, Szepes A, Szepes Z. Endoscopic retrograde pancreatography: When should we do it? *World J Gastrointest Endosc*. 2015;7(11):1023-31.
- Makmun D, Fauzi A, Shatri H. Sensitivity and Specificity of Magnetic Resonance Cholangiopancreatography versus Endoscopic Ultrasonography against Endoscopic Retrograde Cholangiopancreatography in Diagnosing Choledocholithiasis: The Indonesian Experience. *ClinEndosc*. 2017;50(5):486-90.
- Anderson MA, Fisher L, Jain R, Evans JA, Appalaneni V, Ben-Menachem T, et al. Complications of ERCP. *Gastrointestinal endoscopy*. 2012 Mar 1;75(3):467-73.
- Adler DG, Baron TH, Davila RE, Egan J, Hirota WK, Leighton JA, et al. Standards of Practice Committee of American Society for Gastrointestinal Endoscopy. ASGE guideline: the role of ERCP in diseases of the biliary tract and the pancreas. *Gastrointest Endosc*. 2005 Jul;62(1):1-8.
- Sun H, Tang H, Jiang S, Zeng L, Chen EQ, Zhou TY, et al. Gender and metabolic differences of gallstone diseases. *World journal of gastroenterology: WJG*. 2009 Apr 21;15(15):1886.
- Bekele Z, Yifru A. Obstructive jaundice in adult Ethiopians in a referral hospital. *Ethiop Med J*. 2000 Oct;38(4):267-75.
- Molvar C, Glaenger B. Choledocholithiasis: Evaluation, Treatment, and Outcomes. *Semin Intervent Radiol*. 2016;33(4):268-76.
- Chen H, Jorissen R, Walcott J, Nikfarjam M. Incidence and predictors of common bile duct stones in patients with acute cholecystitis: a systematic literature review and meta-analysis. *ANZ J Surg*. 2020 Sep;90(9):1598-1603.
- Hintze RE, Adler A, Veltzke W, Abou-Rebyeh H, Hammerstingl R, Vogl T, et al. Clinical significance of magnetic resonance cholangiopancreatography (MRCP) compared to endoscopic retrograde cholangiopancreatography (ERCP). *Endoscopy*. 1997 Mar;29(3):182-7.
- Phillips EH. Controversies in the management of common duct calculi. *Surg Clin North Am*. 1994 Aug;74(4):931-48.
- Tranter SE, Thompson MH. Spontaneous passage of bile duct stones: frequency of occurrence and relation to clinical presentation. *Ann R Coll Surg Engl*. 2003 May;85(3):174-7.
- Collins C, Maguire D, Ireland A, Fitzgerald E, O'Sullivan GC. A prospective study of common bile duct calculi in patients undergoing laparoscopic cholecystectomy: natural history of choledocholithiasis revisited. *Ann Surg*. 2004 Jan;239(1):28-33.
- Suthar M, Purohit S, Bhargav V, Goyal P. Role of MRCP in Differentiation of Benign and Malignant Causes of Biliary Obstruction. *J Clin Diagn Res*. 2015;9(11):TC08-TC12.

16. Romagnuolo J, Bardou M, Rahme E, Joseph L, Reinhold C, Barkun AN. Magnetic resonance cholangiopancreatography: a meta-analysis of test performance in suspected biliary disease. *Ann Intern Med.* 2003 Oct 7;139(7):547-57.
17. Park MS, Kim TK, Kim KW, Park SW, Lee JK, Kim JS, Lee JH, Kim KA, Kim AY, Kim PN, Lee MG, Ha HK. Differentiation of extrahepatic bile duct cholangiocarcinoma from benign stricture: findings at MRCP versus ERCP. *Radiology.* 2004 Oct;233(1):234-40.
18. Bain VG, Abraham N, Jhangri GS, Alexander TW, Henning RC, Hoskinson ME, et al. Prospective study of biliary strictures to determine the predictors of malignancy. *Can J Gastroenterol.* 2000 May;14(5):397-402. doi: 10.1155/2000/467567. PMID: 10851279.
19. Kaltenthaler EC, Walters SJ, Chilcott J, Blakeborough A, Vergel YB, Thomas S. MRCP compared to diagnostic ERCP for diagnosis when biliary obstruction is suspected: a systematic review. *BMC Med Imaging.* 2006;6(1):9-24.
20. De Backer AI, Mortelé KJ, Bomans P, De Keulenaer BL, Vanschoubroeck IJ, Kockx MM. Tuberculosis of the pancreas: MRI features. *AJR Am J Roentgenol.* 2005 Jan;184(1):50-4. doi: 10.2214/ajr.184.1.01840050. PMID: 15615950.
21. Hwang CM, Kim TK, Ha HK, Kim PN, Lee MG. Biliary ascariasis: MR cholangiography findings in two cases. *Korean J Radiol.* 2001;2(3):175-178. doi:10.3348/kjr.2001.2.3.175