

# Pediatric Ovarian Torsion: A Diagnostic Challenge in COVID-19 Times

Chanchlani R, Jangid M, Ahmad R, Sharma P

Department of Pediatric Surgery,

All India Institute of Medical Sciences,

Bhopal, India.

## Corresponding Author

Mahendra Jangid

Department of Pediatric Surgery,

All India Institute of Medical Sciences,

Bhopal, India.

E-mail: roshanchanchlani@gmail.com

## ABSTRACT

Ovarian torsion is a rare gynecological emergency in children and an early surgical intervention is needed to salvage the ovary. Herein, we present a case of eight year old girl who presented with complaints of lower abdominal pain during ongoing COVID-19 pandemic. She was diagnosed as a case of ovarian torsion on right side. She underwent exploratory laparotomy and ovarian cystectomy was performed. Delay in diagnosis and treatment of ovarian torsion may have grave consequences, resulting in functional loss of the ovary.

## KEY WORDS

*Ovarian cystectomy, Ovarian torsion, Laparotomy*

## Citation

Chanchlani R, Jangid M, Ahmad R, Sharma P. Pediatric Ovarian Torsion: A diagnostic challenge in COVID times. *Kathmandu Univ Med J.* 2020;COVID-19 Special Issue 70(2):120-3.

## INTRODUCTION

Ovarian torsion is a rare gynecological emergency in children and an early surgical intervention is needed to salvage the ovary. We present a case of eight year old girl admitted in Pediatric Surgery ward during ongoing COVID-19 pandemic with complaints of lower abdominal pain. She was diagnosed as a case of ovarian torsion on right side. She underwent exploratory laparotomy and ovarian cystectomy was performed. Delay in diagnosis and treatment of ovarian torsion may therefore have grave consequences, resulting in functional loss of the ovary. A brief discussion of evaluation, treatment, and management of ovarian torsion follows.

## CASE REPORT

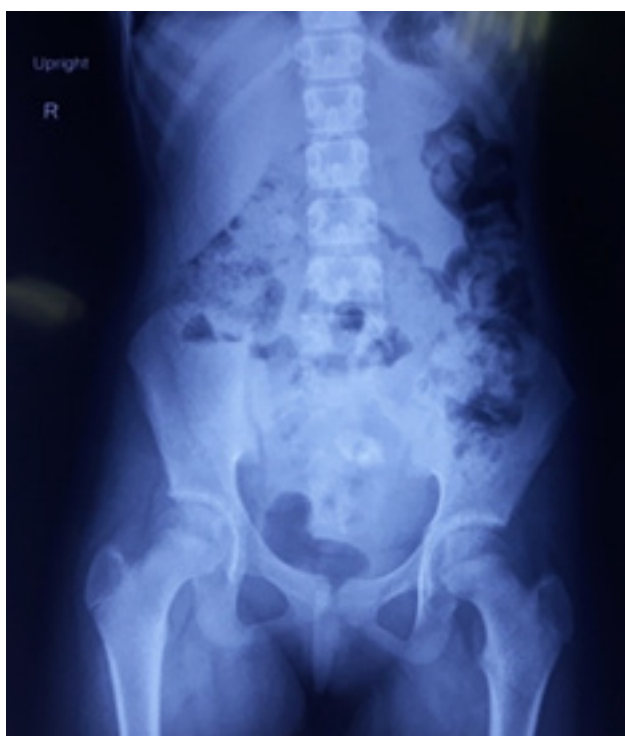An eight years old girl was admitted in emergency in last week of June this year, with complaint of lower abdominal

pain for last 2 days, which was severe, intermittent and colicky in nature. The pain was not relieved by analgesics. There were no associated complaints like nausea, vomiting, fever, dysuria or diarrhea. Patient has not achieved menarche and did not have any other gynecological symptoms.

On general examination the patient was alert, oriented and mildly dehydrated. She was of average build and nutrition. There was mild pallor. On admission her vitals were pulse 110 /min, BP was 90/60 mm of Hg and respiratory rate was 24 breaths/ min. She was afebrile and SpO<sub>2</sub> was 98%. On palpation of the abdomen there was tenderness present in lower abdomen, there was a lump of size approximately 11x15 cm in right lower quadrant and hypogastric reaching upto umbilicus. The mobility of mass could not be assessed due to tenderness and guarding however there was no rebound tenderness. Rest of the systemic examination was

unremarkable. A provisional diagnosis of acute abdomen was made with a differential diagnosis of acute ovarian torsion, appendicular perforation with lump, Meckel's diverticulitis and ileocecal mass.

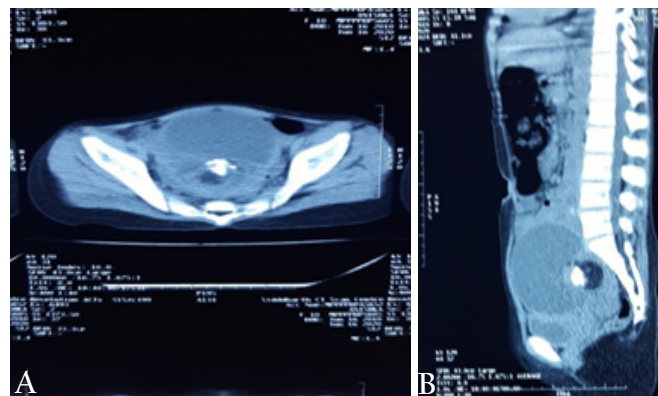
She was admitted, analgesics were administered and she underwent hematological and imaging investigations. Her routine hematological investigations returned normal except her hemoglobin level was 8.5 gm/dl. On admission abdominal X-ray revealed large soft tissue shadow with calcification in the pelvic region. (fig. 1) On ultrasonography examination of abdomen and pelvis-there was a well defined large solid cystic mass lesion noted in pelvis of size approximately 9.7×6.7×7.1 cm containing hyperechogenic areas and heterogeneous hypoechoic areas with mild internal vascularity within the solid part of the lesion.



**Figure 1.** Plain abdominal radiograph showing calcification

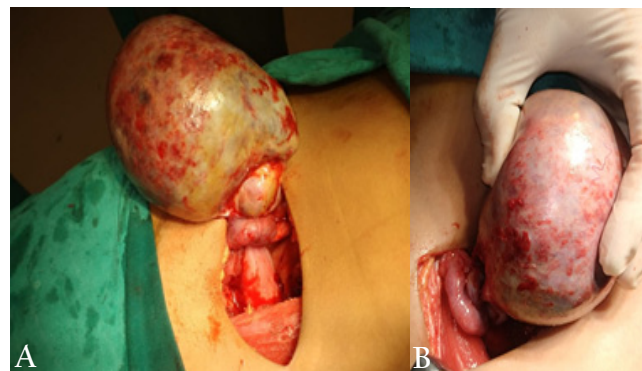
The mass was abutting the posterior wall of uterus and displacing it antero-inferiorly. Also there was hypoechoic area containing follicles noted within the lesion-possibly left ovary. Right ovary was not visualized separately. CT scan of abdomen and pelvis showed large well defined hypodense cystic lesion with areas of fat density and calcific densities within measuring 11×9×8 cm in pelvis in midline, lesion was causing compression over rectum posteriorly and uterus and urinary bladder anteriorly. Both ovaries were not seen separately suggestive of ovarian dermoid cyst. (fig. 2) A provisional diagnosis of ovarian dermoid with suspected torsion was made and tumour markers were sent which returned with values as AFP-1.19 ng/ml,  $\beta$ hCG-1.20 mIU/ml and LDH-451 U/l.

As an institutional protocol for pre operative work up her RT-PCR for SARS CoV was done which was negative. After



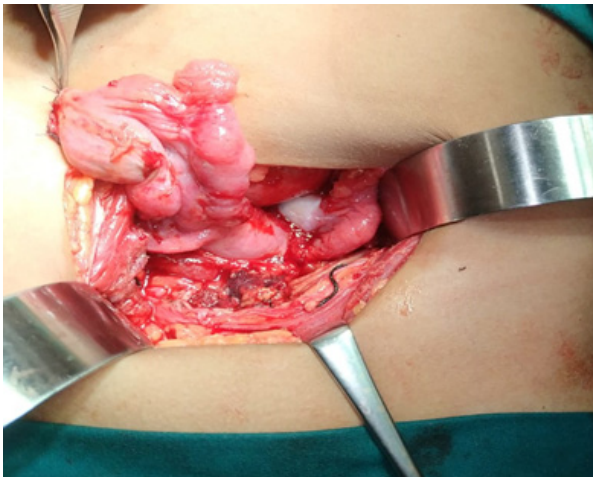
**Figure 2.** CT scan of abdomen and pelvis showing (A) large well defined hypodense cystic lesion measuring 11×9 ×8 cm in pelvis with areas of fat density and calcific densities (B) causing compression over rectum posteriorly and uterus and urinary bladder anteriorly.

taking informed consent from the parents the patient was taken up for exploratory laparotomy through Pfannenstiel incision which revealed an enlarged, congested right twisted ovarian cyst, the greater omentum was found wrapped all around the cyst and part of urinary bladder. Right ovarian cystectomy was performed and part of the omentum around the cyst was excised, preserving the right ovary. (fig. 3 and 4) Left sided ovary was examined and was found to be normal. The abdomen was closed in layers without drain. Postoperatively, intravenous fluids, and antibiotics were given and adequate analgesia was ensured. Patient was allowed orally on post operative day one and tolerated full oral diet. The patient recovered well from the surgery and was allowed home on the fifth postoperative day. On follow-up after one month the patients was doing well.



**Figure 3.** Operative photograph showing torsion of the right ovary (arrow) along with the cyst (A), change in color of the cyst after detorsion (B).

Peritoneal fluid analysis showed cellular tissue and revealed predominantly lymphocytes with reactive mesothelial cells, macrophages and few neutrophils against a proteinaceous background admixed with RBC. No atypical cells or malignant cells were seen. On gross examination of the specimen a congested dusky cyst of size 8×4×2 cm filled with areas of calcification, hair, cheesy material was present. Histopathological examination revealed presence of fibrocollagenous wall and ectodermal and mesodermal components with keratinous debris and hairshaft. No



**Figure 4.** Operative photograph showing preserved right ovary after cystectomy with normal left ovary.

evidence of immature elements seen, consistent with the diagnosis of mature cystic teratoma-dermoid cyst.

## DISCUSSION

As we intent to publish this report, the SARS-CoV2 virus continues to spread around the globe, and cases of COVID-19 continue to rise. Preventing SARS-CoV-2 infection and giving the necessary treatment should be the main principle for treating children with pediatric surgical diseases. However, the outbreak may last for months, for urgent and some “time-sensitive” diseases, undue delay in surgery may miss the “critical window” for intervention, which may compromise the children’s life. In India, although the medical resources are relatively insufficient at the height of this epidemic, separating the non-infected from infected patients is a very effective way to reduce the risk of cross-infection, and to make the treatment timely and safe. We should not suspend the necessary pediatric surgical treatment indefinitely for fear of infection.

Ovarian torsion is defined as partial or complete rotation of the ovarian vascular pedicle causing obstruction to venous outflow and arterial inflow.<sup>1</sup> The dilemma in the diagnosis of ovarian torsion is due to the relative rarity of the condition as the incidence, is 2-3%, especially in children, as well as to the non-specificity of the symptoms and the other varied etiologies that take precedence over ovarian torsion in children. Recent literature strongly recommends ovarian preservation for pediatric patients with ovarian torsion. The mechanism of torsion in women and young girls with ovarian masses is likely related to the increased size and weight of the involved ovary.<sup>2</sup> Ovarian torsion is most commonly associated with benign pathology and the torsion of the right ovary is more common than the left, probably due to presence of sigmoid on left and longer right ligament of ovary.<sup>3,4</sup> In literature dermoid cysts are the most common ovarian cysts in children and adolescents.<sup>5,7</sup>

Most commonly, ovarian torsion occurs with the torsion of fallopian tube as they share the same vascular pedicle.<sup>6-8</sup> Data suggest that nausea and vomiting more commonly occur in pre-menarchal patients and these symptoms are more commonly reported in pediatric and adolescent patients with torsion than in those with an ovarian cyst alone.<sup>9</sup> The risk of torsion increases when pelvic masses exceed 5 cm.<sup>10</sup> Ultrasound is the gold standard imaging choice for acute torsion because of the ability to directly and rapidly evaluate ovarian anatomy and perfusion in a noninvasive manner.<sup>11</sup> While CT may be useful in diagnosing ovarian torsion its utility in discerning abdominal versus gynecological pathology is good.<sup>12</sup> When computed tomography imaging suggests torsion, surgery should not be delayed.<sup>13</sup> Laparoscopy is the standard treatment of ovarian dermoid cysts and provides many advantages over laparotomy. However, laparoscopic approach could result in chemical peritonitis caused by the spilled contents of a ruptured dermoid cyst.<sup>14</sup> The maximum cyst size above which laparotomy should be considered is controversial. Some investigators recommended laparotomy for mature cystic teratoma >10 cm.<sup>15</sup> Previously, the management of ovarian torsion entailed resection of the total ovary without attempting detorsion. This was because it was thought that a hemorrhagic ovary epitomized nonviable tissue and that attempting a simple detorsion may lead to thromboembolism. Another issue was the possibility of leaving a malignancy in situ. Over the last two decades however, a more conservative and hence favorable approach has been in vogue, consisting of detorsion with or without cystectomy. The evidence regarding laparoscopy is very limited and of low quality. There is no contraindication to the use of laparoscopy in COVID-19 positive patients, but all studies recognizes the risk of aerosolization of viral particles during CO<sub>2</sub> insufflation.<sup>16,17</sup> In our setup the facility for laparoscopic surgery is not readily available due to ongoing crisis of manpower and resources following COVID pandemic. Our patient underwent laparotomy with cystectomy and ovary was spared. With regard to the contralateral ovary, the concept of attempting oophoropexy is debatable, but has often been considered in cases of recurrent torsion.<sup>18</sup> Although traditionally it was thought that oophorectomy was usually invariably needed, a more conservative approach is advocated for in recent literature.<sup>19</sup>

## CONCLUSION

Ovarian torsion is a rare cause of abdominal pain in the pediatric populace and may result in infarction of the ovary and fallopian tube. It must definitely be considered in any girl with acute onset lower abdominal pain. Timely diagnostic imaging and surgical intervention can go a long way in preventing the catastrophic complications of ovarian torsion.

## REFERENCES

1. Mashiach R, Melamed N, Gilad N, Ben-Shitrit G, Meizner I. Sonographic diagnosis of ovarian torsion: accuracy and predictive factors. *J Ultrasound Med.* 2011;30:1205-10.
2. Ngo A, Otjen JP, Parisi MT, Ferguson MR, Otto RK, Stanescu AL. Pediatric ovarian torsion: a pictorial review. *Pediatr Radiol.* 2015; 45: 1845-55.
3. Nair S, Joy S, Nayar J. Five year retrospective case series of adnexal torsion. *J Clin Diagn Res.* 2014;8:9-13.
4. Rossi BV, Ference EH, Zurakowski D, Scholz S, Feins NR, Chow JS, et al. The clinical presentation and surgical management of adnexal torsion in the pediatric and adolescent population. *J Pediatr Adolesc Gynecol.* 2012;25:109-13.
5. Outwater EK, Siegelman ES, Hunt JL. Ovarian teratomas: tumor types and imaging characteristics. *Radiographics.* 2001;21:475-90.
6. Argenta PA, Yeagley TJ, Ott G, Sondheimer S. "Torsion of the uterine adnexa: pathologic correlations and current management trends. *J Reprod Med.* 2000;45:831-6.
7. Cass DL, Hawkins E, Brandt ML, Chintagumpala M, Bloss RS, Milewicz AL, et al. Surgery for ovarian masses in infants, children, and adolescents: 102 consecutive patients treated in a 15-year period. *J Pediatr Surg.* 2001;36:693-9.
8. Nichols DH, Julian PJ. Torsion of the adnexa. *Clin Obstet Gynecol.* 1985;28:375-80.
9. Herman HG, Shalev A, Ginat S, Kerner R, Keidar R, Bar J, et al. Clinical characteristics of adnexal torsion in premenarchal patients. *Arch Gynecol Obstet.* 2016;293:603-8.
10. Oltmann SC, Fischer A, Barber R, Huang R, Hicks B, Garcia N. Cannot exclude torsion—a 15-year review. *J Pediatr Surg.* 2009;44:1212-6.
11. Ssi-Yan-Kai G, Rivain AL, Trichot C, Morcelet M, Prevot S, Deffieux X et al. What every radiologist should know about adnexal torsion. *Emerg Radiol.* 2018; 25: 51.
12. Gittleman AM, Price AP, Goffner L, Katz DS, "Ovarian torsion: CT findings in a child. *J Pediatr Surg.* 2004;39:1270-72.
13. Swenson DW, Lourenco AP, Beaudoin FL, Grand DJ, Killelea AG, McGregor AJ. Ovarian torsion: case-control study comparing the sensitivity and specificity of ultrasonography and computed tomography for diagnosis in the emergency department. *Eur J Radiol.* 2014;83:733-8.
14. Clement D, Barranger E, Benchimol Y, Uzan S. Chemical peritonitis: a rare complication of an iatrogenic ovarian dermoid cyst rupture. *Surg Endosc.* 2003;17:658.
15. Chang CK, Teng SW, Leu FJ. Laparoscopy versus laparotomy for cystic ovarian teratomas. *Inter J Gynec Obstet.* 2005;88:69-70.
16. Spinelli A, Pellino G. COVID-19 pandemic: perspectives on an unfolding crisis. *Br J Surg.* 2020; 107: 785-7.
17. Zheng MH, Boni L, Fingerhut A. Minimally invasive surgery and the novel coronavirus outbreak: lessons learned in China and Italy. *Ann Surg.* 2020;72:e5-e6.
18. Poonai N, Poonai C, Lim R, Lynch T. Pediatric ovarian torsion: case series and review of the literature. *Can J Surg.* 2013;56:103-8. doi: 10.1503/cjs.013311.
19. Celik A, Ergün O, Aldemir H, Ozcan C, Ozok G, Erdener A, et al. Long-term results of conservative management of adnexal torsion in children. *J Pediatr Surg.* 2005;40:704-8.