

Unusually large prostatic utricle cyst

Paudel K¹, Kumar A²

¹Postgraduate, ²Associate Professor, Department of Radio diagnosis and Imaging, Kasturba Medical College Hospital, Attavar, Mangalore-575001, Karnataka, India

Abstract

Prostatic utricle cyst is one of the uncommon conditions and only a few cases have been reported. We present a case of unusually large prostatic utricle cyst in a 13- year- old male. He presented with burning urination and post-void dribbling of urine. A cystic mass was felt on digital per rectal examination. Ultrasound pelvis revealed a well-defined midline cystic mass posterior to the urinary bladder. Subsequent magnetic resonance imaging (MRI) of the pelvis demonstrated fluid containing cystic lesion communicating with posterior urethra. Surgical resection of the cyst was performed through the posterior sagittal approach. Follow up of the patient after three months of operation, there was complete resolution of the symptoms.

Key words: Prostatic utricle cyst, MRI, Ultrasound

Prostatic utricle cyst results from incomplete regression of mullerian duct structure in the male prostatic urethra producing a cystic structure of variable size that persists in the midline between the urinary bladder and the rectum¹. In the male fetus, secretion of mullerian regression factor by the testes causes involution of the mullerian system

So that only vestigial structures persists. The cephalic aspect of the mullerian system persists as the appendix of testis and the caudal aspect remains as the prostatic utricle. It occurs most frequently in males with perineal or penoscrotal hypospadias¹. Prostatic utricle cyst is an uncommon condition and only a few cases have been described in the literature.

Case report

A 13- year- old male presented with burning urination and post-void dribbling of urine. He had history of penoscrotal hypospadias. There was no history of fever or trauma to the pelvis. Clinical examination revealed a well nourished male with normal vital signs. His abdomen was soft, non-tender and no evidence of organomegaly on palpation. Bilateral testes were in

the scrotal sacs. A cystic mass was felt on digital per rectal examination. Urine routine examination revealed significant pus cells. Ultrasound pelvis with full bladder was performed, which revealed a well-defined midline anechoic cystic mass posterior to the urinary bladder (Fig 1). No internal flow was seen on colour doppler study. Subsequent magnetic resonance imaging (MRI) of the pelvis demonstrated sharply marginated lesion measuring 11.5 cm in cranio-caudal dimension and 4.4cm in antero-posterior dimension with high signal intensity in T2 weighted images [Fig 2] and low signal intensity in T1 weighted images [Fig 3] suggesting fluid content within it. No abnormal enhancement was identified on post-contrast images. It was appeared to communicate with the posterior urethra. Complete excision of the cyst was performed through the posterior sagittal approach with lateral mobilization of the rectum and subsequent histopathological examination revealed prostatic utricle cyst. There were no complications during the surgery and postoperative period. Complete resolution of the pre-operative symptoms noted on follow up of the patient after three month of surgery.

Correspondence

Dr. Kalyan Paudel
Department of Radio-diagnosis and Imaging,
KMC Hospital, Mangalore-575001, India
E-mail: paudel6@gmail.com

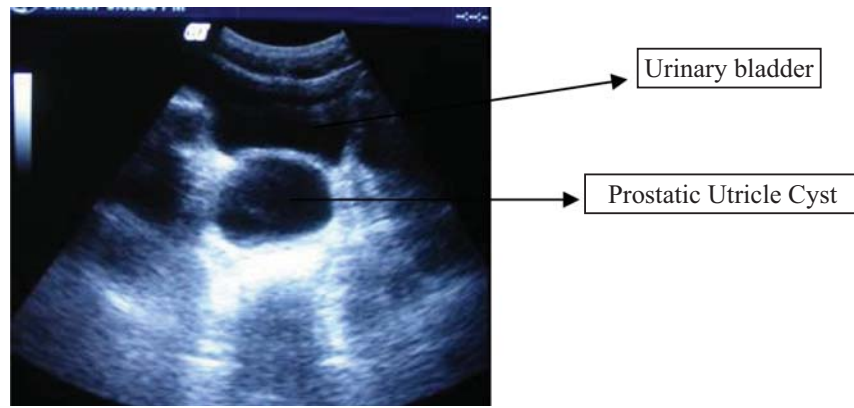


Fig 1: Ultrasound pelvis reveals a large anechoic cystic lesion posterior to the urinary bladder.

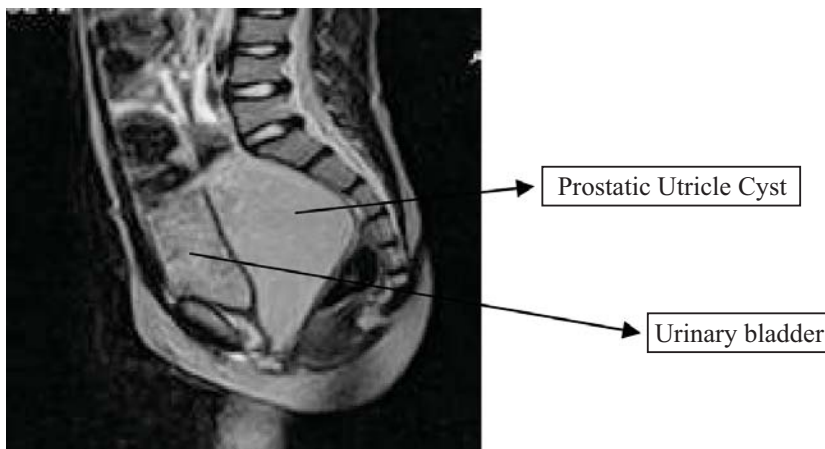


Fig 2: Sagittal T2 weighted MR image demonstrating a sharply marginated, large cystic lesion behind the urinary bladder.

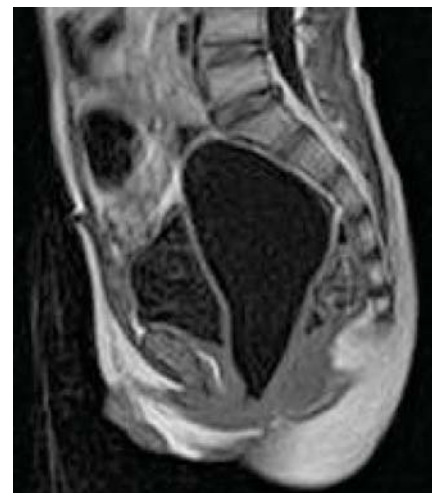


Fig 3: Sagittal T1 weighted MR image showing a well-defined, hypointense lesion posterior to urinary bladder and anterior to the rectum.

Discussion

Prostatic utricle is a small vestigial diverticulum on the posterior surface of the prostatic urethra². In males with ambiguous genitalia, it may form a large diverticulum that protrudes from the posterior side of the prostate. Incidence of prostatic utricle cyst is increased in children born with penoscrotal or perineal hypospadias, undescended testis and unilateral renal agenesis. In our patient, penoscrotal hypospadias was present.

Presence of a utricle cyst can cause lower urinary tract irritative or obstructive symptoms, epididymitis, hematuria, urinary incontinence, oligospermia, constipation, pyuria or abnormal abdominal mass. Dr. Schwartz and Co. had reported four cases of midline prostatic cysts, among them two were asymptomatic, with one case detected on physical examination and one found incidentally on computed tomography (CT)³. Urine may pool in utricle cyst since it communicates

with the urethra, occasionally resulting in the distinctive feature of post-void dribbling. In our patient, post-void dribbling was present.

Ultrasound demonstrates the cystic fluid collection and its relation to the adjacent organs. MRI is valuable imaging modality for evaluation of midline cyst. The excellent soft tissue contrast and multiplaner capability of MRI provide superb depiction of pelvic anatomy, allowing differentiation between entities that can mimic the utricle cyst such as mullerian duct cyst. Sagittal and coronal images are particularly useful in visualizing the location of the cyst in relation to the prostate and urinary bladder.

Differential diagnosis of deep pelvic cysts in the male includes prostatic utricle, mullerian duct cyst, seminal vesicle cyst, urachal cyst and bladder diverticulum.

Urachal cysts occur anterior to the urinary bladder and sagittal MR images will definitely demonstrate their location⁴. The mullerian duct cyst is typically round, large, and often extends above the prostate gland. It is usually not associated with hypospadias or intersex problems and most often is an isolated abnormality⁵. Mullerian duct cyst may obstruct the ejaculatory duct or vas deferens. The prostatic utricle, on the other hand, has been called the homologue of the uterus or the "utricle masculinus." Prostatic utricle cyst is usually found in younger patients and is commonly associated with hypospadias or intersex problems whereas mullerian duct cyst is usually seen in young adults (third or fourth decade)⁶. Utricle cyst and mullerian duct cyst both occur in the midline, however, the utricle cyst communicates with the posterior urethra whereas mullerian duct cyst is connected to the verumontanum by a thin stalk⁷. In utricle cyst, communication with the prostatic urethra is common and spermatozoa may be present whereas mullerian duct cyst never contains sperm⁸.

Cysts of the seminal vesicle are rare congenital disorders, usually associated with anomalies of the kidney or mesonephric ducts. Most seminal vesicle cysts are less than five cm in diameter. The diagnosis is definitive if one normal seminal vesicle is seen and other seminal vesicle is absent in association with a thick-walled ipsilateral cystic structure. MRI shows cyst arising from the region of the seminal vesicles. Because of its increased signal intensity relative to the bladder on the T1 - and T2-weighted sequences, the collection was thought to contain complex proteinaceous fluid and/or some old blood products⁹.

Various techniques have been described for surgical treatment of the prostatic utricle cyst including transurethral de-roofing, endoscopic incision or surgical excision¹. Surgical excision can be performed by suprapubic, perineal or midline transvesical approaches⁶. The posterior sagittal approach with lateral mobilization of the rectum is suited for medium size utricle cysts resection¹⁰. Laparoscopic excision of the cyst is safe and viable alternative to open procedures in the surgical treatment of symptomatic utricle cysts in childhood¹. A resectoscope with a bulb electrode or a cystoscope with a Bugby electrode was used to fulgurate circumferentially the dilated utricle. After fulguration a Councill catheter was placed in the lesion for three to five days and urine was diverted via a suprapubic tube for two to three weeks¹¹.

Conclusion

Prostatic utricle cyst is an uncommon midline cystic lesion between the urinary bladder and the rectum commonly associated with hypospadias. Ultrasound is

usually the initial modality of investigation that may show anechoic cystic lesion posterior to the urinary bladder. MRI is very useful to depict the lesion in relation to the adjacent organs as well as to show the communication of the lesion with the prostatic urethra. In addition MRI is also modality of choice to differentiate utricle cyst from other midline cystic lesions of the pelvis. Prostatic utricle cyst can be managed by surgical or endoscopic excision of cyst or transurethral de-roofing.

References

1. Willetts IE, Roberts JP, Mac Kinnon AE. Laparoscopic excision of a prostatic utricle in a child. *Pediatric Surgery International* 2003;7:557-8.
2. Njeh M, Mnif J, Bahloul A, Kessentini S, Triki A, Mhiri MN. The pathological prostatic utricle: two case reports. *Prog Urol* 1997;7:281-5.
3. Schwartz JM, Bosniak MA, Hulnick DH, Megibow AJ, Raghavendra BN. Computed tomography of midline cysts of the prostate. *J Comput Assist Tomogr* 1998;12:215-8.
4. Rosen L, Hoddick WK, Hricak H, Lue TF. Urachal carcinoma. *Urol Radiol* 1985;7:174-7.
5. Ardill RH, Manivel JC, Hanratty SB, Ercole C, Letourneau JG. Epididymitis associated with mullerian duct cyst and calculus: sonographic diagnosis. *AJR* 1990;155:91-2.
6. Coppens L, Bonnet P, Andrienne R, De Leval J. Adult mullerian duct or utricle cyst : clinical significance and therapeutic management of 65 cases. *J Urol* 2002; 167:1740-4.
7. Dermott Mc VG, Meakem TJ, Stolpen AH, Schnell MD. Prostatic and periprostatic cysts: findings on MR imaging. *AJR* 1995;164:123-7.
8. Chang SG, Hwang IC, Lee JH, Park YK, Lim JW. Infravesical obstruction due to benign intraurethral prostatic cyst. *J Korean Med Sci* 2003;18:125-6.
9. Kneeland JB, Auh YH, Mc Carron JP, et al. Computed tomography sonography, vesiculography and MR imaging of a seminal vesicle cyst. *J Comput Assist Tomogr* 1985;9:964-6.
10. Siegel JF, Brock WA, Pena A. Transrectal posterior sagittal approach to prostatic utricle. *J Urol* 1995;153:785-7.
11. Husmann DA, Allen TD. Endoscopic management of infected enlarged prostatic utricles and remnants of rectourethral fistula tracts of high imperforate anus. *The Journal of Urology* 1997;157:1902-6.