

Chondrolipoma of tongue

Goel G¹, Khadilkar UN², Kumar S³

¹Resident, ²Professor, ³Assistant Professor, Department of Pathology, Kasturba Medical College, Mangalore, Karnataka, India

Abstract

Although lipomas can occur in any part of the body, they are found infrequently in the oral cavity. Variants of lipoma have been described according to the type of tissue present; a lipoma with cartilaginous metaplasia is a chondrolipoma which is a rare variant. We describe a chondrolipoma of tongue in a 36 year old lady.

Key words: Tongue, Chondrolipoma

Lipomas are benign, circumscribed, expansile connective tissue neoplasms predominantly composed of mature white fat cells. They may occasionally exhibit variable amounts of other mesenchymal elements such as fibrous connective tissue (fibrolipoma) and mucoid substances (myxoid lipoma). Exceptionally in lipomas of large size and long duration, cartilaginous metaplasia may occur (chondrolipoma)¹. Lingual chondrolipoma was first described in 1989². Since then only six cases of chondrolipoma have been reported in the oral cavity³.

Case report

A 36 year old lady presented with a painless mass on the right lateral border of tongue since childhood. She noticed an increase in the size of the mass over the past few months, associated with mild difficulty in swallowing. A wide surgical excision of the lesion was done.

Grossly, the lesion was an oval, well circumscribed nodule measuring 3×2×1 cm³. The overlying mucosa was normal. The cut surface was grayish white to yellow and the excision was complete.

Microscopically, the tumor was composed of palisaded lobules of mature cartilaginous tissue admixed with a few lobules of mature adipocytes and dilated congested vessels in the center. (Fig. 1 & 2) A peripheral rim of mature adipose tissue was also seen. The cartilage cells did not show any mitosis. There was no histological evidence of malignancy in the studied sections. The surgical margins were free of tumor and the lesion did not recur after a follow up period of one year.

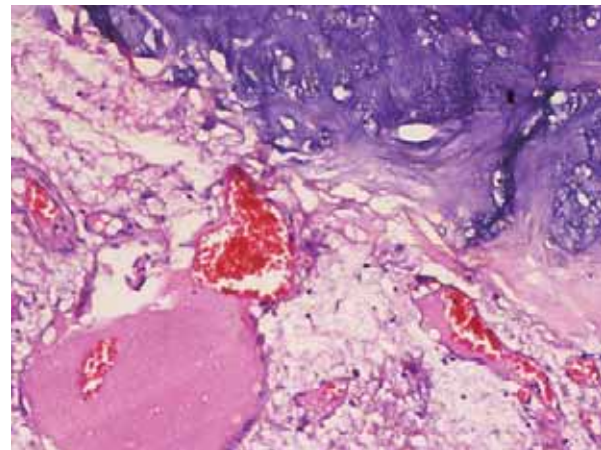


Fig 1: Lobules of cartilage with intervening adipose tissue

Correspondence

Dr. Suneet Kumar
Assistant Professor
Department of Pathology
Kasturba Medical College
Mangalore, Karnataka, India
E-mail: suneet302@yahoo.com

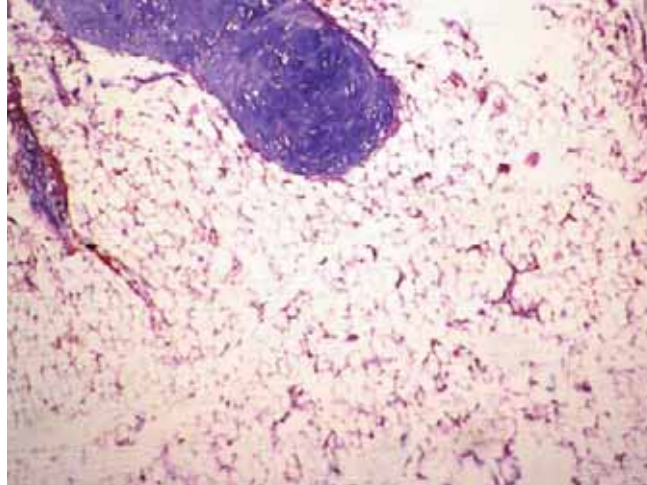


Fig 2: Dilated blood vessel in the center surrounded by cartilage & rim of adipose tissue

Discussion

Chondrolipoma is rather a rare tumor, usually occurring in the periosteum. Whereas chondromas and lipomas of the tongue have been reported, the first lingual tumor with both differentiations, chondrolipoma or lipochondroma was reported in 1989 in a 47-year old male who presented with a firm mass less than 1cm in diameter at the lateral border of tongue².

The peak incidence of lipomas is during the fifth and sixth decade of life and they usually occur singly. Lipomas that contain either fibrous or chondroid metaplasia have been seen in the nasopharynx, tongue, esophagus and hypopharynx. The structure and function of some fully modulated mesenchymal cells can change with altered systemic or local influences such as metabolic, mechanical (trauma, friction) and/ or circulatory; prolonged ischemia may lead to infarction, hemorrhage and calcification^{4, 5}.

Well documented examples of intraoral benign mesenchymoma have been reported in the oral cavity and the patients ranged from two months to 38 years of age. The lesions were unencapsulated, composed of fibrous tissue interspersed with at least two other mature mesenchymal tissues; no single mesenchymal element was predominant and there was no cellular pleomorphism or mitotic activity. According to Bures and Barnes, a benign mesenchymoma may represent a hamartoma if the lesion occurs in an individual younger than 25 years, associated with other congenital anomalies or hamartomatous lesions or with a phacomatosis. To avoid confusion, the term benign mesenchymoma should not be used strictly to describe an unencapsulated neoplasm composed of two or more mature mesenchymal tissues not ordinarily associated

with each other, excluding fibrous connective tissue. Conversely, if a soft tissue neoplasm is well demarcated or encapsulated and composed predominantly of a single mesenchymal tissue, combined with one or more secondary mesenchymal tissues, the diagnosis should reflect the predominant mesenchymal tissue present⁶.

In the present study, the lesion showed features of submucosal lipoma with chondroid metaplasia and was designated as chondrolipoma.

There are several theories as to the origin of the tumor. Firstly, it may be a choristoma possibly arising from pluripotent mesenchymal cells sequestered during embryogenesis; normally no cartilage is found in the tongue. Another possibility is that the lipoma or chondroma component is a form of metaplastic stromal reaction, due to trauma². Katzer hypothesized from histological observations that cartilage could be developmentally produced in small nodules of fibrous tissue with myxoid and chondroid change by mechanical causes³. This hypothesis may be supported by the histopathologic findings in our case in which the cartilage showed a garland like shape and had some spaces, suggesting that several small nodules of chondroid substance were growing together and had undergone partial fusion.

A chondrolipoma must be distinguished from a chondroid lipoma which exhibits features of both a lipoma and a hibernoma⁷.

Excision is the treatment of choice and no recurrences have been reported¹.

Conclusion

To conclude, chondrolipoma of tongue is a rare entity with a debated histological origin having features of submucosal lipoma and chondroid metaplasia. These tumors are amenable to excision and do not recur.

References

1. Nwaorgu OGB, Akang EEU, Nwachokor FN. Pharyngeal lipoma with cartilaginous metaplasia (chondrolipoma): A case report and literature review. *J Laryngol Otol* 1997;111:656-8.
2. Maes A, Eulderink F. Chondrolipoma of the tongue. *Histopathology* 1989;14:660-2.
3. Fujimara N, Enomoto S. Lipoma of the tongue with cartilaginous change: A case report and review of the literature. *J Oral Maxillofac Surg* 1992;50:1015-7.
4. Piattelli A, Fioroni M, Iezzi G, Rubini C. Osteolipoma of tongue. *Oral oncology* 2001;37:468-70.
5. Hietanen J, Makinen J. Chondrolipoma of the tongue: A case report. *Int J Oral Maxillofac Surg* 1997;26:127-8.
6. Jones AC, Trocheset D, Freedman PD. Intraoral benign mesenchymoma: A report of 10 cases and review of the literature. *Oral Surg Oral Med Oral Pathol* 2003;95(1):67-76.
7. Halaas YP, Mra Z, Edelman M. Chondrolipoma of the oropharynx. *Ear Nose Throat J* 2001;80:146-7.