

Pompe Disease: Cyanosed Hypotonic Infant with Normal Respiratory Rate

Koirala S, Poudel A, Basnet R, Subedi K

Department of Paediatrics

Kathmandu Medical College

Sinamangal, Kathmandu

Corresponding Author

Satish Koirala

Department of Paediatrics

Kathmandu Medical College

Sinamangal, Kathmandu

Email: Skoirala_2009@hotmail.com

Citation

Koirala S, Poudel A, Basnet R, Subedi K. Pompe Disease: Cyanosed Hypotonic Infant with Normal Respiratory Rate. *Kathmandu Univ Med J* 2015;50(2):172-4.

ABSTRACT

Infantile hypotonia or floppy infant is a diagnostic challenge when it presents with other presenting complaints such as fever, cough or diarrhea. Many times the hypotonia goes unnoticed when other symptom covers the hypotonia and child continues to receive the treatment for other symptoms. We report a rare case from Nepal of infantile Pompe disease who presented with the history of fever and cough in the recent earthquake disaster camp at remote part of Sindhupalchowk, Nepal. He was being treated as a case of pneumonia.

Pompe disease can be diagnosed clinically by taking detailed history and correlating the clinical findings during the presentation with other symptoms. In our case the normal respiratory rate, reduced SpO₂ and presence of crackles dominated the hypotonia and was mistreated as pneumonia. High index of suspicion is necessary in diagnosing Pompe disease.

KEY WORDS

Developmental delay, hypertrophic cardiomyopathy, hypotonia, normal respiratory rate, pompe disease

INTRODUCTION

Pompe disease is a lysosomal glycogen storage disease (GSD II) characterized by deficiency of alpha glucosidase enzyme activity leading to excessive accumulation of glycogen in multiple organs, especially in cardiac and skeletal muscle. It has phenotype heterogeneity depending on the age of presentation, organ system involvement, degree of enzymatic activity and subsequent rate of progression.¹ It has an autosomal recessive inheritance pattern with the defective gene site localized to chromosome 17_q25.2-25.3.² It has predicted incidence of 1:40,000.³

CASE-REPORT

A 5 months-old male infant was examined in the earthquake disaster health camp at Sindhupalchowk for fever, cough and difficulty in breathing. Due to presence of fever, cough and bilateral crackles in the chest, he was treated as

pneumonia with ceftriaxone at the camp site. Later he was referred to KMC hospital for further management as severe pneumonia with impending respiratory failure.

Further history revealed a home delivered full-term, appropriate for gestational age baby from consanguineous marriage, with uneventful antenatal and neonatal period. Exclusively breastfed, floppiness was noticed from the second month of age and the baby was not able to hold his neck even at the presentation. There was no history of rashes, or feeding intolerance. There was no significant family history of cardiac disease, and sudden death. Father was 37 years; mother was 35 years, and both were working as a laborer at Tatopani. His two siblings were girls aged 5 yr and 2 yr; healthy with normal developmental milestones.

He was consuming breast milk and passing urine as usual. On physical examination, his heart rate 135 beats/min; respiratory rate 40 breathe/min, apyrexial, BP 94/62 mm

of Hg. SpO₂ 82 % in ambient air with peri-oral cyanosis. Despite low SpO₂, there was no signs of respiratory distress or tachypnea. Growth parameters are as follows; weight 6.5 kg (Z score -1.3); Length 62cm (Z score -1.7); head circumference 40 cm (Z score -2.5). He was alert and did not appear to be in distress or dehydration. He was unable to lift his head and had considerable head lag while pulling to a sitting position (Fig.1).

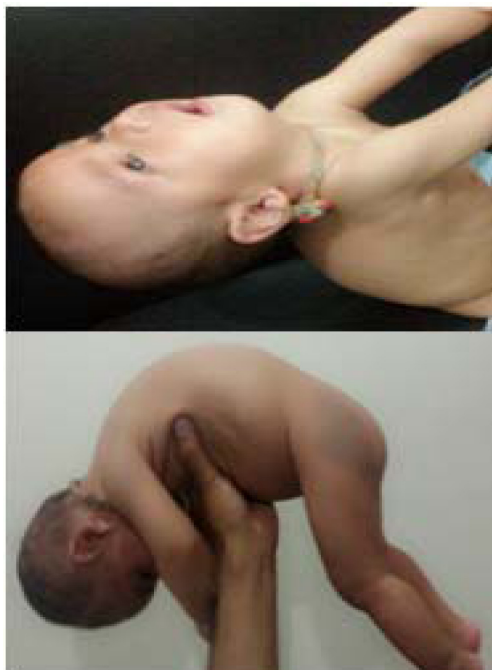

Figure 1. Demonstrating Hypotonic infant.

He had reduced air entry both lungs with conducted sounds without wheeze. Cardiovascular exam revealed normal first and second heart sound with palpable liver 2 cm below the costal margin. There was diffuse hypotonia noted in all four limbs. Neurologically the infant was alert but not playful. Deep tendon reflexes could not be elicited. There was no lymphadenopathy and skin examination was unremarkable. He was kept in oxygen via nasal canula at 1 L/min and the Spo₂ rose to 99 %. Chest X-ray revealed globular heart shadow with normal lung field (Fig 2).

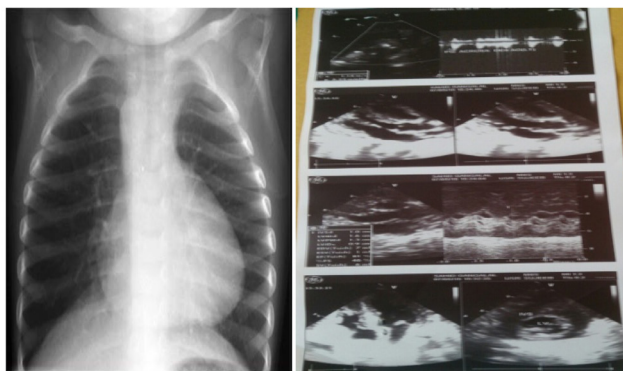


Figure 2. Chest x-ray showing globular heart with normal lung field and Echocardiography suggestive of hypertrophic cardiomyopathy.

A pediatric cardiologist was consulted and the echocardiography revealed as asymmetric hypertrophy of IVS causing small LV cavity, suggestive of Hypertrophic cardiomyopathy. Blood examination was as Table 1. The CPK-NAC was markedly elevated 1033 U/L (Ref. range 24-171 U/L). Quantitative blood alpha-glucosidase level was 13 nmol/nmol/hr/mg, which was markedly deficient (Ref. range Normal activity >60 nmol/hr/mg).

Table 1. Blood investigations

Blood Investigations	Results
Hb	11.6 gm %
TC	9,900/cumm
DC	N30 L 69
Platelets	3,50,000/cumm
Sugar (R)	76 mg/dl
ESR	8
Na/K	137/3.8 mEq/L
Serum Alkaline Phosphatase	329 U/L
CPK-NAC	1033 U/L
LDH	1076 U/L
SPOT/SGPT	172/153 U/L
Ca/Phosphorus	9.7/ 4.1 mg/dl

DISCUSSION

A The child with severe hypotonia and developmental delay presented with fever, cough and difficulty breathing having the spo₂ of 82 % in room air. The differential diagnosis of severe hypotonia is broadly classified as anterior horn cell disorder, congenital motor or sensory neuropathies, neuromuscular junction disorders, congenital muscular dystrophies, and metabolic and multisystem disease.

The presence of high CPK (more than 1000 U /L) limits the differential to predominantly muscular diseases, especially those related with muscle necrosis. Muscular involvement is seen in congenital muscle dystrophy, congenital myotonic dystrophy, and metabolic dystrophy (Pompe and other storage diseases). Cardiac involvement further limits the differential diagnosis to congenital myotonic dystrophy and Pompe disease. It is confirmed by the serum alpha-glucosidase level which was 13 nmol/hr/kg in our case.

Infant with Pompe disease have severe hypotonia and they do not have normal inspiratory drive. As a result the respiratory tract is covered with excessive mucous secreted from the goblet cells. These children cannot expel out which results in conducted sounds and misinterpreted as basal crepitations of lung parenchyma.

Also, they may have low oxygen saturation due to weak ventilatory drive.

Enzyme replacement therapy (ERT) is under study for the treatment of Pompe disease. The recent results with recombinant human alpha-glucosidase are promising. With introduction of ERT, the life span can be extended for few years, though not fully curable.⁴ The best therapeutic results are achieved when ERT is started early in the course of symptom development and before irreversible muscular damage has occurred.⁵

In developing countries where ERT is not available, patients with Infantile Pompe disease usually die within the first year of life due to cardio-respiratory failure. In classic infantile form, onset of symptom is at median age of 1.6 months with the majority of patients dying at the median age of 6 to 7.7 months.⁶

We report a rare case from Nepal of deficient alpha glucosidase enzyme activity.

REFERENCES

1. Kishnani PS, Steiner RD, Bali D, Berger K, Byrne BJ, Case LE, et al. Pompe disease Diagnosis and management guideline. *Genet Med*. 2006; 8(5): 267-268.
2. Kishnani PS, Howell RR. Pompe Disease in infants and children. *J pediatr*. 2004; 144:S35-43.
3. Martiniuk F, Chen A, Mack A, Arvanitopoulos E, Chen Y, Rom WN, et al. Carrier frequency for glycogen storage disease type II in New York and estimates of affected individuals born with the disease. *Am J Med Genet*. 1988 Aug 27;79(1):69-72.
4. Fukuda T, Roberts A, Plotz PH, Raben N. Acid Alpha-Glucosidase Deficiency. *Cur Neur Neurosci Rep*. 2007;7(1):71-77.
5. Kishnani PS, Nicolino M, Voit T, Rogers RC, Tsai AC, Waterson J, et al. Chinese Hamster Ovary Cell-derived Recombinant Human Acid Alpha-Glucosidase in Infantile-Onset Pompe Disease. *J Pediatr*. 2006; 149(1):89-97.
6. van den Hout HM, Hop W, van Diggelen OP, Smeitink JA, Smit GP, Poll-The BT, Bakker HD, et al. The Natural course of Infantile Pompe's Disease: 20 original cases compared with 133 cases from the literature. *Pediatrics*. 2003; 112:332-40.