

Study to Compare and Evaluate Traditional vs. Endoscopic Septoplasty

Shrestha I, Pokharel M, Dhakal A, Amatya RCM

Department of ENT, Head & Neck surgery

Dhulikhel Hospital, Kathmandu University School of Medical Sciences (KUSMS),

Dhulikhel, Kavre, Nepal

Corresponding Author

Inku Shrestha

Department of ENT, Head & Neck Surgery

Dhulikhel Hospital, Kathmandu University School of Medical Sciences (KUSMS)

Dhulikhel, Kavre, Nepal

E-mail: shresthainku@gmail.com

Citation

Shrestha I, Pokharel M, Dhakal A, Amatya RCM. Study to Compare and Evaluate Traditional vs. Endoscopic Septoplasty. *Kathmandu Univ Med J* 2015;50(2): 109-14.

ABSTRACT

Background

Surgery on a deviated septum has seen several modifications since its inception starting from radical septal resection to preservation of the possible septal framework.

Objective

To compare the efficacies of "Endoscope Septoplasty" over "Traditional Septoplasty" in treating pathological septum and turbinates, in terms of their outcome.

Method

Prospective descriptive study conducted on 60 patients who presented to the Department of ENT, Kathmandu University School of Medical sciences during a period of two years. The severity of the symptoms of the patients was scored using a visual analogue scale which was compared post operatively to subjectively evaluate the efficacy of either surgery. Objective assessment was done by nasal endoscopy. P value in case of subjective and objective evaluation was done by applying Z- test.

Result

The mean age \pm SD was 29.5 ± 1.2 . Maximum patients fell into age group of 21-30 with 31.7 % followed by 11-20 with 28.3% and then 31-40 with 25 %. There were total 35 males (58.3%) and 25 females (41.7%). Among the symptoms, nasal obstruction seems to be dominating with total of 83.3%, followed by postnasal drip with 66.6% and then headache with 60%. The types of dislocation was compared, there were 66.7% cases with DNS and Spur whereas only 10 % with isolated spur. C shaped deformity was seen in 30% and S shaped in 26.6 % cases. Significance in Z test, is seen in subjective assessment post surgery for nasal obstruction, headache and rhinorrhea and for objective assessment post surgery for persistent contact with turbinates. (p value set to 0.01)

Conclusion

Endoscopic surgery is an evolutionary step towards solving the problems related to deviated nasal septum. It is safe, effective and conservative alternative to conventional septal surgery.

KEY WORDS

Endoscopic approach, septoplasty.

INTRODUCTION

Septoplasty is one of the most common surgeries among ENT surgeons but even today the difficult septum still presents a great surgical challenge. Surgery on a deviated nasal septum (DNS) has seen several modifications since its inception starting from radical septal resection to mucosal preservation and subsequent preservation of the possible septal framework.¹⁻⁵

Traditional nasal surgery does improve nasal airway, resection rather than conservative surgery is often used. There is often overexposure, unnecessary manipulation of the septal anatomy and more resection. Use of endoscope addresses the above three areas favorably. The nasal endoscope allows precise pre operative identification of the septal pathology and its associated lateral nasal wall abnormalities and helps in better planning of Endoscope Aided Septal surgery (EAS).

Surgery on a deviated nasal septum has changed a lot, starting from radical septal resection to mucosal preservation subsequent preservation of the possible septal framework as the latter gives rise to lesser complications,⁵ allows concomitant rhinoplasty or a revision surgery later and moreover conservative surgery can be safely performed in children.

Aim of the study is to compare the efficacies of the two techniques- "Endoscope aided Septoplasty" over "Traditional Septoplasty" in treating pathological septum and turbinates, in terms of their outcome.

METHODS

This is prospective, analytical study conducted on 60 patients who presented to the Department of ENT, in Dhulikhel hospital, Kathmandu University School of Medical sciences during a period of 2 years from September 2012 to September 2014. Before starting the study, we obtained approval from the Institutional review committee of Dhulikhel hospital.

The patients were carefully randomized attempting the best balance of other variants of the efficacies namely age, sex and type of deformity. These cases were evaluated by brief history taking and thorough clinical examination after written informed consent. Each patient was thoroughly examined with nasal endoscopy (with or without nasal decongestant to enable correct identification of contact areas and turbinate pathology) and findings were recorded. Carl Storz Rigid fiberoptic nasal endoscope of 0 and 30 degrees with Carl Storz light source was used for diagnostic nasal endoscopy and endoscope assisted surgeries. Radiological examination included a plain radiograph of the paranasal sinuses (Water's view) and when affordable, a computed tomography scans with coronal and axial cuts of the osteo meatal complexes. Allergic testing was performed in cases of allergic rhinitis. In both groups, diagnostic nasal

endoscopy was performed, with special reference to identification of the septal and lateral wall deformities and contact areas without usage of a topical decongestant. The cases were taken up for surgery only when found refractory to medical therapy. They were divided into 2 groups, each consisting 30 random patients. The surgery in both groups were performed under GA by surgeons experienced in both type of surgeries.

Inclusion criteria were all cases of symptomatic DNS. Patient excluded were those with uncontrolled chronic medical diseases and those unable to follow up for 3 months post operatively.

In the traditional group, Cottle's Maxilla- Premaxilla Technique 4 or Metzenbaum's technique 2 were followed. In addition, submucous diathermy of the hypertrophic inferior turbinate, inferolateral partial turbinoplasty, and partial posterolateral resection of middle turbinate were performed wherever necessary. Functional Endoscopic sinus surgery (FESS) was done in cases with features of chronic sinusitis. In both groups nasal cavities were packed with antibiotic impregnated Vaseline pack for 48 hours. All patients were under antibiotic cover for one week along with analgesics, antihistaminic and decongestants. The severity of the symptoms of the patients was scored using a visual analogue scale which was compared post operatively to subjectively evaluate the efficacy of either surgery. Objective assessment was done by nasal endoscopy.

P value in case of subjective and objective evaluation was done by applying Z test. P value < 0.01 was accepted as statistically significant.

Methodology of evaluation

Patients were assessed using a Proforma given below. Patients were called for review after 10 days, 1 month, 2 months and 3 months period. During every visit improvement in symptoms were noted. Objective assessment was done by nasal endoscopy.

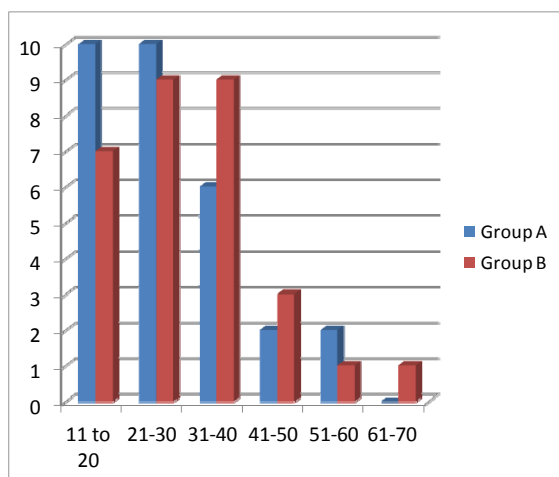
RESULTS

Among total 60 patients, the minimum age was 12 and maximum was 70 with a range of 58 years. The mean age \pm SD was 29.5 ± 1.2 . Maximum patients fell into age group of 21-30 with 31.7 % followed by 11-20 with 28.3% and then 31-40 with 25 %.

Among Group A; the minimum age was 12 years and maximum of 57 years with range of 45 years. The mean age \pm SD was 28 ± 1.21 . Maximum patients fell into the age group of 11-20 and 21-30 with 33.3% in each.

Among Group B; the minimum age was 17 and maximum of 70 years with range of 53 years. The mean age \pm SD was 31 ± 1.2 . Maximum patients fell in to the age group of 21-30 and 31-40 with 30 % in each (Graph 1)

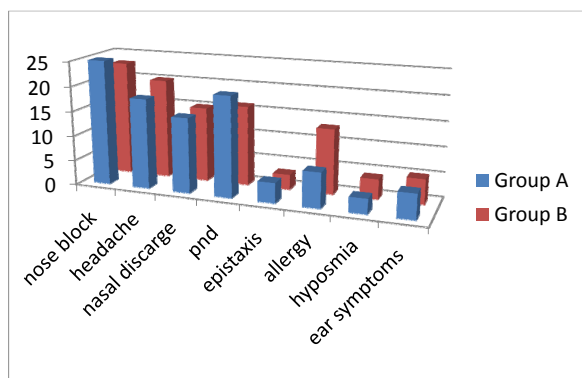
Males and females were of equal numbers with 30 males



Graph 1. Age distribution.

and 30 females with 50 % each. In group A, males were 17 (56.7%) and females (43.3%) where as in group B, males were 13 (43.3%) and females were (56.7%).

Patients presented with various symptoms either single or in combinations. The commonest being nasal block seen in 83.3% in Group A and 76.6% in Group B. Nasal block was followed by headache with 60%in group A and 66.6% in group B and then postnasal drip with 66.6% in group A and 53.3% in group B. Nasal discharge was seen in 50 % cases in both groups. Other symptoms were epistaxis in total 11.6%, allergic symptoms in 33.3%, ear complaints in 16.7 % cases and only 11.6% cases complained of hyposmia. (Graph 2)



Graph 2. Symptomology in both groups.

Regarding the types of septal deviation seen on patients pre-operatively; C shaped deviation was seen in 31.6%, (fig. 1) followed by S shaped in 26.6% and then caudal deviation in 15% and isolated spur in 10%. DNS with spur was seen in 65% cases (fig. 2). Among them the sites of deviation were caudal dislocation in 15%, anterior deviation in 70% and posterior deviation in 40% cases.

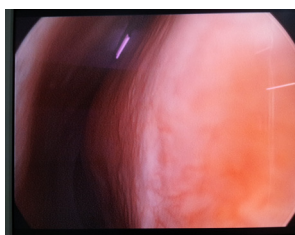


Figure 1. C shaped DNS seen in DNE

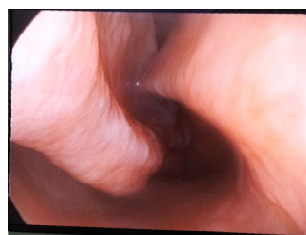

Figure 2. Diagnostic nasal endoscopic (DNE) view showing DNS with spur contacting inferior turbinate.

Chronic rhinosinusitis was the commonest associated condition seen in 46.6% cases followed by allergic rhinitis in 21.6% cases. Others were external deformity (6.7%), Eustachian tube dysfunction (11.6%), nasopalatine cyst (1.6%), obstructive sleep apnoea (3.3%), trauma (8.3%) and recurrent upper respiratory tract infection (18.3%).

Among 30 cases in group A; 7(23.3%) underwent FESS and 15 (50%) underwent bipolar cautery turbinoplasty. Other 30 cases in group B; 12 cases (40%) underwent FESS, 3 cases (10%) inferolateral partial turbinoplasty, 4 cases (13.3%) underwent partial posterolateral resection of middle turbinate (MT), 17 cases (56.6%) underwent bipolar cautery of inferior turbinate and 4 (13.3%) cases underwent bipolar diathermy of polypoidal septal mucosa. (Table 1)

Table 1. Surgical details of cases who underwent EAS (endoscope assisted septoplasty)

Surgical details	Group A N	Group A N %	Group B N	Group B N %
Functional Endoscopic sinus surgery	7	23.3	12	40
Inferolateral partial turbinoplasty	-	-	3	10
Partial posterolateral resection of MT	-	-	4	13.3
Bipolar cautery of IT	15	50	17	56.6
Bipolar /diathermy polypoidal septal mucosa	-	-	4	13.3

Within the cases in Group A, 15 % had relief from headache and 60% had improved headache. Only one patient complained of worsening of headache which may be due to crusting. 20% of patients had relief from nasal obstruction whereas 48% had improved nasal congestion. Three patients still complained of worsening of obstruction which may be due to synechiae formation and crusting. Nasal discharge resolved in 21.4% and was improved in 35.7%. In three cases it was the same and in three cases it worsened which may be due to association with allergic rhinitis. Post nasal drip was resolved, improved and remained same in three cases (33.3%) each. Among two cases of hyposmia one improved and one remained the same. Regarding four cases with ear complaints two resolved and one each improved and remained same. (Table 2)

Table 2. Subjective visual analogue scale- traditional septoplasty

Symptoms	Number	Resolved	Improved	Same	Worse
Headache	20	3(15%)	12(60%)	4(20%)	1(5%)
Nasal Obstruction	25	5(20%)	12(48%)	5(20%)	3(12%)
Rhinorrhoea	14	3(21.4%)	5(35.7%)	3(21.4%)	3(21.4%)
Post Nasal Discharge	9	3(33.3%)	3(33.3%)	3(33.3%)	0
Hyposmia	2	0	1(50%)	1(50%)	0
Ear complaints	4	2(50%)	1(25%)	1(25%)	0

Group B- Among 21 patients who complained of headache only two patients had same symptom and for one patient it worsened. Rest of the patients had either resolved (19%) or improved (66.6%) headache. Similarly for nasal obstruction; majority of the patients had either resolved or improved symptom with 47% each, whereas for only one case condition remained the same. For rhinorrhoea, 78% had either improved or resolved condition but four patients (22%) still complained of similar discharge. Similar symptom scale were shown for post nasal drip with 85.6% cases having improved or resolved discharge, in two cases (9.5%) it remained same and one case had worsening of symptom in the duration. 100% of hyposmia and ear symptoms were either resolved or improved. (Table 3)

Table 3. Subjective visual analogue scale- endoscopic septoplasty

Symptoms	Number	Resolved	Improved	Same	Worse
Headache	21	4(19%)	14(66.6%)	2(9.52%)	1(4.7%)
Nasal Obstruction	21	10(47.6%)	10(47.6%)	1(4.7%)	0
Rhinorrhoea	18	2(11.1%)	12(66.6%)	4(22.2%)	0
Post Nasal Discharge	21	4(19%)	14(66.6%)	2(9.52%)	1(4.7%)
Hyposmia	2	1(50%)	1(50%)	0	0
Ear complaints	4	2(50%)	2(50%)	0	0

Subjective assessment: comparative results of the two surgeries based on symptoms tested by Z test showed significance for headache, nasal obstruction and rhinorrhoea. Significance level was set to p= 0.01. (Table 4)

Table 4. Subjective assessment-comparative results of the two surgeries based on symptoms

Symptoms No of cases T/E	Traditional (n=30)				Endoscopic (n=30)				P value
	Benefitted		Non Benefitted		Benefitted		Non Benefitted		
	R	I	S	W	R	I	S	W	
Headache (20/21)	3	12	4	1	4	14	2	1	<0.01*
Nasal Obstruction (25/21)	5	12	5	3	10	10	1	0	<0.01*
Rhinorrhoea (14/18)	3	5	3	3	2	12	4	0	<0.01*
Post Nasal Discharge (9/21)	3	3	3	0	4	14	2	1	0.23
Hyposmia (2/2)	0	1	1	0	1	1	0	0	0.25
Ear complaints (4/4)	2	1	1	0	2	2	0	0	0.28

*significant Z test.
 T- Traditional E- Endoscopic
 R- Resolved (symptom completely resolved)
 I- Improved (symptom has improved from pre operative state)
 S- Same (Condition of symptom remains same)
 W- Worse (condition of symptom has become worse than in pre-operative state)

Table 5. Table – showing objective endoscopic assessment.

Endoscopic Findings on F/U	Traditional (n=30)		Endoscopic (n=30)		P value
	N	%	N	%	
1. Persistent deformity	11	17.2	3	10	0.0146
Anterior deviation	3	3.3	2	6.7	0.638
Posterior deviation	5	16.6	1	3.3	0.085
Spur	3	10	0	0	0.075
2. Persistent contact with turbinate	5	16.6	1	3.3	0.085
3. Persistent pathology of the turbinates	9	30	0	0	0.001*
4. Others Synechiae	5	16.6	2	6.7	0.226
Tear of Flap	4	13.3	0	0	0.038
Perforation	3	10	0	0	0.075

*significant Z test.

Table 5 depicts the positive findings of the objective assessment of the patients done during the last available follow up using endoscopes which showed significance in Z test for “Persistent pathology of the turbinates” with P value- 0.001.

DISCUSSION

This study shows that surgery in both groups were done in young adults with mean of 28 in group A and 31 in group B. This is comparable to other studies like In Nayak et al study (1998); age group in traditional group ranged from 17-58 years with mean of 28 years and in endoscopic group age ranged from 18-52 years with mean of 24 years.⁶ Nayak et al (2002) study shows age range 6-54 years with mean 26.4 years.⁷ The high incidence in 2nd to 4th decade of age group could be due to the fact that people in their active period of life are more prone to external injuries, hence likely to present with deviated nasal septum and are concerned with their physical status.

Gray (1965), Pease (1969), Jazbi (1974) have extensively studied the factors responsible for deviated nasal septum in early childhood and they believed that prenatal traumatic factors may produce anterior septal dislocation and it becomes pronounced as age advances.⁸⁻¹⁰

Ali DS (1965) reported a low incidence of DNS in younger age group than older. Explanation for this low incidence in age group below 10 years is due to fact that attention was given for development of skeletal framework of nose and surgical intervention was deferred as far as possible.¹¹ Other reason may be that traumatic factors which contribute to produce DNS would not have had their full effect yet in these early years. Another point to be mentioned is that children are largely an uncomplaining population compared to adults.

Males and females were equal in our study where as in Nayak et al study it was 2:1. This equal proportion in our study is due to fact that the incidence is also equal.

In the present study, commonest presenting symptom was nasal obstruction 80% which was followed by headache (63.3%) and postnasal drip 60%. Nasal septal deviation can cause nasal obstruction, headaches, snoring and oral breathing.^{12,13} Nasal congestion was seen in 72% and headache in 46% in the study by Ghazipour Ali in Iran.¹³

Sinonasal headaches are attributed to the presence of contact points between opposite mucosal surfaces in the sinonasal region, such as contacts between the nasal septum and the superior or middle conchae or with inner walls of the ethmoid sinus. These contact points can intensify primary headaches or cause secondary headaches, which have recently been added to the International Classification of Headache Disorders. As defined, these headaches are characterized by frequent localized headaches, particularly in the periorbital region, the inner wall of the eye, and the temporal region, and also in the forehead and the upper jaw, and are accompanied by the presence of contact points in the sinonasal region. The pain is mediated via anterior and posterior ethmoidal nerves.^{14,15}

Endoscopic septoplasty has been described previously in literature.^{6,7,16-19} The rationale for developing endoscopic technique from a traditional headlight approach comes from the fact that during common nasal procedures, the surgeons view is obstructed due to the narrowing caused by septal spurs or deviations.^{17,19}

Endoscopy enables the surgeons to localize the spurs and remove them under direct vision and also has improved fields of view in posterior deviations. Endoscope can be easily passed under septal mucosal flaps, minimal lifting of flap is required to gain excellent visualization. The improvement in critical areas such as nasal valve region can be better assessed during surgery. Incision can be given more posteriorly in the nose immediately anterior to the area of deviation. The extent of mucosal elevation anteriorly in the nose is minimized. Therefore, postoperative edema is reduced. The instruments used in endoscopic septoplasty are similar to endoscopic sinus surgery. This allows for smooth integration of septoplasty to sinus procedure without any awkward exchanges between headlight and endoscope.¹⁶⁻¹⁸

M Milojevic et al. (2014) reports a horrific case of unilateral blindness following traditional septoplasty due to fracture of upper and lateral walls of sphenoid sinus with bony penetration on the optic canal.²⁰

Hwang et al in their retrospective study reported hematoma in 0.9%, asymptomatic perforation in 0.9% and synechiae formation in 4.5 % patients.¹⁷ Sufian Nawaiseh et al in Jordan, reports hemorrhage in one (1.6%) and septal hematoma in one (1.6%) patient.¹⁹ N Prepageran in Malaysia (2010) has no complication to report.²¹

In our study in similarity with study by Nayak et al and Gupta et al. complication rates were significantly more in traditional group.^{6,22}

This study clearly showed more number of patients being relieved of presenting complaints in endoscopic group with statistically significant results in some.

Statistically significant results were seen for headache, nasal obstruction and rhinorrhoea with p value <0.01. In the study by Nayak et al. 1998 EAS was found to be more effective in treating symptoms such as nasal obstruction and headache with p value <0.02 and < 0.05 respectively.

It has also shown difference in objective assessment done via endoscope even though with a single statistically significant result for "Persistent pathology of the turbinates". P value was 0.001.

Our study in overall showed better results and lesser complications in endoscopic septoplasty as compared to traditional septoplasty.

CONCLUSION

Endoscopic septoplasty is fast developing concept and gaining popularity towards the trend towards performing endoscopic surgeries. The primary advantage of this technique is its ability to reduce morbidity as it provides a direct targeted route to the anatomic deformity, improved visualization, and magnification of the surgical field. It also provides significant clinical and excellent teaching tool when used in conjunction with video monitors over traditional approaches.

REFERENCES

1. Freer O. The correction of deflections of the nasal septum with a minimum of traumatism, *Journal of American Medical Association* 1902;38:636.
2. Metzenbaum M. Replacement of lower end of the dislocated cartilage versus submucous resection of the dislocated end of the septal cartilage. *Archives of Otolaryngology*. 1929;(9):282
3. Galloway T. Plastic repair of the deflected nasal septum. *Archives of laryngology*. 1946;(44):141.
4. Cottle MH, Loring RM, Fischer GG, Gaynon IE, et al. The maxilla-premaxilla approach to extensive nasal septum surgery. *AMA Arch Otolaryngol* 1958; 68:301-13.
5. Maran AGD. Septoplasty. *Journal of laryngology and otology*. 1974;88:393-402.
6. Nayak DR, Balakrishnan R, Murthy K. An endoscopic approach to the deviated nasal septum- a preliminary study. *The Journal of Laryngology and Otolaryngology*. 1998;112: 934-9.
7. Nayak DR, Balakrishnan R, Murthy KD, Hazarika P. Endoscopic Septoturboplasty: our update series. *Indian Journal of Otolaryngology and Head and Neck surgery*. March 2002;54:20-24.
8. Gray LP. The deviated nasal septum. I. aetiology. *J Laryngol Otol*. 1965;79:567-75.
9. Pease WS. Neonatal nasal septal deformities. *J Laryngol Otol*. 1969;83:271-4.
10. Jazbi B. Diagnosis and treatment of nasal birth deformities. *Clin Paediatr*. 1974;13:1974.

11. Ali D S. A statistical study on the nasal septum in 5096 cases in Iraq. *J. Laryng.* 1965;79: 244-8.
12. Cummings CW, Flint PW, Harker LA, Haughey BH, Richardson MA, Robbins KT et al. Cummings otolaryngology, head and neck Surgery. 5th ed. Philadelphia: Mosby; 2010: 483-6.
13. Ghazipour A, Abshirini H, Shoar MH, Pursalehan S. Sinonasal Headaches and Post operative outcomes after septoplasty in patients with nasal septal deviation. *Iranian Journal of otorhinolaryngology.* 2011;23(65):133-139.
14. Nayak DR, Ramaswamy B. Endoscopic Approach to Middle Turbinate Squeeze Syndrome. *Indian J. Otolaryngol Head Neck Surg.* 2012;64(2):167-71.
15. Goetz CG, Encj, Pappert EJ. Textbook of clinical neurology. 5th ed. USA: W.B. Saunders; 2008: 248-91.
16. Hwang PH, McLaughlin RB, Lanza DC, Kennedy DW. Endoscopic Septoplasty: Indications, technique and results. *Otolaryngol Head Neck Surg* 1999; 120: 678-82.
17. Lanza DC, Rosin DF, Kennedy DW. Endoscopic septal spur resection. *Am J Rhinol* 1993; 7: 213-6.
18. Gupta N. Endoscopic Septoplasty. *Indian journal of Otolaryngology and Head and Neck Surgery.* 2005;57(3):240-3.
19. Nawaiseh S, Khtoum N A. Endoscopic Septoplasty: Retrospective analysis of 60 cases. *Journal Pak Med Assoc.* 2010;60:796-8.
20. Milojevic M, Sotirovic J, Stosic S, Avramovic S. Unilateral blindness following nasal septoplasty. *B-ENT.* 2014;10(2):161-4.
21. Prepageran N, Lingham OR. Endoscopic Septoplasty: the open book Method. *Indian J Otolaryngol Head Neck Surg* 2010;62(3):310-2.
22. Gupta M, Motwani G. Comparative study of Endoscopic aided septoplasty and traditional septoplasty in posterior nasal septal deviations. 2005;57(4):309-11.