

Dentigerous Cysts of Maxillofacial Region– Clinical, Radiographic and Biochemical Analysis

Sridevi K,¹ Kaushik A,¹ Ramaswamy P,² Manjula M,³ Vinod VC,¹ Aravinda K⁴

¹SGT Dental College, Hospital and Research Institute, Gurgaon, Haryana.

²St. Joseph Dental College and Hospital, Eluru, Andhra Pradesh.

³Govt Dental College and Hospital, Hyderabad, Andhra Pradesh.

⁴Swamy Devi Dyal Hospital and Dental College, Panchkula, Haryana.

Corresponding Author

K Sridevi

Department of Oral Medicine, Diagnosis and Radiology,

SGT Dental College, Hospital and Research Institute,

Gurgaon, Haryana (India).

E-mail: srigivi123@gmail.com

Citation

Sridevi K, Kaushik A, Ramaswamy P, Manjula M, Vinod VC, Aravinda K. Dentigerous Cysts of Maxillofacial Region– Clinical, Radiographic and Biochemical Analysis. *Kathmandu Univ Med J* 2015;49(1):8-11.

ABSTRACT

Background

Dentigerous cyst is the second most common type of odontogenic cysts that encloses the crown of an unerupted tooth by expansion of its follicle due to the collection of cystic fluid. In view of the capability of these lesions attaining a marked size if not diagnosed early and treated properly, the present study was done based on the clinical and radiographic presentation of the dentigerous cyst in addition to the analysis of the cystic contents.

Objective

The present study reported 14 cases of dentigerous cysts (DC) with their incidence and relative distribution of the maxillofacial region along with the clinical and radiographic features and biochemical analysis of cystic fluid.

Method

The study was conducted at Sri Govind Tricentenary Dental College, Hospital and Research Institute, Gurgaon, Haryana for a period of one year and six months. A detailed case history and thorough clinical examination was done for the patients who were provisionally found to have odontogenic cysts. Necessary radiographs, aspiration of the cystic fluid and incisional biopsy were performed to the 14 patients who were provisionally diagnosed with dentigerous cysts (DC) after obtaining the informed consent and the cystic fluid was subjected to biochemical analysis.

Results

Majority of the affected patients with DC were in their second decade and showed more predilection for mandible with a male predominance. The area of predilection was third molar region in the mandible and it is the canine region in maxilla. All the cases were associated with impacted teeth and majority showed expansion of the buccal/labial cortical plate. The various biochemical variables (total protein content, albumin, globulin and albumin: globulin ratio) were also assessed in the present study.

Conclusion

The awareness of protean features of DC evident through this study is essential for the general as well as specialty practitioners for the accurate diagnosis and proper treatment planning of these non cancerous but potentially destructive lesions and also opens new avenues for further research.

KEY WORDS

Cystic fluid, dentigerous cysts, maxillofacial region, odontogenic cysts.

INTRODUCTION

A cyst has been defined as 'a pathological cavity containing fluid, semi fluid or gaseous contents and is not created by the accumulation of pus'. Most cysts, but not all, are lined by epithelium.¹ The maxillofacial region is most commonly affected by a greater number of odontogenic cysts (OC) than any other part of the body because of the ubiquitous presence of epithelial cell rests after odontogenesis.² DC is a type of OC that encloses the crown of an unerupted tooth by expansion of its follicle (Follicular cyst) due to collection of cystic fluid and is attached to the neck of the tooth. DC usually exhibits a slow growth and tendency towards expansion of the cortex of the involved jaw.³ However, despite their benign biological behavior, these lesions can reach a marked size if they are not diagnosed early and treated appropriately.⁴ Moreover, ameloblastoma, epidermoid carcinoma and mucoepidermoid carcinoma are the complications known to be reported to develop from the cyst linings.⁵

Hence the present study was undertaken to analyse the relative frequency and distribution of DC, their clinical and radiographic features along with estimation of proteins in the cystic fluid. This study will not only help the general practitioners to know about the biological behavior of DC which is required for their early detection and treatment but also throws light for future research.

METHODS

A detailed case history and clinical examination was done for the patients who were provisionally found to have odontogenic cysts at Sri Govind Tricentenary Dental College, Hospital and Research Institute, Gurgaon, Haryana for a period of one year and six months. Necessary radiographs, aspiration of the cystic fluid and incisional biopsy were performed to the patients provisionally diagnosed with dentigerous cysts (DC) after obtaining the informed consent and the cystic fluid was subjected to biochemical analysis.

Sample preparation of biochemical analysis of cystic fluid:

Aspiration of the cystic fluid was done for the 14 patients with 2 ml sterile syringe using 21 gauge needle. The area of aspiration was isolated with sterile cotton roles to prevent bacterial contamination. The cystic fluid was centrifuged at 5000 rotations per minute for 10 minutes to remove any particulate matter and supernatants were taken in clear dry aliquots. The supernatants were used to analyze total protein content by Biuret test, to estimate the albumin, globulin and albumin: globulin ratio by Dye Binding Method. Biuret test and Dye Binding Methods were chosen for biochemical analysis as these methods were easy to perform, provided good qualitative results and large number of samples could be efficiently assayed. The inception of the study was pursued following the approval from the ethical committee.

RESULTS

The age of incidence ranged from 11 to 43 years with the mean age of 21.6 years and 57.14% of the patients were in their second decade at the time of diagnosis. As summarized in table 1, males were more frequently affected than females with a male: female ratio of 2.5:1 (10 males and 4 females).

Table 1. Summary of clinical features.

S.No	Clinical features	
1	Age and gender distribution	
	a) Age range	11-43 years
	b) Mean age of incidence	21.6 years
2	Presenting symptoms	
	a) Swelling	1.5 mos-3years (12)
	b) Swelling and intermittent episodes of pain	4 mos (2)
3	Anatomic distribution	
	Number (Percentage)	
	a) Maxilla Incisor/canine region	5(35.72%)
	b) Mandible	
	Incisor/canine region	3(21.43%)
Premolar region	1(7.14%)	
Molar region	5(35.71%)	

The presenting complaint in 85.71% of the patients was found to be swelling of the affected area of jaws and 14.29% had intermittent episodes of pain along with the swelling. The average duration of occurrence for DC ranged from 1.5 months to 3 years. Of the 14 DC, 9 cases (64.28%) affected the mandible and 5 (35.72%) involved the maxilla and all the cases were associated with impacted teeth. Among the nine DC affecting the mandible, 5 cases (35.71%) were associated the third molar region followed by the incisor/canine region (right and left central incisors, right lateral incisor one case each and one case of mandibular left canine as shown in figure 1) and mandibular left second premolar (one case). Maxillary lesions affected three right canines, one right lateral incisor and one left canine (Figure 2). Of 14 cases 11(78.57%) showed unilocular radiolucency and 3 (21.43%) cases showed multilocular radiolucency. Expansion of buccal / labial cortical plates was observed in 78.57% and bicortical expansion was observed in 21.43% of the patients. Ten cases (71.43%) showed sclerotic border,

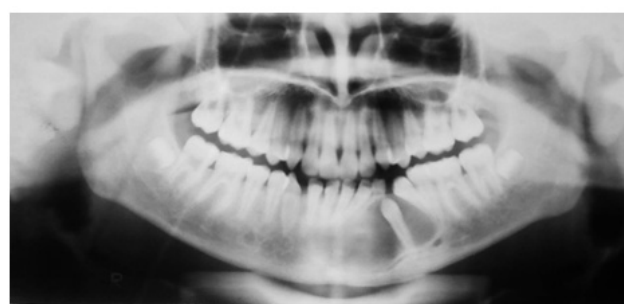


Figure 1. OPG showing the dentigerous cyst involving the mandibular left canine.

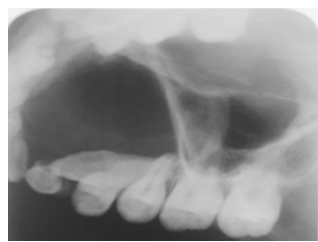

Figure 2. Occlusal radiograph showing the unilocular homogenous cystic radiolucency involving the maxillary right canine

and 7 of 14 DC (50%) showed root resorption. All the cases were associated with impacted teeth and 4 (28.57%) were associated with displaced teeth (table 2).

Table 2. Summary of radiographic features.

S.No	Radiographic features	
1	Radiographic appearance	Number (%)
	a) Unilocular radiolucency	11 (78.57%)
	b) Multilocular radiolucency	3 (21.43%)
2	Expansion of the cortical plates	
	a) Buccal/ labial cortical plate	11 (78.57%)
	b) Bicortical Expansion	3 (21.43%)
3	Sclerotic border	10 (71.42%)
4	Root resorption of adjacent teeth	7 (50%)
5	Impacted teeth	14 (100%)
6	Displacement of adjacent teeth	4 (28.57%)

As depicted in table 3 the quantity of aspirated cystic fluid in DC ranged from 0.6 to 5 ml with an average of 2.14 ml. The total protein content ranged from 3.8 – 8.4 gms / 100 ml with a mean value of 5.8 gms / 100 ml. The albumin content in DC ranged from 2.0 – 4.6 gms / 100 ml with a mean value of 3.18. The globulin level in DC varied from 0.8 – 2.4 gms / 100 ml with a mean value of 1.84. The albumin: globulin ratio ranged from 0.46 – 3.5 with a mean value of 2.28.

Table 3. Details of biochemical analysis.

S.No	Biochemical variable	Range	Mean
1	Quantity of the aspirated fluid	0.6-5.0	2.14
2	Total protein in grams/100ml	3.8-8.4	5.8
3	Albumin in grams/100ml	2.0-4.6	3.18
4	Globulin in grams/100ml	0.8-2.4	1.84
5	Albumin / Globulin ratio	0.46-3.5	2.28

DISCUSSION

The maxillofacial region is affected by a greater number of cysts than any other parts of the body. Odontogenic cysts are frequently encountered in dental practice constituting an important aspect of oral and maxillofacial pathology and are formed by the activation of odontogenic cell rests entrapped within the tissue of the jaws, such as the epithelial remnants of Malassez, cell rests of Serrae or the enamel organ.⁶

DC are the second most common type of cyst in the jaws after radicular cysts; therefore knowledge on the incidence and relative distribution as well as their clinical

and radiographic presentation may help the practitioners to determine an early and likely clinical diagnosis. The exact pathogenesis of DC remains unknown; however most authors favor a developmental origin. It encloses the crown of an unerupted or supernumerary tooth by expansion of its follicle and is attached to its neck.⁷

Similar to the previous studies,^{4,7-10} in the present study the age of incidence of DC ranged from 11-43 years with a mean age of 21.6 years and a peak incidence was observed during the second decade of life, although Waldren CA,¹¹ reported a wide age range with peak incidence from 2nd to 4th decades and Jones et. al.¹² also reported a wide age range and a peak incidence during 5th decade. The marked male predominance with a male female ratio of 2.5:1, in the present study lies within the range of 1.1:1 to 2.9:1 of previously reported studies,⁷⁻¹² but one previous study by Prockt has reported a female predominance.¹³ The male predominance, variations in the age of incidence (wide age range) peak incidence and mean age may be attributed to genetic factors, type of the ethnic group, size of the sample and age of the patient at the time of reporting and diagnosis. Swelling and/or pain were the presenting complaints as described in the literature to date.

The most common site of involvement is the mandibular third molar region followed by the maxillary canine region consistent with the results in the present study,^{2,6,8,9,12} although Tortorici et. al.¹⁴ reported the preferential involvement of DC in the anterior maxillary region and Waldren CA found the upper third molars to be the most prevalent site.¹¹ This may not be a surprising finding given the fact that lower third molars and upper canines are teeth most commonly affected by impaction. In the present study rare cases were also found in the maxillary incisors, mandibular anteriors and mandibular premolar. The DC present as swelling and/or pain although asymptomatic lesions found incidentally by radiographic examination.

Radiologically, majority of DC appear as well delineated unilocular homogenous radiolucency enveloping the crown of an unerupted tooth, where the radiolucency starts from cemento-enamel junction at the neck of the tooth, but, some are multilocular.^{15,16} In the absence of infection, most DC show well corticated margins, which is thin and smoothly curved. The expansion of the Buccal/labial plate is common but buccal and lingual (bicortical) expansion is extremely rare.^{15,16} In addition to the presence of an unerupted/impacted tooth, DC have a greater tendency than other jaw cysts to resorb the roots and displace not only the involved tooth but also the adjacent ones.^{1,15,16} These findings are consistent with the results of the present study as 78.57% of the lesions are unilocular and expansion of buccal/labial plate was seen in 78.57% and bicortical expansion is present only in 21.43% of patients.

There were only few reported studies on the biochemical aspect of the cystic fluid. The studies done by Skaug N, Brown RM and Toller PA demonstrated that cystic fluids have a composition with respect to total protein,¹⁷⁻¹⁹ relative

distribution of protein fractions and proteins originating from plasma which is characteristic of inflammatory exudates. The extent of inflammation and cell degradation may explain the variation in composition of different cystic fluids. In the present study, the total volume of aspirated fluid from DC ranged from 0.6 to 5.0 ml with an average of 2.14 ml. The total protein content in DC in this study ranged from 3.8-8.4 gm/100 ml with the mean value of 5.8 gm/100 ml in accordance with the earlier studies which suggested that the protein content of DC can be explained by the ability of individual proteins to diffuse through the cyst wall and less modified by the cellular activity of cyst wall.¹⁸ The albumin content in DC in the present study ranged from 2.0-4.6 gms/100 ml with a mean value of 3.18. The globulin level in DC varied from 0.8-2.4 gms/100ml with a mean value of 1.84. The albumin: globulin ratio ranged from 0.46-3.5 with a mean value of 2.28.

Tollar PA demonstrated that the total protein levels in non-keratinizing cysts were in the range of 5.0 to 11 g/100ml with a mean of 7.1 g/100ml and suggested that the soluble protein level in the aspirated cyst fluid is over 4.0 g/100ml, then the lesion may be apical,¹⁹ dentigerous, fissured or even ameloblastoma. The reported mean concentration of total protein in DC was 6.75 g/100ml, albumin, globulin contents were in the range of 2.09 g/100ml to 4.1 g/100ml and 0.9 g/100ml to 2.34 g/100ml respectively. The mean concentration of albumin and globulin were 3.52 and 3.1 respectively.

Skaug N also suggested that fluid from jaw cysts was remarkably rich in protein when compared with other body fluids.¹⁷ Factors such as the intravascular blood pressure, the vascular permeability texture of the cyst wall, the intracystic pressure as well as the decreased rate of the cyst fluid would also influence the protein composition of

the cyst content. The cyst is usually treated by enucleation along with the removal of the involved tooth. When the extraction is not desired orthodontic traction of the involved tooth may follow cystectomy and marsupialization may be carried out for larger lesions.

CONCLUSION

In conclusion this paper reports that:

- DC has a male predilection with a peak incidence during second decade.
- The most commonly affected site is the mandibular third molar region followed by the maxillary canine region.
- Involvement of maxillary right lateral incisor, mandibular right and left central incisors, mandibular right lateral incisor and mandibular left canine and left second premolar is rare and uncommon.
- Expansion of the buccal/labial cortical plate is more common.
- Throws some light on protein analysis of the cystic fluid for future research.

Knowledge of the clinical and radiographic presentations and an insight to the biological nature of the DC is needed to ensure early detection and prompt management of these non-cancerous but potentially destructive lesions.

The results obtained from the present study are derived from a small sample population. Hence further research with larger sample size and longer duration of the study are necessary to derive definite conclusions.

REFERENCES

1. Shear M, Speight PM. Cysts of the oral and maxillofacial regions; 4th edition. Oxford: Blackwell Munksgaard; 2007.
2. Koseoglu BG, Atalay B, Erdem MA. Odontogenic cysts: A clinical study of 90 cases. *J Oral Science* 2004; 46(4): 253-7.
3. Benn A, Altini M. Dentigerous cysts of inflammatory origin - A clinicopathologic study. *Oral Surg Oral Med Oral Pathol Oral Radiol Endod* 1996; 81: 203-9.
4. Ochsenius G, Escobar E, Godoy L, Peñafiel C. Odontogenic cysts: Analysis of 2,944 cases in Chile. *Med Oral Patol Oral Cir Bucal*. 2007; 12(2):85-91.
5. Stuart CW, Michael JP. Oral radiology – Principles and interpretation; 6th edition. Mosby: Philadelphia; 2011.
6. Manickam S, Mandana D, Praveen SB. Analysis of 153 cases of odontogenic cysts in a South Indian sample population: a retrospective study over a decade. *Braz Oral Res* 2012; 26(4):330-4.
7. Meningaud JP, Oprean N, Pitak-Arnop P, Bertrand JC. Odontogenic cysts: A clinical study of 695 cases. *J Oral Sci* 2006;48(2):59-62.
8. Lin HP, Wang YP, Chen HM, Cheng SJ, Sun A, Chiang CP. A clinicopathologic study of 338 dentigerous cysts. *J Oral Pathol Med* 2013;42:462-7.
9. Yeo JF, Rosnah BZ, Ti LS, Zhao YY, Ngeow WC. Clinicopathologic study of dentigerous cysts in Singapore and Malaysia. *Malays J Pathol* 2007;29:41-7.
10. Ledsma-Montes C, Hernandez-Guerrero JC, Garcés-Ortiz M. Clinicopathologic study of odontogenic cysts in a Mexican sample population. *Arch Med Res*. 2000 Jul-Aug; 31 (4):373-6.
11. Waldron CA. Odontogenic cysts and tumors. In Neville BW, Damm DD, Allen CM, Bouquet JE eds. *Oral and Maxillofacial Pathology*, 2nd ed, Philadelphia: W.B. Saunders;493-540.
12. Jones AV, Craig GT, Franklin CD. Range and demographics of odontogenic cysts diagnosed in a UK population over a 30-year period. *J Oral Pathol Med*. 2006 Sep;35(8):500-507.
13. Prockt AP, Schebela CR, Maito FD, Sant'Ana-Filho M, Rados PV. Odontogenic cysts: analysis of 680 cases in Brazil. *Head Neck pathol*. 2008 Sep; 2 (3): 150-6. Epub 2008 Jun 10.
14. Tortorici S, Amodio E, Massenti MF, Buzzanca ML, Burrucano F, Vitale F. Prevalence and distribution of odontogenic cysts in Sicily: 1986-2005. *J Oral Sci*. 2008;50(1):15-18.
15. Farman AG, Nortje CJ, Wood RE. Panoramic Radiology of Pericoronary Pathoses. In *Panoramic Radiology*, 1st ed, Springer; 2007; p143.
16. Langlais RP, Langland OE, Nortje CJ eds. *Diagnostic Imaging of the Jaws*, 1st ed, Williams and Wilkins; 1995; p 287.
17. Skaug N. Proteins in fluids from non keratinizing jaw cysts in man. *Int J Oral Surg* 1977;6:107-121.
18. Brown RM. Some observations on fluids of odontogenic cysts. *J Oral Pathol* 1976; 5: 74-87.
19. Toller PA. Protein substances in odontogenic cyst fluids. *Br Dent J* 1970; 128(a): 317-32.