

A case of Synchronous Malignancy of Stomach and Kidney

Aslam S SM,¹ Sridhar H,² Rao MY¹

¹Department of Medicine

²Department of Pathology

M.S.Ramaiah Medical college

Bangalore, India

Corresponding Author

Shaikh Mohammed Aslam .S

Department of Medicine

M.S.Ramaiah Medical college

Bangalore, India

Email: drmdaslam@yahoo.com

Citation

Aslam S SM, Sridhar H, Rao MY. A case of Synchronous Malignancy of Stomach and Kidney. *Kathmandu Univ Med J* 2013;41(1):94-95.

ABSTRACT

The synchronous occurrence of primary renal cell carcinoma with gastric cancer is very rare. We report a case of 41 year old male who presented on 05/07/2011 to M S Ramaiah hospital, Bangalore with history of fever, pain abdomen and malena. Ultrasound abdomen and pelvis showed large heterogenous mass arising from the upper pole of left kidney. Computed tomography of the abdomen showed left renal cell carcinoma. Renal biopsy showed features consistent with renal cell carcinoma – clear cell type. Oesophagogastroduodenoscopy revealed gastric polypoidal growth. Gastric biopsy from the growth revealed poorly differentiated adenocarcinoma of stomach. We report this case to highlight a rare occurrence of synchronous malignancy of stomach and kidney.

KEYWORDS

Gastric adenocarcinoma, gastric cancer, renal cell carcinoma, synchronous malignancy

INTRODUCTION

Multiple primary cancers in a single patient are uncommon. The synchronous occurrence of primary renal cell carcinoma with gastric cancer is very rare.¹⁻³ We report a case of a 41 year old male who was diagnosed with synchronous malignancy that consisted of renal cell carcinoma and gastric adenocarcinoma.

CASE REPORT

A 41 year old male patient presented on 05/07/2011 to M S Ramaiah hospital, Bangalore with history of fever, diffuse abdominal pain and malena of 15 days duration. He also gave history of loss of appetite and 10kg weight loss. On examination he was pale and his blood pressure was 110/70 mmHg. Systemic examination was normal. Investigations revealed hemoglobin of 10gm%, ESR was 116mm at the end of first hour, and peripheral smear showed normocytic, normochromic anaemia. Renal function tests, liver function tests, serum electrolytes and urine routine examination were normal. Ultrasound abdomen and pelvis showed

large heterogenous mass arising from the upper pole of left kidney. The mass measured 108X65X10 mm. The mass was heterogenous and had anechoic areas with few areas of vascularity. In view of ultrasonographic finding CT abdomen was done which showed left renal cell carcinoma with extensive hepatic, lung and bone metastasis.

To confirm the diagnosis CT guided renal biopsy was done. Renal biopsy revealed tumour cells arranged in diffuse sheets. Tumour cells are large, round to oval with varying size, centrally situated nuclei and cytoplasm ranging from optically clear to granular with well defined cell membranes (Fig 1). Focally the tumour cells show bizarre nuclei. Large areas of tumour necrosis were seen. Diagnosis of renal cell carcinoma – clear cell type – Fuhrman – nuclear grade – G2 to G4 was made.

In view of malena, esophagogastroduodenoscopy was done, which revealed gastric polypoidal growth. Biopsy was taken from the growth. Gastric biopsy showed tumour cells predominantly arranged in cords and sheets. They are round to oval with hyperchromate nucleus, prominent

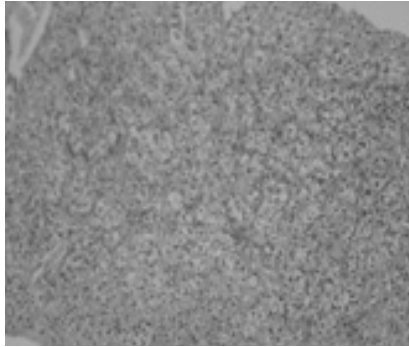


Figure 1. Photomicrograph of renal biopsy showing tumour cells - round to oval with central nuclei and optically clear to granular cytoplasm with well defined cell membranes (original magnification 100X; Hematoxylin Eosin stain).

nucleoli and eosinophilic cytoplasm, showing moderate to severe degree of pleomorphism (Fig 2). A few tumour giant cells were seen. Diagnosis of poorly differentiated adenocarcinoma of stomach was made.

In view of extensive hepatic, lung and bone metastasis no surgical option was considered and the patient was advised sunitinib therapy but patient refused and hence patient was only given supportive treatment and was discharged at request.

DISCUSSION

As a result of longevity, the incidence of multiple primary malignancies is likely to increase. In the recent decades multiple primary cancers in one patient is not uncommon.⁴

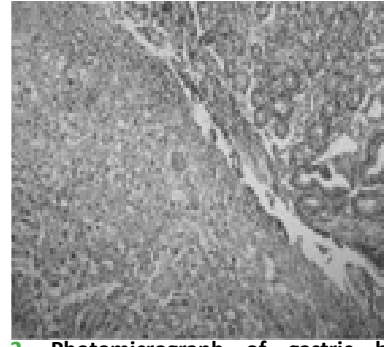


Figure 2. Photomicrograph of gastric biopsy showing pleomorphic tumour cells - round to oval with hyperchromatic nucleus, prominent nucleoli with eosinophilic cytoplasm (original magnification 100X; Hematoxylin Eosin stain).

Second neoplasms are classified as 'synchronous', defined as occurrence of the index tumour and second malignancy within six months of each other.⁵

Renal cell carcinoma has been reported to be associated with other primary malignancies. Gastrointestinal cancers account for most of other primary malignancies in patients with renal cell carcinoma.⁶ But synchronous occurrence of renal cell carcinoma with gastric cancer is very rare

The incidence of gastric cancer with a synchronous second primary cancer varies from 0.7% to 3.5%.⁷ The association of gastric cancer with a primary renal cell carcinoma is extremely uncommon. In India only two such cases have been reported.^{1,8} In conclusion our case highlights a rare occurrence of synchronous double malignancy consisting of renal cell carcinoma and gastric adenocarcinoma.

REFERENCES

1. Nagral A, Mohandas KM, Swaroop D, Swaroop VS, Fakhri AR, Krishna BA et al. Double primary neoplasms of the stomach and kidney. *Indian J Gastroenterol* 1991;10(2):67-68.
2. Azuma T, Koide A, Asami H, Kuroda M, Yano H, Honda E et al. A case of synchronous multiple primary cancers of the stomach and kidney. *Gan No Rinsho* 1990;36(15):2605-9.
3. Funaki H, Suzuki N, Adachi M, Sakakibara T, Sakuma Y, Ohhori T et al. Double primary malignant neoplasm of renal cell carcinoma and stomach cancer: report of two cases. *Hinyokika Kyo* 1985;31(9):1629-34.
4. Chong V H, Idros A, Telisinghe P U. Triple synchronous gastrointestinal malignancies: a rare occurrence. *Singapore Med J* 2010; 51(10): 176-178.
5. Sarkar S, Kundu AK, Chakrabarti S. Lungs : Victim of Synchronous Double Malignancies. *J Assoc Physicians India* 2007;55:235-7.
6. Sato S, Shinohara N, Suzuki S, Harabayashi T, Koyanagi T. Multiple primary malignancies in Japanese patients with renal cell carcinoma. *Int J Urol* 2004;11(5):269-75.
7. Lee JH, Bae JS, Ryu KW, Lee JS, Park SR, Kim CG et al. Gastric cancer patients at high-risk of having synchronous cancer. *World J Gastroenterol* 2006;12(16):2588-92.
8. Kalyani R, Prathima KM, Kumar ML, Srikantia SH. Multiple primary malignancies: synchronous and metachronous presentation—case report. *Indian J Pathol Microbiol* 2003;46(3):470-2.