

Case report**Asymptomatic Diabetes Insipidus Detected after Partial Pneumonectomy of Upper Left Lobe of Lung Diagnosed with Adenocarcinoma: An Unusual Case Report**Dan Singh Budal¹, Rajendra Dev Bhatt^{*2,3}, Chen Ling¹, Chen Jing¹, Chunwei Ma¹, Xujun Ye¹¹Department of Geriatrics, Zhongnan Hospital of Wuhan University, Wuhan City, PR China²Kathmandu University School of Medical Sciences, Dhulikhel, Nepal³Wuhan University, Faculty of Medicine, School of Health Sciences, Wuhan, ChinaArticle Received: 26th March, 2023; Accepted: 18th May, 2023; Published: 30th June, 2023DOI: <https://doi.org/10.3126/jonmc.v12i1.56524>**Abstract**

We present a case of 80 years woman chronic smoker (10 cigarettes)/ per day for 50 years diagnosed with adenocarcinoma in the upper left lobe of her lungs in a geriatric clinic. She has no history of diabetes but taking medicine for hypertension and dyslipidemia. She was admitted and operated on for partial pneumonectomy and discharged after 11 days of care with all essential drugs, and instructions. After 4 weeks of treatment, she complained of unusual polyuria, diagnosed in the department of Geriatrics, Zhongnan Hospital of Wuhan University, China.

Keywords: Adenocarcinoma, Diabetes insipidus, Pneumonectomy**Introduction**


Among all cancers, lung cancer (LC) still remains one of the most commonly encountered cancers globally and still one of the leading cause of cancer death for male and females [1]. However lung cancer rates are decreasing in either sex worldwide [2]. Among the lung cancers, lung adenocarcinoma (LAC) are the commonest which is rarely metastasizes to unusual tissues but usually do with liver, adrenal gland and bones [3]. Metastatic involvement of LAC to the pituitary glands remains very rare [4]. Here is the case found in geriatric clinic of Department of Geriatrics, Zhongnan Hospital of Wuhan University, Wuhan, China diagnosed with LAC by radiological interventions.

We present a case of woman chronic smoker (10

cigarettes) per day for 50 years diagnosed adenocarcinoma in upper left lobe of lungs in geriatric clinic. She has no history of diabetes but taking medicine for hypertension and dyslipidemia. She was admitted and operated for partial pneumonectomy and discharged after 11 days care with all essential drugs, instruction. After 4 weeks of treatment she had complain of unusual polyuria.

Case Report

A female of 80 years old visited geriatric clinic of Zhongnan Hospital with chief complaints of fatigue, poor appetite, emaciation, nausea, vomiting, palpitation, chest tightness abdominal pain and diarrhea. She went to department of Traditional Oral Chinese medicine a couple of week

	<p>©Authors retain copyright and grant the journal right of first publication. Licensed under Creative Commons Attribution License CC - BY 4.0 which permits others to use, distribute and reproduce in any medium, provided the original work is properly cited.</p>	<p>*Corresponding Author: Xujun Ye Assistant Professor Email: wdxjy@whu.edu.cn ORCID: https://orcid.org/0000-0003-0609-723x</p>
---	---	--

Citation

Budal DS, Bhatt RD, Chen L, Chen J, Chunwei M, Xujun Y, Asymptomatic Diabetes Insipidus Detected after Partial Pneumonectomy of Upper Left Lobe of Lung Diagnosed with Adenocarcinoma: An Unusual Case Report, JoNMC. 12:1 (2023) 85-87



before but symptoms didn't subside.

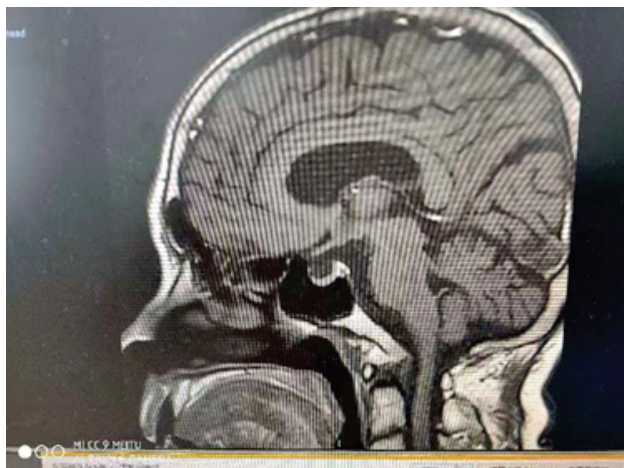


Figure 1: CT scan image of patient

Table 1: Vitals and laboratory values at patient's first visit

Variables	Obtained Value
Temperature	36.3°C
Systolic blood pressure	135mmof Hg.
Diastolic blood pressure	69mmof Hg.
Pulse	74 b/min
Sodium	135.0 mEq/l
Potassium	3.0 mEq/l
Serum Urea	5.52mmol/l
Serum Creatinine	1mg/dl

One week ago, she went to a provincial government hospital to check the electrolyte, which indicate that potassium is 2.9 mmol/l (slightly low) and was given oral potassium supplement for symptomatic treatment. On the basis of chief complains, radiological interventions were performed, her enhanced CT and PET-CT of the left lung showed malignant tumor, the aortic ulcer with mural thrombosis, T11 vertebral compression and edema signal was obvious. Cardiothoracic surgery consultation was done and Aortic Stent implantation, Thorascopic segmental resection of lung was advised.

Orthopedic consultation was also done and biopsy for identification of pathological fractures was advised. Prognosis about the disease and possible outcomes were well explained to family members in detail and they agreed for surgical treatment. Then the patient was transferred to the thoracic surgery department of Zhongnan hospital for treatment and after completing relevant examinations, she underwent Thorascopic partial Pneumonectomy (left Upper Lobe) and Thoracic Aortic Stent implantation along with Thorascopic Mediastinal lymphadenectomy

under general Anesthesia.

After the operation, she was transferred to intensive care unit (ICU) for treatment against possible sepsis, hypotension, hypokalemia, fluid imbalance. One day later, she transferred to thoracic surgery department for symptomatic supportive treatment such as possible sepsis treatment, analgesia, anti-cough therapy. Few days later the patient general condition is fair and thoracic drainage tube has been removed and patient was admitted in Post operative thoracic surgery department as " Post- Operative left lung malignant tumor care" treatment. She was hospitalized for 11 days in thoracic surgery department.

After 27 days of surgery she visited clinic again with complain of unusual polyuria. We did water deprivation Vassopressin Test: Urine Osmotic Pressure Before water Deprivation was 127 mOsm/kg. After water deprivation for 13-15 hours, the urine osmotic pressure will no longer rise and will remain about 500mOsm/Kg. One hour after Vassopressin injection, the urine osmotic pressure was 494Osm/kg; Urine Osmolality was 475mOsm/kg, 2 hours after vasopressin injection. Urine osmolality was 379mOsm/kg, 8hours after Vasopressin Injection.

Discussion

Metastasis of lung tumor to the pituitary gland is a very rare phenomenon in systemic malignancy while metastasis is commonly found in the posterior pituitary than anterior [5]. Pituitary metastasis is usually asymptomatic, and while symptoms are noticed in only less than 10% cases [6].

For timely diagnosis of such cases, Magnetic Resonance Imaging (MRI) along with clinical findings forms the basis of diagnosing pituitary metastasis is essential. MRI also helps to differentiate metastasis from adenomas. Radiological features suggestive of metastasis include (I) Thickening of the pituitary stalk (II) loss of a high intensity signal from the posterior pituitary (III) is intensity on T1 and T2 weighted MRI images (IV) invasion of the cavernous sinus and (V) sclerotic changes around the Sella tursica [7]. So asymptomatic diabetes insipidus very rare in LAC but still clinician should focus on all clinical presentation of patients, along with radiological and laboratory parameters.

Conclusion

In this case, there are two peculiar features. The first is, she had a mass lesion in the lung, but did not have any symptom. Second, apart from spread to adjacent mediastinal nodes and to the



pleura, the only other area to where the tumor had metastasized was to the posterior pituitary. There were no bony or intra-abdominal metastatic deposits. To our knowledge, this is rare case has been documented in literature. These entire features make this case is unique indeed.

References

- [1] Siegel RL, Miller KD, Jemal A. Cancer statistics, 2017, CA Cancer J Clin. 67 (2017) 7- 30. DOI: 10.3322/caac.21387.
- [2] Klikovits T, Lohinai Z, Fábíán K, et al., New insights into the impact of primary lung adenocarcinoma location on metastatic sites and sequence: A multicenter cohort study, Lung Cancer. DOI: 10.1016/j.lungcan.2018.11.004.
- [3] Gulati S, Kiefer C, Karim NA, Diabetes insipidus: An unusual presentation of adenocarcinoma of the lung in a patient with no identifiable lung mass, N Am J Med Sci. 7 (2015) 476-479. DOI: 10.4103/1947-2714.168677.
- [4] Ach T, Wojewoda P, Toullet F, et al., Multiple endocrinological failures as a clinical presentation of a metastatic lung adenocarcinoma. Endocrinol Diabetes Metab Case Reports. 2020 (2020) 1-6. DOI: 10.1530/EDM-20-0024.
- [5] Javanbakht A, D'Apuzzo M, Badie B, et al., Pituitary metastasis: A rare condition, Endocr Connect. 7 (2018) 1049-1057. DOI: 10.1530/EC-18-0338.
- [6] Karamouzis M V., Melachrinou M, Fratzoglou M, et al., Hepatocellular carcinoma metastasis in the pituitary gland: Case report and review of the literature, J Neurooncol DOI:10.1023/A:1023994604919.
- [7] Shimon I, Metastatic Spread to the Pituitary, Neuroendocrinology. 110 (2020) 805-808. DOI: 10.1159/000506810.

