

Original Article**Treating Facial Cuts to a Near Scar Less Outcome in Children****Ashish Lal Shrestha*¹, Ang Dali Sherpa²**¹Department of Pediatric Surgery, Grande International Hospital, Kathmandu, Nepal²Department of Emergency Medicine, Grande International Hospital, Kathmandu, NepalArticle Received: 7th May, 2021; Accepted: 26th June, 2021; Published: 30th June, 2021DOI: <http://dx.doi.org/10.3126/jonmc.v10i1.37980>**Abstract****Background**

Facial Lacerations constitute an important reason for children (< 18 years) to visit emergency room. While bleeding and pain are the associated acute problems, the long term outcome in terms of a cosmetically acceptable scar is a matter of significant parental concern. The aim of the research is to study the profile of facial lacerations in children and to assess the outcome of repair.

Materials and Methods

A retrospective review of children who underwent facial laceration repair between January 2018 and December 2020 was done. The deep ones underwent sutured repair in layers reinforced with tissue adhesive in operation room under intra-venous anesthesia and superficial ones in emergency room with only tissue adhesive following usual wound treatment protocol. Demographics, surgical details and outcomes were studied. All the repaired cuts were followed up at 1 year retrospectively and the cosmetic outcome was evaluated using modified stony brooke scoring system.


Results

A total of 40 patients (24 males, 16 females) underwent facial laceration repair at a mean age of 4.7 years (range 1-13 years). Seventeen were deep and 23 were superficial cuts. Only 1 child in the superficial group with gross wound contamination at presentation developed wound infection. No dissatisfaction was reported in the deep group while parents of 4 children in the superficial group reported dissatisfaction with the final scar.

Conclusion

While surface cuts can be treated with irrigations and tissue adhesive in the emergency room, the deeper cuts require layered repair aided by tissue adhesive for optimum scar outcome.

Keywords: *Face, Lacerations, Tissue Adhesives, Scar*

| | | |
|---|---|--|
|  | <p>©Authors retain copyright and grant the journal right of first publication. Licensed under Creative Commons Attribution License CC - BY 4.0 which permits others to use, distribute and reproduce in any medium, provided the original work is properly cited.</p> | <p>*Corresponding Author: Dr. Ashish Lal Shrestha Consultant Pediatric & Neonatal Surgeon Email: ashishlalshrestha75@gmail.com ORCID: https://orcid.org/0000-0002-4299-8177</p> |
|---|---|--|

Citation

Shrestha AL, Sherpa AD, Treating Facial Cuts to a near Scar less Outcome in Children, JoNMC. 10:1 (2021) 46-50.



Introduction

Children have tendency to fall or hit against objects or surfaces and develop cuts and tears to the face even with trivial trauma. During both indoor and outdoor activities, facial lacerations may incur. Although, mostly minor and treatable at home, some may need a visit to the emergency room (ER). Just as bleeding and pain are the immediate issues, the long term outcome in view of an acceptable scar is always a serious parental concern.

Despite much experimentation and multitude of approaches, even now the quest for an ideal wound closure technique continues to evolve. From preparation to primary closure and from interrupted non-absorbable sutures to tissue adhesive (TA), various techniques attempt to address immediate wound problems and seek an ideal method in order to produce "An imperceptible scar". Therefore, it is desirable to seek a technique that could result in a near scar less outcome.

With an objective to understand the profile of children with facial lacerations and to assess the outcome of repair the current study was undertaken. We hereby present our results of treating facial lacerations in children.

Materials and Methods

A retrospective study was performed at Grande International Hospital, Kathmandu, Nepal of children undergoing facial laceration repair between 2018 and 2020. A total of 40 patients were enrolled, children (age groups ≤ 18 years) with linear lacerations to the face both superficial and deep presenting within 6 hours of injury were included for the study. Facial lacerations presenting beyond 6 hours of injury, wounds with crushed margins, bite wounds, stellate wounds or those requiring debridement were excluded. Following a pre-existent protocol children were categorically divided into 2 groups: 1. Deep Cuts (extending into and involving the muscle layer) 2. Superficial Cuts (extending till the muscle layer but not involving the muscle layer).

Those assessed as deep cuts were preferentially managed in the operation room (OR) under intravenous anesthesia (IVA), where in thorough wound exploration was possible for removal of foreign bodies, clots and debris. This was followed by normal saline irrigations and subsequent repair in 3 layers. The muscles were repaired with 4-0 Vicryl interrupted sutures and dermis with 5-0 Vicryl sub-cuticular sutures. The skin was opposed with TA (N-Butyl-2-Cyanoacrylate) while simultaneously applying mild pressure across the skin edges using a non-tooth fine Adson's

forceps causing some degree of wound eversion that is considered crucial for wound healing. The superficial cuts were treated at ER in a suture less manner using a similar technique to apply TA after wound irrigation. Post repair, the wounds were left open in both the groups without an occlusive dressing. The repaired cuts were followed up retrospectively at 1 year. Scar assessment was done using modified stony brooke scoring system (MSBSS) (graded 0-8, with 0 as the worst and 8 as the best possible scar). Parental opinion was also sought on satisfaction and acceptability of the scar. The demographics and surgical details were tabulated and studied along with outcomes. The results were analyzed using SPSS software.

Results

Patient demographics

A total of 40 patients (24 males and 16 females) underwent facial laceration repair at a mean age of 4.7 years (Age Range 1-13 years). Of these, 17 had deep and 23 had superficial lacerations as shown in Table 1. In each group, the most number of children belonged to the age group 0-6 years or Preschool age while the least number of children to sustain injuries was in the adolescent age group.

Table 1: Showing age and number of children with facial cuts

| Age (years) / Depth | Deep Number | Superficial Number |
|---------------------|-------------|--------------------|
| Preschool(0-6) | 12 | 18 |
| School (7-12) | 5 | 4 |
| Adolescent(13-18) | 0 | 1 |
| Total | 17 | 23 |

The cuts were categorized based on length. The mean length of deep laceration was found to be 5 cm and that of superficial one was 2 cm. The most of the deep cuts were noted to be over the frontal and supra orbital regions while most of the superficial cuts were located over the frontal region as shown in Table 2.

Table 2: Showing region of distribution of facial cuts

| Deep Lacerations | | Superficial Lacerations | |
|------------------------------|-----------|-------------------------|-----------|
| Location | Number | Location | Number |
| Frontal | 7(41%) | Frontal | 11(48%) |
| Supra orbital | 7(41%) | Supra orbital | 3(13%) |
| Zygomatico-Auriculo-Temporal | 2(12%) | Zygomatic | 1(4%) |
| Sub-mental | 1(6%) | Sub-mental | 8(35%) |
| Total | 17 | Total | 23 |

Amongst the deep lacerations, 9/17 (53%) had active bleeding and 2 had gross wound contamination at presentation. There were no



events of post procedural bleeding or hematoma formation in any of the patients. No events of wound infection, suture granuloma or suture sinus were noted. All were satisfied with the final scar outcome with a Mean MSBSS score of 6-7. Amongst the superficial lacerations, 13/23 (56%) had active bleeding and 2 had gross wound contamination at presentation. There were no events of post procedural bleeding or hematoma formation in any of the patients. One child with gross wound contamination at presentation had developed wound infection that settled with regular dressings. No events of suture granuloma or suture sinus were noted. Nineteen parents (83%) patients were satisfied with the final scar outcome with a Mean MSBSS score of 6-7 while 4/23 reported dissatisfaction with Mean MSBSS score of 4 in this category. On the whole 90% of parents were satisfied with the treatment outcome.

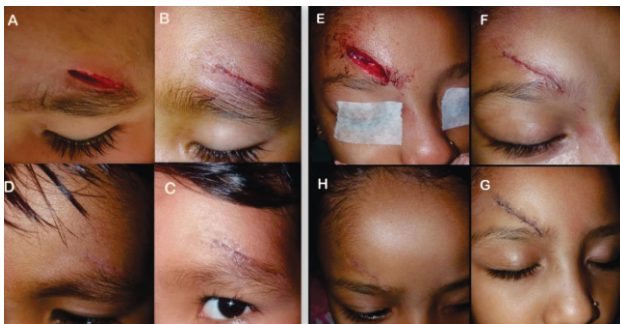

Figure 1A-D: Scar outcome of a patient with superficial laceration. A. After NS irrigation B. After TA application C. At 1 week follow up and D. At 1 year follow up **Fig 1E-H:** Scar outcome of a patient with deep laceration A. Pre-operative B. Immediate post-operative C. At 1 week and D. At 1 month follow up.

Discussion

Childhood facial cuts bear a considerable burden in health care, constituting up to 28% of all the lacerations, with lacerations themselves representing 30-40% of all the childhood injuries presenting to the ER [1-2]. While surgical sutures continue to be used most commonly for their repair, over the years, simultaneous investigations into other wound closure materials have led to many noteworthy innovations including Staplers, Surgical Zippers and even Laser Assisted Tissue Welding [3]. Amidst these, TA was also able to attract a decent share of utility, interest and scrutiny. Its use in pediatric facial lacerations has been studied earlier, albeit mostly focused into factors like reduced pain and anxiety, short procedural time and reduced overall cost. All these matters of specific parental concern have been settled beyond argument. Right since its discovery by Ardis in 1949, and

earliest clinical use by Coover in 1959, over the last 30 years, TA has won considerable appreciation and gained increasing applicability and acceptance [4].

Now-a-days, apart from suture-less circumcisions, hernia repairs, Pfannenstiel incisions and laparoscopic wounds, TA is being used in a wider variety of situations including Brain Surgeries. [5-10]

Most of the earlier studies attempted to address post procedural bleeding, wound dehiscence and infection suggesting TA to be a good alternative to the conventional sutures based on scar appearance along with aforementioned outcomes. Its applicability, however, for the deeper and longer wounds seems to have been largely unaddressed as most of these studies involved short lacerations (mean length: <4 cm) and mainly low tension wounds.[11-13]. Our study attempted to expand the suitability of use of TA by including the lacerations >4 cm (longest: 10 cm) and those with increased tension (obliquely or vertically across the Langer's skin creases). This was made possible by categorically treating the facial wounds by classifying them based on depth rather than length. And subsequently repairing deep cuts using a multi-layered technique (absorbable fine sutures for the deeper tissues) followed by TA application for the skin and similarly applying only TA over the skin for the superficial cuts.

With a layered closure for deep cuts, following advantages were clearly noted: 1. the use of interrupted 4-0 Vicryl sutures for the muscle avoided the potential dead space between the injured muscle edges, preventing post operative bleeding/ hematoma/seroma formation that could lead to a step defect or produce wound dehiscence and poor scar outcome. 2. The use of 5-0 Vicryl sutures in a sub-cuticular fashion allowed distribution of tension in the dermal layer of skin facilitating epidermal approximation in a tension free manner causing the epidermal edges to meet in a near alignment position by the time sub-cuticular sutures were done. 3. The use of mild pressure with non-toothed fine Adson's forceps across the skin edges before application of TA, allowed some degree of wound eversion that is crucial for wound healing. 4. The use of TA as the final layer of wound closure had following benefits: a. Elimination of need for suture removal b. Speed of closure c. Elimination of skin penetration by suture needle reducing chances of infection and post operative pain d. Bactericidal protective bio-film cover e. Elimination of the need for an occlusive dressing. [1,2], [12-14].



Notably, majority of our children belonged to the Preschool age (0-6 years) with very few in the adolescent group. Clumsiness and gait instability along with lack of attention in this age group could possibly be making them vulnerable to facial trauma. Also a T-shaped configuration of injuries that was centered upon the forehead was noted as shown in Figure 5. This was in keeping with a similar study that involved a broader age spectrum from preschool children to senior citizens [14].

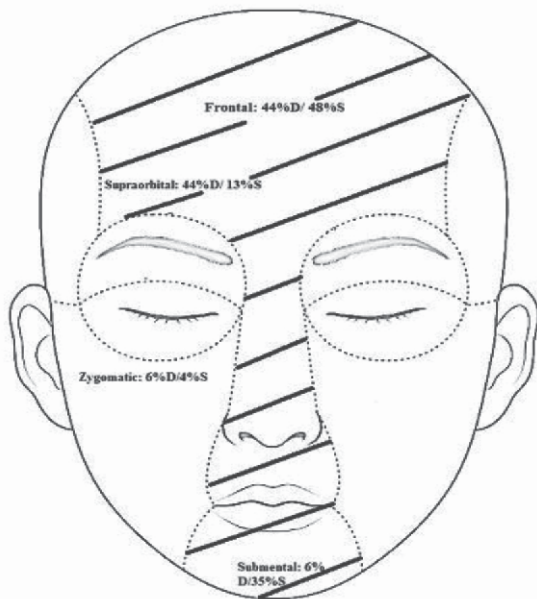


Figure 2: Pictorial illustration of distribution of lacerations showing a T-shaped configuration centered over the frontal region. (D: Deep Lacerations, S: Superficial Lacerations) Picture Courtesy [14].

With our study focusing further into the other facets like wound infection and the ultimate scar outcome, it was noted that overall scar satisfaction was found in 90% of Parents while only 4 complained of dissatisfaction. All of these 4 children had superficial cuts. Of these, 1 child had developed post procedural wound infection. This child had presented with a 2 cm laceration over the zygoma with gross contamination (tripped and fell in a playground that was muddy and dusty). This was primarily repaired with TA in ER. In retrospect, the reason for infection could have been gross contamination that may not have been adequately addressed and besides zygoma being an area of stretch and increased tension in addition to oblique orientation of wound, could have affected overall healing. The final scar outcome for this patient was poor with MSBSS score of 3 and parental dissatisfaction. For the rest 3 patients with scar dissatisfaction, 2 had a vertical wound orientation as a possible

cause of tension and poor scar outcome. Of these one had a MSBSS score of 5 and other had a score of 3. As for the 4th patient, the reason for poor scar could not be delineated. This is illustrated in Table 3.

Table 3: Showing details of dissatisfied patients and poor scar outcome

| Dis-satisfied Patients | Location | Orientation | Length | Contamination | Bleeding | MS-BSS |
|------------------------|-----------|-------------|--------|---------------|----------|--------|
| 1 | zygomatic | Oblique | 2cm | Present | Present | 3 |
| 2 | submental | Vertical | 2 cm | Absent | Present | 5 |
| 3 | frontal | Vertical | 1 cm | Absent | Absent | 3 |
| 4 | frontal | Horizontal | 3 cm | Absent | Present | 5 |

Conclusion

While most of the superficial facial cuts in children can be treated with irrigations and TA in the ER itself, the deeper cuts require a layered repair and if aided by TA can result in an optimum scar outcome. TA being a safe and needle less option can be used in the repair of linear lacerations, including those longer than 5 cm provided that the deeper component of the wound is repaired in layers after thorough wound treatment.

Conflicts of interests: None

References

- [1] Mattick A, Use of tissue adhesives in the management of paediatric lacerations, *Emerg. Med. J. EMJ.* 19:5 (2002) 382–385. DOI: 10.1136/emj.19.5.382.
- [2] Badeau A, Lahham S, Osborn M, Management of Complex Facial Lacerations in the Emergency Department, *Clin Pract Cases Emerg Med.* 1:3 (2017) 162–165. DOI: 10.5811/cpcem.2017.2.33270.
- [3] Al-Mubarak L, Al-Haddab M, Cutaneous Wound Closure Materials: An Overview and Update, *J Cutan Aesthetic Surg.* vol. 6:4 (2013) 178–188, 2013. DOI: 10.4103/0974-2077.123395.
- [4] Junaid S, Fmas A, Beigh S, Lone, A, Rashid, and Fiages, Comparison of Use of 2-Octyl Cyanoacrylate Tissue Adhesive and Standard Skin Sutures In Closure of Abdominal Incisions – A Prospective Randomized Controlled Study, 2018. /paper/Comparison-of-Use-of-2-Octyl-Cyanoacrylate-Tissue-%E2%80%93-Junaid Fmas/73ce71600f9afc94c1a82aa2c87acc40828abc13 (accessed Dec. 12, 2020). DOI: 10.9790/0853-1704120104.
- [5] Swaminathan SP, Jebasingh AV, Annadurai A, Mannan M, A study on comparison of conventional suturing and tissue adhesive (2-octyl cyanoacrylate) for skin closure in inguinal hernia surgeries, *Int Surg J.* 6:1 (2018) 188–192. DOI: 10.18203/2349-2902.isj20185470.
- [6] Kwon JY, Yun HG, Park IY, n-Butyl-2-cyanoacrylate tissue adhesive (Histoacryl) vs. subcuticular sutures for skin closure of Pfannenstiel incisions following cesarean delivery, *PLoS ONE.* 13:9 (2018). DOI: 10.1371/journal.pone.0202074.



- [7] Sebesta MJ, Bishoff JT, Octylcyanoacrylate Skin Closure in Laparoscopy, *JSLs*. 8:1 (2004) 9–14. PMID: 15991440.
- [8] Chawada MJ, Hajgude V, Efficacy of cyanoacrylate glue in operative wound closure, *Int. Surg. J.* 3:2 (2016) 792–796. DOI: 10.18203/2349-2902.isj20160659.
- [9] Chibbaro S, Tacconi L, Use of skin glue versus traditional wound closure methods in brain surgery: A prospective, randomized, controlled study, *J Clin Neurosci Off J Neurosurg Soc Australas.* 16:4(2009) 535–539. DOI: 10.1016/j.jocn.2008.08.004.
- [10] Watson DP, Use of cyanoacrylate tissue adhesive for closing facial lacerations in children, *BMJ.* 299:6706 (1989) 1014. PMID: 2511944
- [11] Bruns TB, Simon HK, McLario DJ, Sullivan KM, Wood RJ, Anand KJ, Laceration repair using a tissue adhesive in a children's emergency department, *Pediatrics.* 98:4 (1996) 673–675. PMID: 8885944
- [12] Osmond MH, Quinn JV, Sutcliffe T, Jarmuske M, Klassen TP, A Randomized, Clinical Trial Comparing Butylcyanoacrylate with Octylcyanoacrylate in the Management of Selected Pediatric Facial Lacerations, *Acad Emerg Med*, vol. 6:3(1999) 171–177. DOI: <https://doi.org/10.1111/j.1553-2712.1999.tb00151.x>.
- [13] Simon HK, McLario DJ, Bruns TB, Zempsky WT, Wood RJ, Sullivan KM, Long-term Appearance of Lacerations Repaired Using a Tissue Adhesive, *Pediatrics*, vol. 99: 2 (1997) 193–195. DOI: 10.1542/peds.99.2.193.
- [14] Lee JH, Jeon MS, Lee DL, Shin HK, Seul JH, Analysis of patients with facial lacerations repaired in the emergency room of a provincial hospital, *Arch Plast Surg.* 42:1 (2015) 34–39. DOI: 10.5999/aps.2015.42.1.34.

