

**Journal of Nobel Medical College**Available Online: [www.nepjol.info](http://www.nepjol.info), [www.nobelmedicalcollege.com.np](http://www.nobelmedicalcollege.com.np)

Volume 7, Number 2, Issue 13, July-December 2018, 15-19

**Original Article****Association between the clinical findings and chest radiographs in children with severe pneumonia aged 1 month to 5 years.****Vijay Kumar Sah\*, Arun Giri and Niraj Niraula***Department of Pediatrics, Nobel Medical College Teaching Hospital, Biratnagar, Nepal*Received: 12<sup>th</sup> March, 2018; Revised after peer-review: 22<sup>th</sup> April, 2018; Accepted: 18<sup>th</sup> May, 2018DOI: <https://doi.org/10.3126/jonmc.v7i2.22288>**Abstract****Background**

Pneumonia is the main cause of death among children under five years of age particularly in developing countries. According to the WHO, there are more than 15 million cases representing 7-13% of pneumonia cases annually which necessitate hospital admission due to their severity. There is paucity of data regarding the clinical spectrum and the epidemiology of severe pneumonia from eastern part of Nepal. It is important to understand the clinical spectrum and the epidemiology of severe pneumonia at local level to better define problem and to draw inferences for management and policy formulation.

**Material and Methods**

A hospital based retrospective observational study conducted at Department of Pediatrics and Neonatology, Nobel Medical College and Teaching Hospital, Biratnagar, Nepal. One hundred and forty four cases with a diagnosis of severe pneumonia were studied over a period of one year. All the cases from 1 month to 5 years of age fulfilling the standard WHO case definition of severe pneumonia were included in the study. A pre-designed semi-structured questionnaire was used to obtain the clinical profile and investigations.

**Results**

A total of 144 cases were studied and analyzed. The age range was from 1 month to 5 years. The mean age of the cases was 13.56 months. Majority of the cases belonged to age group of 1-6 months 40.27% (n=58). There was a male preponderance in our study comprising 58.3% (n=84) of males and 41.7% (n=60) of females. Fever and cough were the most common symptoms present in all cases, fever being present in 95.8% (n=136) cases and cough was present in 98.6% (n=142) cases. The most common radiological finding in our study was bronchopneumonia in 27.8% (n=40) cases followed by lobar pneumonia in 24.3% (n=35) cases and interstitial pneumonia in 18.8% (n=27) cases. Complications were present in 6.9% (n=10) cases and 22.2% (n=32) of the cases had no radiological abnormalities. Among the studied symptoms and signs of severe pneumonia, hurried breathing (p<0.001), wheeze (p=0.016), refusal of feeds (p=0.001), altered sensorium (p=0.006) and previous history of acute respiratory infections showed significant association with radiological abnormalities.

**Conclusion**

Children of severe pneumonia presenting with fast breathing, wheeze, altered sensorium, refusal of feeding and past history of acute respiratory infections showed significant association with abnormal chest radiographs.

**Key words:** Cough, fast breathing, Pneumonia, X-ray

---

**Introduction:**

Acute respiratory infections (ARI) are one of the commonest causes of death in children in developing countries. It is responsible for an estimated 4 million deaths worldwide. Almost all ARI deaths in young children are due to acute lower respiratory tract infections (ALRTI), mostly pneumonia [1]. Worldwide, pneumonia is a leading cause of death, killing 6.6 million children less than five years of age [2]. Children with infections of the lower respiratory tract (e.g. pneumonia, bronchiolitis) may demonstrate signs of compensation for impaired gas exchange (e.g. elevated respiratory rate chest indrawing), and those with severe ARI (e.g. associated with sepsis or hypoxemia) often display 'danger signs' (e.g. cyanosis, altered mental status). However, even among children with the same ARI subtype, clinical presentations are highly variable; for example, some children with chest radiograph-confirmed pneumonia do not have cough [3].

**Material and Methods:**

This is a retrospective study of children with severe pneumonia. Patients visiting the department of pediatrics, Nobel Medical College Teaching Hospital Biratnagar, Nepal fulfilling the inclusion criteria were enrolled in this study from March, 2017 – Feb, 2018. One hundred forty four cases were enrolled in the study. Of these 144 children; there were 84 males, and 60 females with mean age of 13.56 months. Children with congenital anomalies of heart and lungs, anatomical defects like cleft lip and cleft palate, immunocompromised states like human immunodeficiency virus infection (HIV) and infants less than one month of ages were not included in the study.

Diagnosis was made as per the WHO IMCI guidelines. Presence of any one of the general danger signs such as, convulsions; Inability to drink or feed or breastfeed; Lethargy or unconsciousness; Vomits everything; and/or any one of the following: Chest in-drawing or Stridor in calm child. Based on WHO ARI criteria, children were considered tachypnoeic if Respiratory rate (RR) > 60 in < 2 months, > 50 in 2 months – 1 yr and > 40 in 1 yr – 5 yrs.

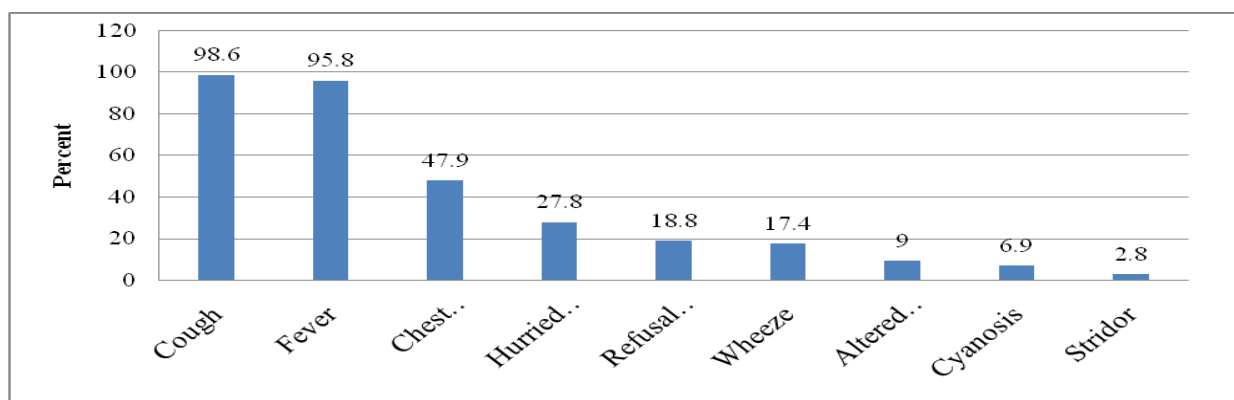
All the required statistical analysis such as sensitivity, specificity, negative predictive value, P value was calculated wherever necessary and data entry, statistical analysis was done by statistical package for social sciences (SPSS) version 23 for windows.

**Results:**

A total of 144 cases were studied and analyzed. The age range was from 1 month to 5 years. The mean age of the cases was 13.56 months. Majority of the cases belonged to age group of 1-6 months 40.27% (n=58) followed by age group of 7-12 months 27.08% (n=39). There was a male preponderance in our study comprising 58.3% (n=84) of males and 41.7% (n=60) of females. Fever and cough were the most common symptoms present in all cases, fever being present in 95.8% (n=136) cases and cough was present in 98.6% (n=142) cases. Chest indrawing was present in 47.9% (n=69) cases, followed by hurried breathing in 27.8% (n=40) cases, refusal of feeds in 18.8% (n=27) cases, wheeze in 17.4% (n=25) cases, altered sensorium in 9.0% (n=13) cases, cyanosis in 6.9% (n=10) cases and stridor was seen in 2.8% (n=4) cases.

**Table 1. Demographic Distribution of Severe Pneumonia Cases**

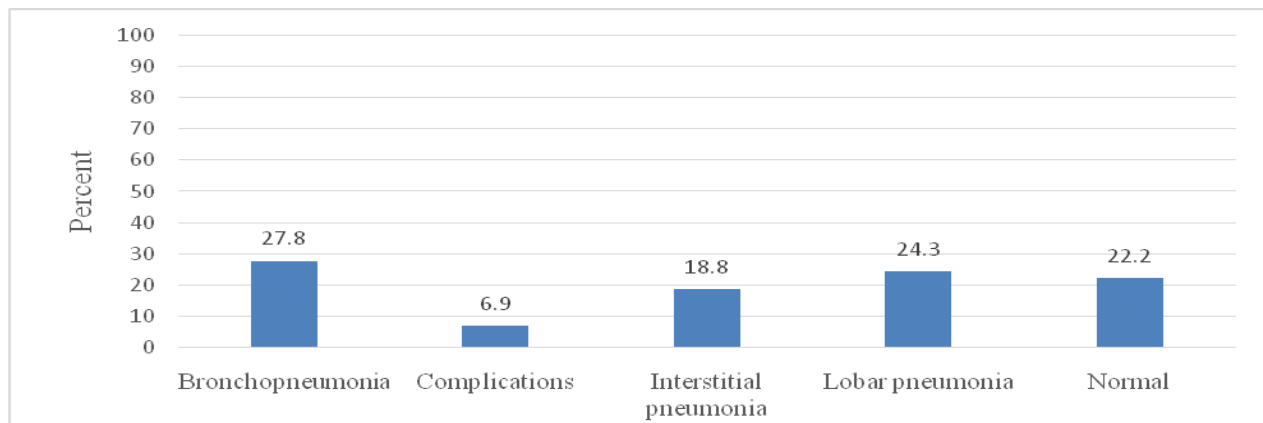
Age Group (months)	SEX				Total	Percent (%)
	Male	Percent (%)	Female	Percent (%)		
1-6	45	31.25%	13	9.02%	58	40.27%
7- 12	20	13.88%	19	13.19%	39	27.08%
13- 18	4	2.77%	5	3.47%	9	6.25%
19- 24	6	4.16%	10	6.94%	16	11.11%
25- 30	0	0.00%	1	0.69%	1	0.69%
31- 36	6	4.16%	7	4.86%	13	9.02%
37- 42	1	0.69%	0	0.00%	1	0.69%
43- 48	2	1.38%	1	0.69%	3	2.08%
49- 54	0	0.00%	0	0.00%	0	0.00%
55- 60	0	0.00%	4	2.77%	4	2.77%
<b>Total</b>	<b>84</b>	<b>58.3%</b>	<b>60</b>	<b>41.7%</b>	<b>144</b>	<b>100%</b>



**Figure 1: Clinical presentations of severe pneumonia**

The most common radiological finding in our study was bronchopneumonia in 27.8% (n=40) cases followed by lobar pneumonia in 24.3% (n=35) cases and interstitial pneumonia in 18.8% (n=27)

cases. Complications were present in 6.9% (n=10) cases and 22.2% (n=32) of the cases had no radiological abnormalities.



**Figure 2: Radiological features of severe pneumonia cases**

Among the studied symptoms and signs of severe pneumonia, fever ( $p=0.126$ ), cough ( $p=0.130$ ), chest indrawing ( $p=0.071$ ), stridor ( $p=0.135$ ) and cyanosis ( $p=0.199$ ) showed no significant association with the radiological abnormalities. However, fast breathing

( $p<0.001$ ), wheeze ( $p=0.016$ ), refusal of feeds ( $p=0.001$ ), altered sensorium ( $p=0.006$ ) and previous history of acute respiratory infections in children with severe pneumonia showed significant association with radiological abnormalities.

**Table 2: Association of the history and symptoms with radiological Abnormalities**

Test statistics										
	FEVER	COUGH	HURRIED BREATHING	CHEST INDRAWING	WHEEZE	STRIDOR	REFUSAL OF FEEDS	CYANOSIS	ALTERED SENSORIUM	PREVIOUS HISTORY OF ARI
<b>P value</b>	0.126	0.130	<0.001	0.071	0.016	0.135	0.001	0.199	0.006	0.017

**Discussion:**

Pneumonia is a silent global disease which is easily detected and treated effectively in developed countries but in developing countries it has very high morbidity and mortality. Various abbreviations e.g. ARI and LRTI used to in description of pneumonia, its familiar and benign image in the developed world has brought a wrong perception about this disease as a public health problem thus undermining it as a single, tractable problem. Research on pneumonia is can be highly effective, especially if this disease is solely dealt comprehensively [4].

In a study done by Joseph et al at union territory of Chandigarh, India noted fever (73.1%), cough (98.9%), hurried breathing (93.6%), chest indrawing (20.9%), wheeze (32.0%), altered sensorium (8%) and cyanosis in 0.8% of the cases which is similar to our study.<sup>[5]</sup>Likewise, clinical

profile of the patients of severe pneumonia done by Magda Yehia El Seify et al at a pediatric hospital of Ain Shams University of Egypt showed fever (92.2%), cough (74.4%), hurried breathing (90%), wheeze (48.9 %), and cyanosis in 24.4% of the patients [6].

Tallying with our study, a study conducted by Hamid et al in Pakistan showed bronchopneumonia in 49.3% cases followed by lobar pneumonia in 10.3%, complications in 1.2% and normal findings in 38.9% of the cases [7]. Similarly, a multicenter study identified normal chest radiographs in 46% cases, lobar consolidation in 15% cases, bronchopneumonia and interstitial pneumonia in 27% cases and mixed consolidation and infiltrates in 12% cases [8].

Chest radiography continues to be a valuable method for case identification that

is correlated to clinical signs of pneumonia. Yet, radiologic findings in cases of clinical pneumonia is likely to vary due to complex mix of etiology, healthcare-seeking patterns, antibiotic use, age, and underlying health conditions and malnutrition.

### Conclusion:

Younger children mostly between the ages of 1 to 6 months followed by ages of 7-12 months presented with severe pneumonia with higher incidence in males as compared to females. Fever and cough were the most common symptoms present in all cases. Most common radiological findings were bronchopneumonia followed by lobar pneumonia and interstitial pneumonia. There was significant association of presenting symptoms of fast breathing ( $p < 0.001$ ), wheeze ( $p = 0.016$ ), refusal of feeds ( $p = 0.001$ ), altered sensorium ( $p = 0.006$ ) and previous history of acute respiratory infections ( $p = 0.017$ ) in children with severe pneumonia with radiological abnormalities.

### References:

- [1] Wardlaw T, Salama P, Johansson EW, Mason E. Pneumonia: the leading killer of children. *Lancet* (London, England). 368:9541 (2006) 1048-50.
- [2] Puumalainen T, Quiambao B, Abucejo-Ladesma E, Lupisan S, Heiskanen-Kosma T, Ruutu P, et al. Clinical case review: a method to improve identification of true clinical and radiographic pneumonia in children meeting the World Health Organization definition for pneumonia. *BMC infectious diseases*. 8 (2008) 95.
- [3] A manual for doctors and other senior health workers. Acute Respiratory Infections in Children: Case Management in small hospitals in developing countries. A manual for doctors and other senior health workers, WHOARI905
- [4] Edmond K, Scott S, Korczak V, Ward C, Sanderson C, Theodoratou E, et al. Long term sequelae from childhood pneumonia; systematic review and meta-analysis. *PloS one*. 7:2 (2012) e31239.
- [5] Mathew JL, Singhi S, Ray P, Hagel E, Saghafian-Hedengren S, Bansal A, et al.

- Etiology of community acquired pneumonia among children in India: prospective, cohort study. *Journal of Global Health*. 5:2 (2015).
- [6] El Seify MY, Fouda EM, Ibrahim HM, Fathy MM, Hussein Ahmed AA, Khater WS, et al. Microbial Etiology of Community-Acquired Pneumonia Among Infants and Children Admitted to the Pediatric Hospital, Ain Shams University. *European Journal of Microbiology & Immunology*. 6:3 (2016) 206-14.
- [7] Hamid M, Qazi SA, Khan MA. Clinical, nutritional and radiological features of pneumonia. *JPMA The Journal of the Pakistan Medical Association*. 46:5(1996) 95-9.
- [8] Fancourt N, Deloria Knoll M, Baggett HC, Brooks WA, Feikin DR, Hammitt LL, et al. Chest Radiograph Findings in Childhood Pneumonia Cases From the Multisite PERCH Study. *Clinical infectious diseases : an official publication of the Infectious Diseases Society of America*. 64 (2017) S262-s70.