

## ROLE OF MRI IN EVALUATION OF POST-TRAUMATIC KNEE INJURIES: A PROSPECTIVE STUDY

Sanju Rawal,<sup>1</sup> Rajendra KC,<sup>1</sup> Subhash Chandra Yadav,<sup>1</sup> Bardan Oli,<sup>1</sup> Sadhan Mukhi,<sup>1</sup> Krishna Thapa,<sup>1</sup> Darshana Dhakal,<sup>1</sup> Narayan Bohara<sup>1</sup>

### ABSTRACT

### INTRODUCTION

The knee joint is the largest and most complex joint in the human body. Therefore it is often affected by trauma. Magnetic Resonance Imaging (MRI) is a non-invasive imaging modality that provides detailed images of the soft tissue structures of the knee joint. The objective of this study was to evaluate MRI findings in patients with post-traumatic knee joint injuries.

### MATERIAL AND METHODS

This prospective study was carried out using a 3.0 Tesla MRI (Magnetom Lumina) scanner in the Department of Radiodiagnosis and Medical Imaging at Universal College of Medical Sciences & Teaching Hospital, Bhairahawa, Nepal. The study included 128 patients with post-traumatic knee injuries, from September 2023 to February 2024. Data were analyzed using SPSS version 20.

### RESULTS

In this study of 128 participants, 57.81% were male and 42.19% were female, with a mean age of 38.60±13.05 years. The majority of MRI findings were medial meniscus tear (51.56%), followed by anterior cruciate ligament tear (46.09%), medial collateral ligament sprain (44.53%), lateral meniscus tear (39.84%), lateral collateral ligament sprain (33.59%), and posterior cruciate ligament tear (17.97%). Our study also revealed various grades of collateral ligament injuries, including the medial and lateral ligaments. There were 59.65% of cases with a grade I medial collateral ligament sprain, followed by grade II at 33.33% and grade III at 7.02%. The grade I and grade II lateral collateral ligament sprains were 62.79% and 37.21%, respectively.

### CONCLUSION

MRI is a non-invasive and valuable diagnostic modality that can provide an accurate diagnosis. It is often preferred over arthroscopy.

### KEYWORDS

Knee joint, Ligament injuries, Magnetic resonance imaging

1. Department of Radiodiagnosis and Medical Imaging, Universal College of Medical Sciences, Bhairahawa, Nepal

<https://doi.org/10.3126/jucms.v12i01.65537>

#### For Correspondence

Dr. Sanju Rawal  
Department of Radiodiagnosis and Medical Imaging  
Universal College of Medical Sciences  
Bhairahawa, Nepal  
Email: sanjurawalchhetri1983@gmail.com

## INTRODUCTION

The knee joint is a large, hinge-type synovial and weight-bearing joint, composed of the femur, tibia, and patella. It consists of two joints, the tibiofemoral joint (between the femur and tibia) and the patellofemoral joint (between the patella and femur).<sup>1-3</sup> The Anterior Cruciate Ligament (ACL), Posterior Cruciate Ligament (PCL), Medial Collateral Ligament (MCL), and Lateral Collateral Ligament (LCL) are the four major ligaments responsible for knee stabilization. Additionally, there are two menisci, the medial and lateral meniscus, which serve as shock absorbers between the femur and tibia. These ligaments work together to provide stability and flexibility to the knee, allowing it to flexion, extension, and slight rotation.<sup>4</sup> Traumatic injuries to these ligaments can lead to knee instability, pain, and immobility, often associated with sports activities and accidents.<sup>5,6</sup> Magnetic Resonance Imaging (MRI) has emerged as the preferred non-invasive method for evaluating post-traumatic knee injuries. It provides comprehensive insight into the soft tissues, ligaments and cartilage with excellent contrast and details about the type and severity of the injury. This imaging modality plays a crucial role in accurately and promptly diagnosing post-traumatic knee injuries, including meniscus tears and ligament injuries, and is now widely used instead of invasive diagnostic arthroscopy.<sup>7,8</sup> Recent studies have shown that musculoskeletal imaging is one of the fastest-growing fields for MR imaging applications, making the development of advanced imaging tools for joints of increasing clinical significance.<sup>9</sup> The objective of this study was to evaluate MRI findings in patients with post-traumatic knee joint injuries.

## MATERIAL AND METHODS

This prospective study was conducted in the Department of Radiodiagnosis and Medical Imaging, Universal College of Medical Sciences and Teaching Hospital, Bhairahawa, Nepal, from September 2023 to February 2024. The study included 128 patients with knee joint injuries who were referred to the Radiodiagnosis Department for MRI. The MRI scans were performed using a 3.0 Tesla Magnetom Lumina MR scanner from Siemens System, with the patient lying supine on the MRI table. The knee was positioned in extension and externally rotated at an angle of 10-15 degrees for better ACL imaging. The MRI scan included the following sequences: Proton Density (PD)-Transverse (tra)-Turbo Spin-echo (tse), T2W-tra-tse, T2W-me2d-tra-gre, PD-tse-Sagittal (sag), T2W-tse-sag, T2W-de3d-sag, T1W-tse-sag, PD-tse-cor, and T1W-tse-cor. The study obtained ethical clearance from the Institutional Review Committee of UCMS-TH, with reference number UCMS/IRC/046/23. Both verbal and written consents were taken from the participants. The sample size was calculated by cohort formula:  $n = z^2 p (1-p) / e^2$ .

Where,  $z=1.96$  at 95% Confidence Interval,  $p=96.92\%$  prevalence of MRI abnormal findings,<sup>6</sup>  $q=1-p$ ,  $e=0.03$  (3% marginal error). Putting these values into the above formula, the calculated total sample size was approximately 127.4, but we included 128 patients in our study.

### Inclusion criteria

- Patients of any age group, either male or female with post-traumatic knee injuries referred from OPD or IPD.

### Exclusion criteria

- Patients who did not give consent for the study
- Patients with a previous history of knee joint operation or related procedures.
- Patients with a history of any chronic knee joint pathology, history of claustrophobia or any contraindication to MRI.

Data were entered into Microsoft Excel and then analyzed using Statistical Package for the Social Sciences (SPSS) version 20. The data was expressed in numerical values and percentages, including the mean and standard deviation (SD).

## RESULTS

A total of 128 patients participated in the study, with 74 males (57.81%) and 54 females (42.19%). The age range of the participants was between 12 and 78 years, with a mean age of  $38.60 \pm 13.05$  years. Notably, knee injuries were observed to occur with varying frequencies on different sides. Specifically, the right knee exhibited a frequency of 67 (52.34%), the left knee had a frequency of 48 (37.5%), and the bilateral knee had a frequency of 13 (10.16%). A study revealed that road accidents were the leading factor in knee injuries, making up 64.84% of cases. Fall from heights were the second most common cause at 24.22%, followed by sport-related injuries at 10.94%. (Table 1)

**Table 1. Distribution of patient demographic characteristics, n=128**

Characteristics	Frequency (n)	Percentage (%)
<b>Age (Years)</b>		
<20	8	6.25
21-30	30	23.44
31-40	38	29.69
41-50	26	20.31
>50	26	20.31
<b>Mean age±SD</b>	38.60 ± 13.05	
<b>Gender</b>		
Male	74	57.81
Female	54	42.19
<b>Symptoms</b>		
Pain	97	75.78
Swelling	27	21.09
Limitation of movement	48	37.5
<b>Mode of injury</b>		
Road accident	83	64.84
Fall from height	31	24.22
Sport	14	10.94
<b>Side of injury</b>		
Right knee	67	52.34
Left knee	48	37.5
B/L knee	13	10.16

**Table 2. Distribution of MRI findings in patients, n=128**

MRI Findings	Frequency (n)	Percentage (%)
Normal MRI findings	5	3.91
Anterior cruciate ligament tear	59	46.09
Posterior cruciate ligament tear	23	17.97
Medial meniscus tear	66	51.56
Lateral meniscus tear	51	39.84
Medial collateral ligament sprain	57	44.53
Lateral collateral ligament sprain	43	33.59

Out of all the participants, 5 patients (3.91%) did not show any findings, while the rest had different findings. The most common injury was a tear in the medial meniscus, seen in 66 cases (51.56%). This was closely followed by a tear in the anterior cruciate ligament, with 59 cases (46.09%). The least common tear was found in the posterior cruciate ligament, with only 23 cases (17.97%). (Table 2)

**Table 3. Distribution of various grades of collateral ligaments**

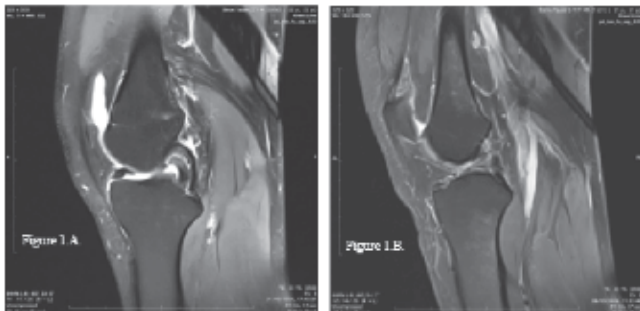
Grading	MCL (n=57)		LCL (n=43)	
	Frequency (n)	Percentage (%)	Frequency (n)	Percentage (%)
Grade I	34	59.65	27	62.79
Grade II	19	33.33	16	37.21
Grade III	4	7.02	0	0

Table 3 shows the different grades of collateral ligaments (medial and lateral). Among them, Grade I MCL sprain was observed in 34 cases (59.65%), followed by Grade II in 19 cases (33.33%) and the least number of cases had Grade III (7.02%). In comparison, LCL had Grade I in 62.79% of cases and Grade II in 37.21% of cases, with no instances of Grade III.

**Table 4. Distribution of type of ACL and PCL Tear**

Types of Tear	Frequency (n)	Percentage (%)
ACL, n=59	Partial	18
	Complete	41
PCL, n=23	Partial	9
	Complete	14

The majority of cases revealed that 41 (69.49%) had a complete tear of the anterior cruciate ligament injury, with partial tears following behind. Interestingly, 14 (60.87%) cases showed a complete tear of the posterior cruciate ligament, with partial tears in 9 (39.13%) cases. (Table 4)



**Figure 1. Illustrates an MRI of the knee, specifically a sagittal proton density (PD) weighted image. Fig. (A) Shows a bucket handle tear of the medial meniscus, while fig. (B) Shows a complete tear of the anterior cruciate ligament.**

## DISCUSSION

This study aimed to evaluate MRI findings in patients with post traumatic knee injuries. The study revealed that the age of the participants varied between 12 and 78 years, with mean age of  $38.60 \pm 13.05$  years. Among the participants, 74 (57.81%) were male and 54 (42.19%) were female. These demographic values were compared to the findings of Kumar I et al,<sup>10</sup> who reported a mean age of  $37.4 \pm 14.6$  years for their patients, and Thapa M et al,<sup>6</sup> where 48 (73.8%) were male and 17 (26.2%) were female. The present study revealed that out of the 128 patients, 83 (64.84%) experi-

enced injuries due to road accidents, which is slightly higher compared to the study conducted by Sharma D et al,<sup>11</sup> where 30% of the injuries were caused by roadside accidents, and Moorthy J et al,<sup>12</sup> where 22.6% of the injuries were due to road traffic accidents (RTA). However, the another type of incident was slightly lower than that reported by Moorthy J et al<sup>12</sup> and Sharma D et al.<sup>11</sup>

In this study, a wide range of MRI diagnoses were observed. The most common findings included medial meniscus tear in 66 cases (51.56%), followed by anterior cruciate ligament tear in 59 cases (46.09%), medial collateral ligament sprain in 57 cases (44.53%), lateral meniscus tear in 51 cases (39.84%), lateral collateral ligament sprain in 43 cases (33.59%), and posterior cruciate ligament tear in 23 cases (17.97%). These findings were compared to previous studies conducted by Hetta W et al,<sup>9</sup> where the majority of knee injuries were anterior cruciate ligament tears at 60%, followed by meniscus tears at 40% and collateral ligament injuries at 32%; and Thapa M et al,<sup>6</sup> where 56.9% had anterior cruciate ligament tears, followed by 26.2% with medial meniscus tears and 12.3% with posterior cruciate ligament tears; Bari AA et al,<sup>13</sup> where the majority of incidences were anterior cruciate ligament tears at 74.7%, followed by medial meniscus tears at 47.3% and lateral meniscus tears at 28.2%. Despite these comparisons, our study showed that the majority of injuries were medial meniscus tears rather than anterior cruciate ligament tear. Our study revealed that 41 cases (69.49%) in the total participants had a complete ACL tear, while 18 cases (30.51%) had a partial ACL tear. Furthermore, 14 cases (60.87%) had a complete PCL tear, and 9 cases (39.13%) had a partial PCL tear. These findings are consistent with a study done by Umap R et al.,<sup>14</sup> which found 40% complete PCL tears, 40% partial PCL tears, and 20% grade I sprain of the PCL.

In our study, we found that participants experienced different grades of collateral ligament sprains. The medial collateral ligament sprain was classified as grade I in 54 cases (59.65%), grade II in 19 cases (33.33%), and grade III in 4 cases (7.02%). In contrast, the lateral collateral ligament sprain was classified as grade I in 27 cases (62.79%) and grade II in 16 cases (37.21%). These findings indicate a slightly higher prevalence compared to a study conducted by Umap R et al,<sup>14</sup> where only 1 patient had a grade I MCL sprain and 3 patients had a grade I LCL sprain.

Our study has a few limitations. We conducted a descriptive study in which only MRI was used because knee arthroscopy though is performed in UCMS-TH, however at sparse intervals which would have increased our study duration significantly. All the data were assessed solely based on MRI findings.

## CONCLUSION

MRI is widely preferred as the most effective noninvasive technique used instead of arthroscopy to evaluate and diagnose knee injuries, particularly ligament and meniscus tears. Most ligament and meniscus injuries can be accurately diagnosed using MRI. The main injuries identified in our study are medial meniscus tear, anterior cruciate ligament tear, and several others.

## ACKNOWLEDGEMENT

Authors would like to extend their appreciation to our residents, technologists, and MIT students of UCMS-TH for their constant supports and help in collecting data.

## CONFLICT OF INTEREST

None

## REFERENCES

1. Sathish A, Jayanthan S, Priya K. MRI Assessment of Painful Knee Joint in Meenakshi Mission Hospital and Research Centre, Madurai, Tamil Nadu: A Cross-Sectional Study. *International Journal of Contemporary Medicine, Surgery and Radiology*. 2019 Sept 23;4(3):248-252.
2. Refaat M, El Shazly E, Elsayed A. Role of MR Imaging in Evaluation of Traumatic Knee Lesions. *Benha Medical Journal*. 2020 Oct 1;37:77-86.
3. MacMahon PJ, Palmer WE. A biomechanical approach to MRI of acute knee injuries. *American Journal of Roentgenology*. 2011 Sep;197(3):568-77.
4. Saeed IO. MRI evaluation for post-traumatic knee joint injuries. *J Nurs Health Sci*. 2018;7(2):48-51.
5. Van Oudenaarde K, Swart NM, Bloem JL, Bierma-Zeinsstra SM, Algra PR, Koes B, Verhaar J, Nelissen RG, Bindels PJ, Luijsterburg PA, Reijnen M. Post-traumatic knee MRI findings and associations with patient, trauma, and clinical characteristics: a subgroup analysis in primary care in the Netherlands. *British Journal of General Practice*. 2017 Dec 1;67(665):e851-8.
6. Thapa M, Thapa S, Chhetri PK. The Role of magnetic resonance imaging in traumatic knee injury. *Nepal Journal of Medical Sciences*. 2020 Feb 15;5(1):53-61.
7. Ali MM, Aboud MA, El-Feshawy MS, El-Gyoshy AM. Role of magnetic resonance imaging in evaluation of postoperative knee surgery. *The Egyptian Journal of Hospital Medicine*. 2018 Jul 1;72(8):4973-6.
8. Chaudhuri S, Joshi P, Goel M, No RH, Ramnagari A. Role of MRI in evaluation of traumatic knee injuries. *Journal of Evolution of Medical and Dental Sciences*. 2013 Feb 18;2(7):765-71.
9. Hetta W, Niazi G. MRI in assessment of sports related knee injuries. *The Egyptian Journal of Radiology and Nuclear Medicine*. 2014 Dec 1;45(4):1153-61.
10. Kumar I, Prajapati N, Reshi AM. Post traumatic internal derangement of knee evaluation at 3.0 Tesla MRI. *International Journal of Contemporary Medicine Surgery and Radiology*. 2020;5(2):17-20.
11. Sharma D, Sharma A, Talwar N, Mittal P, Garg S, Airon D. Role of MRI evaluation in knee injuries. *J Evolution Med Dent Sci*. 2020 Apr 27;9(17):1435-41.
12. Moorthy J, Radhan P, Kumar V, Thangam V, Gadiraju B. Clinical and MRI profile of patients with knee injuries and correlation of MRI with arthroscopic findings. *International Journal of Research in Orthopaedics*. 2023 Mar;9(2):352.
13. Bari AA, Kashikar SV, Lakhkar BN, Ahsan MS. Evaluation of MRI versus arthroscopy in anterior cruciate ligament and meniscal injuries. *Journal of Clinical and Diagnostic Research: JCDR*. 2014 Dec;8(12):14.
14. Umap R, Anurag B, Bagale S, Shattari N. Evaluation of traumatic knee joint injuries with MRI. *Int J Contemp Med Surg Radiol*. 2018 Jul;3(3):78-81.