

## PLEOMORPHIC ADENOMA OF PALATE: A CASE REPORT

Nagendra Shris,<sup>1</sup> Ravish Mishra,<sup>1</sup> Deepak Yadav,<sup>1</sup> Laxmi Kandel,<sup>1</sup> Shahid Ali,<sup>1</sup> Hemanta Raj Pathak<sup>1</sup>

### ABSTRACT

### INTRODUCTION

Pleomorphic adenoma is one of the most common benign salivary gland tumor affecting the major salivary glands mainly parotid gland of approx. 80% but infrequently the minor salivary glands of palate of approx. 7%. Salivary gland tumors are rare accounting only 2–3% of tumors occurring in head and neck region. The majority of minor salivary gland tumors are malignant in nature. The most common sites for minor salivary gland where pleomorphic adenoma arises are the palates followed by lips and cheek. This case report presents a case of pleomorphic adenoma of minor salivary gland of palate treated successfully by wide surgical excision with 1 cm healthy margin with uninvolved anatomical barrier under general anesthesia.

### KEYWORDS

Pleomorphic adenoma, Palate, Minor salivary gland

1. Department of Oral and Maxillofacial Surgery, Universal College of Medical Sciences, Bhairahawa, Nepal

<https://doi.org/10.3126/jucms.v11i03.61619>

---

#### For Correspondence

Dr. Nagendra Shris  
Department of Oral and Maxillofacial Surgery  
Universal College of Medical Sciences  
Bhairahawa, Nepal.  
Email: nagendrashris@gmail.com

## INTRODUCTION

Pleomorphic adenoma is a benign mixed tumor composed of epithelial and myoepithelial cells arranged in various morphological patterns, demarcated from the surrounding tissues by a fibrous capsule. The epithelial part arises from the duct-lining epithelium, while the mesodermal part arises from the myoepithelial cells, which are the contractile cells surrounding the tubules draining individual acini. It derives its name from the architectural pleomorphism which is seen by light microscopy. It is also known as “mixed tumor, salivary gland type”, which describes its pleomorphic appearance as opposed to its dual origin from epithelial and myoepithelial elements. Pleomorphic adenoma accounts about 70-75 % of all salivary gland tumors.<sup>1</sup>

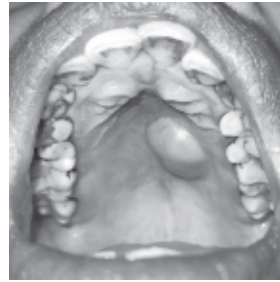Intraorally, pleomorphic adenoma affects the palate most commonly (42.63%), followed by the lip (10%), buccal mucosa (5.5%), retromolar area (0.7%), and the floor of the mouth.<sup>2</sup> Pleomorphic adenomas may occur at any age, most common during 4th -6th decades of life. It has female predilection (60%) than male (40%). Pleomorphic adenoma tumors are painless, well-delineated and covered with normal mucous membrane. Sometimes superficial mucosal ulcerations are observed.<sup>3</sup>

The term pleomorphic shows the diversity of the histology of the tumor. The essential components are the capsule, epithelial and myoepithelial cells, and mesenchymal or stromal elements. The capsule varies in thickness and presence. Cells of epithelial origin give rise to ductal structures and are intermixed with mesenchymal component that is mucoid/myxoid, cartilaginous, or hyalinized.<sup>4</sup>

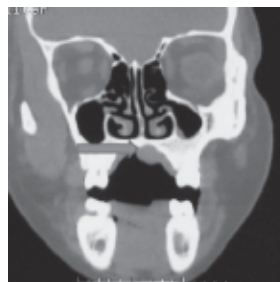The potential risk of the pleomorphic adenoma becoming malignant is about 6%. Pleomorphic adenoma has clinical features, such as distant metastases and malignant transformation, which are inconsistent with the benign phenotype in local sites. The treatment of pleomorphic adenoma is surgical excision. Enucleation of pleomorphic adenoma is not suitable because higher chance for recurrence.<sup>5</sup>

## CASE REPORT

A 34 year female patient was presented to Department of Oral and Maxillofacial Surgery in Universal College of Medical Sciences, complaining of swelling on left posterior palatal region since 1.5 month. Patient was apparently well 1.5 months back when she noticed swelling at left posterior palate. Initially swelling was small in size of approx. maize grain then it gradually increased to 3cm × 2cm of present size. It was oval in shape, sessile, smooth mass with well defined margin, non-fluctuant and non-tender on palpation.



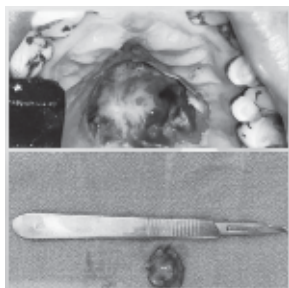**Figure 1.** Clinical photograph showing well defined mass over left palate on computed tomography (CT) scan, there was no obvious bony erosion.



**Figure 2.** Coronal view of computed tomography scan showing soft tissue mass on left palate with no bony erosion

In FNAC, well fixed Giemsa stained cellular smears showed variable sized clusters of benign myoepithelial cells arranged in loose cohesive clusters and few scattered singly embedded in myxoid stroma. Individual myoepithelial cells are round to oval, few show mild anisonucleosis with dense nuclear chromatin and moderate to abundant amount of cytoplasm. Many myoepithelial cells are plasmacytoid in appearance. Also seen are benign ductal epithelial cells scattered singly. Individual ductal epithelial cells are round to oval with dense nuclear chromatin and moderate amount of cytoplasm. All these features suggestive of benign salivary gland neoplasm.

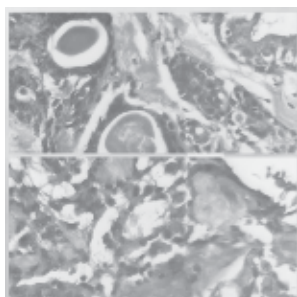
Wide surgical excision with 1 cm healthy margin with uninvolved anatomical barrier of the lesion was made using the surgical blade. Excision of the mass was done under general anesthesia. The whole tumor mass was separated out with careful dissection and the whole encapsulated tumor mass was excised along with the mucoperiosteum and the eroded bone of the palate with the boundary line localized in the surrounding healthy tissue. Hemostasis was achieved by use of electrosurgery. The mass was sent for histopathological examination. The result of the histopathological examination after the tumor excision confirmed the diagnosis of pleomorphic adenoma. The patient's postoperative course was uneventful and patient was kept on regular follow up.



**Figure 4.** Clinical photograph showing wide local excision of lesion

The given H and E stained section showed encapsulated tumor containing both epithelial and mesenchymal component. At 10x magnification shows epithelial cells present in the form of sheets and strands and arranged in ductal and tubular pattern. There is presence of plasmacytoid cells which are round to polygonal cells having eccentric nuclei and eosinophilic cytoplasm. Plasmacytoid cells are surrounding duct like spaces filled with eosinophilic coagulum in few areas. There is presence of fibromyxoid stroma with areas of hyalinization and squamous metaplasia along with keratin formation. There is also presence of chondroid areas and salivary gland. Areas of hemorrhage and fat cells are also seen. At 40x magnification showed stellate cells with cytoplasmic processes and it also confirms the features seen in the low power view.

All these features are suggestive of PLEOMORPHIC ADENOMA.



**Figure 5.** H and E section at 40x magnification showing ductal pattern with eosinophilic coagulum and stellate cells with cytoplasmic processes

## DISCUSSION

Tumors occurring in the small salivary glands account for about 20–40% of all salivary gland tumors, but to be precise about 22%, according to Spiro. The smaller the salivary glands that are affected, they more likely trigger a malignant tumor. Mixed tumor of the minor salivary glands affects mostly in 4<sup>th</sup> - 6<sup>th</sup> decades, with a predominance in females.<sup>1</sup> Pleomorphic adenoma is the most common salivary gland neoplasm and accounts for about 60% of all salivary gland neoplasms. 7% of these tumors arise in the minor salivary glands. The most common site for minor salivary gland where pleomorphic adenoma arises is the palate, followed by the lip. According to Gupta P et al,<sup>1</sup> the hard palate is the most commonly affected location in the oral cavity. Infrequently, heterotopic localization of pleomorphic adeno-

mas has been described in paranasal sinuses, middle ear, tongue, and alimentary and respiratory tracts.<sup>4</sup> Clinically pleomorphic adenoma presents as slow growing, asymptomatic, unilateral firm mass that may become large if left untreated. When originating in the minor salivary glands, mostly it occurs on the soft and hard palate due to the highest concentration of salivary glands in that region and is typically a firm or rubbery sub mucosal mass without any kind of ulceration on or at the surrounding area.<sup>1</sup>

Pleomorphic adenomas usually occur in adults with a peak incidence in the fourth and sixth decades of life, which mainly affect women. Two different hypotheses have been reported, referred to as the multiclonal hypothesis and monoclonal hypothesis. Multiclonal hypothesis proposes that 2 or more stem cells of mesenchymal and epithelial origins give rise to the different components within the pleomorphic adenoma. The monoclonal hypothesis proposes that a single totipotent stem cell gives rise to 2 or more cells that undergo divergent differentiation.<sup>4</sup>

Histologically, it is highly variable in appearance. Classically it is biphasic and is characterized by a mixture of polygonal epithelial and spindle-shaped myoepithelial elements in a variable background stroma that may be mucoid, myxoid, cartilaginous or hyaline. Epithelial elements may be arranged in duct-like structures, sheets, clumps or interlacing strands and consist of polygonal, spindle or stellate-shaped cells. Areas of squamous metaplasia and epithelial pearls may occur. The tumor is not enveloped, but is surrounded by a fibrous pseudocapsule of varying thickness. The tumor extends through normal glandular parenchyma in the form of finger-like pseudopodia, but this is not a sign of malignant transformation. The “cellular” type of pleomorphic adenoma is one in which the epithelial element predominates, whereas the “myxoid” type is composed mostly of a myxomatous or myxochondromatous mesenchymal-like element. The “mixed” type is a classic form. Distinctive epithelial cell types include spindle, clear, squamous, basaloid, cuboidal, plasmacytoid, oncocytic, mucous and sebaceous.<sup>3</sup>

It is formed of acini, cords and thin strands of epithelial cells suspended in a stroma, which often has a myxomatous appearance. Immunohistochemical stains for cytokeratin, S 100 protein and 'galial fibrillary acidic protein' (GFAP) are reliable methods of evaluating component cell types in pleomorphic adenoma. S100 and GFAP are also useful for separation of pleomorphic adenoma from adenoid cystic carcinoma.<sup>6</sup>

The differential diagnosis for this case are palatal abscesses, odontogenic and non-odontogenic cysts, soft tissue tumors such as fibroma, lipoma, neurofibroma, neurilemmoma, and lymphoma as well as other salivary gland tumors. The diagnosis of pleomorphic adenoma is established on the basis of history, physical examination, cytology and histopathology. Computed tomography scan and MRI can provide appropriate information on the location and size of the tumor and its extension to surrounding superficial and deep structures.<sup>1</sup>

Standard treatment of pleomorphic adenoma in the palate is surgical excision with the removal of periosteum or bone if it is involved. Enucleation of pleomorphic adenoma is not suitable because of recurrence, which is due to incomplete surgical resection of the lesion. Recurrences of pleomorphic

adenoma increase the possibility of malignant transformation. Carcinoma ex-pleomorphic adenomas usually arise from a coexisting or previously excised pleomorphic adenoma.<sup>4</sup>

Complete excision with a wide margin is essential in the treatment of pleomorphic adenoma. The treatment of PA is essentially surgical excision. Because these tumors are radioresistant, radiation therapy is contraindicated. Though these benign tumors are well encapsulated, resection of the tumor with an adequate margin of grossly normal surrounding tissue is necessary to prevent local recurrence because these tumors are known to have microscopic pseudopod-like extensions into the surrounding tissue due to "dehiscence" in the capsule. The recurrence of PA is attributed to implantation from capsule rupture, islands of tumor tissue left behind after surgery, and the multicentric nature of PA. Therefore, long-term follow-up is required.

## CONCLUSION

Pleomorphic adenoma is a rare benign minor salivary gland tumor in the palate, usually seen in adult patients. The most common symptom is a slow-growing, painless submucosal mass on the hard palate. Definitive diagnosis lies in the histopathological examination. The treatment choice of pleomorphic adenoma is wide surgical excision with 1 cm healthy margin with uninvolved anatomical barrier.

## ACKNOWLEDGEMENT

We want to show our gratitude towards all the staffs and interns posted in the Department of Oral and Maxillofacial Surgery.

## CONFLICT OF INTEREST

None

## REFERENCES

1. Gupta P, Gupta M. Rare Case Report: Young Male Hard Palate Pleomorphic Adenoma. *Indian J Otolaryngol Head Neck Surg.* 2021;73(4):510–3.
2. Gothwawal AK, Kamath A, Pavaskar RS, Satoskar SK. Pleomorphic adenoma of the palate: A case report. *J Clin Diagnostic Res.* 2012;6(6):1109–11.
3. Rahnama M, Orzedala-Koszel U, Czupkhallo L, Lobacz M. Pleomorphic adenoma of the palate: A case report and review of the literature. *Wspolczesna Onkol.* 2013;17(1):103–6.
4. Erdem MA, Çankaya AB, Güven G, Olgaç V, Kasapoğlu Ç. Pleomorphic adenoma of the palate. *J Craniofac Surg.* 2011;22(3):1131–4.
5. Iida Y, Serizawa M, Mukaigawa T, Kamijo T, Nakajima T, Asakura K, et al. Molecular profile of a pleomorphic adenoma of the hard palate: A case report. *Medicine (Baltimore).* 2020;99(29):e21207.
6. Shaaban H, Davenport PJ, Bruce J. Recurrent pleomorphic adenoma of the palate in a child. *Br J Plast Surg.* 2001;54(3):245–7.