

SPONTANEOUS PNEUMOTHORAX ASSOCIATED WITH COVID-19 INFECTION: A CASE SERIES

Sanjog Kandel,¹ Manoj Karki,¹ Bidhata Rayamajhi,¹ Shatdal Chaudhary,¹ Niraj Kumar Jaiswal,¹ Narayan Gautam²

ABSTRACT

Coronavirus disease 2019 (COVID-19) is an infectious disease caused by the severe acute respiratory syndrome coronavirus 2 (SARS-COV-2) virus, which mostly affects the respiratory system. As a result of the inflammatory response, mortality and morbidity are linked to fast clinical deterioration. Pneumothorax is a rare complication in COVID-19 patients that might exacerbate the patient's hypoxia and necessitate rapid treatment.

It is critical to evaluate alternate diagnosis and repeat imaging in individuals with SARS-CoV-2 who have seen an abrupt worsening. We present a case series of four individuals who had spontaneous pneumothorax despite having no other risk factors for pneumothorax other than recent COVID-19 infection.

KEYWORDS

COVID-19, Pneumothorax, Intercoastal chest drain

1. Department of Internal Medicine, Universal College of Medical Sciences, Bhairahawa
2. Department of Biochemistry, Universal College of Medical Sciences (UCMS), Bhairahawa

<https://doi.org/10.3126/jucms.v10i02.51364>

For Correspondence

Dr. Sanjog Kandel
Department of Internal Medicine
Universal College of Medical Sciences
Bhairahawa, Nepal.
Email: drsanjograj@gmail.com

INTRODUCTION

Since its first outbreak in December 2019 in Wuhan, Hubei Province, China, corona virus disease (COVID-19) has presented clinicians with many unprecedented hurdles in terms of presentation, treatment regimens, and sequelae. The sickness, which is recognized to be a communicable disease, began in Wuhan, China, and spread worldwide after that.¹

Its common variety of symptoms range from fever, cough, dyspnea, myalgia, pharyngitis, fatigue, and loss of smell and/or taste to less common symptoms such as sore throat, rhinorrhea, headache, chest pain, dizziness, abdominal pain, diarrhea, nausea/vomiting, although some of those infected can be asymptomatic. Multiple organ systems have been directly affected by the novel virus.²

Spontaneous pneumothorax is an uncommon but life-threatening consequence that occurred in 1% of COVID-19 cases and 13% of COVID-19 infection in mechanically ventilated patients.^{3,4} It describes the presence of gas in the pleural space that develops without any prior thoracic damage. Secondary spontaneous pneumothorax is a consequence of preexisting lung disease.^{5,6} Primary spontaneous pneumothorax occurs without any history of the underlying pulmonary disease. Pneumothorax has also been connected to patients with Middle East respiratory syndrome corona virus (MERS-CoV) infection and severe acute respiratory syndrome.⁷

We present five examples of primary pneumothorax caused by covid-19 in non-ventilated patients in order to demonstrate that it can develop in patients without any underlying or pre-existing lung diseases who have not received positive breathing pressure.

The goal of our research is to look at the clinical and radiological results of individuals with this type of presentation, as well as other coexisting problems (such as pneumothorax) in covid-19 patients who develop acute hypoxia and clinically worsen with time.

CASE 1

A 36-year-old man was discovered to be Covid-19 positive using RT-PCR. Three days ago, he was taken to the emergency room from a rural hospital with chest pain, cough, shortness of breath, and a high-grade fever, respiratory rate of 28 breaths/min, temperature of 101° F, blood pressure of 110/70 mmHg, and SpO₂ of 80 percent on room air.

Bilateral basal crepitations were found on chest examination, and a chest radiograph indicated bilateral lower zone infiltrates, indicating Covid-19 pneumonia.

WBC 21,200/mm³, D-dimer 3.2 mg/L, C-reactive protein (CRP) 151.3 mg/L, Lactate Dehydrogenase (LDH) 922 U/L, and Ferritin 1883 g/L were among the test findings.

With the addition of IV corticosteroids, the patient required 10 L of oxygen to maintain a normal level of saturation.

He complained of right-sided chest pain and shortness of

breath the next day, requiring 15 L of oxygen to maintain 95 percent saturation. A significant right-sided pneumothorax with mediastinal displacement to the left (Figure 1-a) was discovered on a repeat chest x-ray (CXR).

A computerised tomography (CT) chest confirmed pneumothorax (Figure 1-b). Intercoastal chest drain was inserted on right side. Patient stayed few days in intensive care unit (ICU) with chest tube in-situ and later on shifted in ward after being SARS CoV-2 negative; subsequently chest tube removed.

Five days later he complained chest pain on right side and a chest radiograph confirmed a large right sided pneumothorax again. Intercostal chest tube was inserted again on right side. A repeat CT chest showed bilateral pneumatoceles/bullous disease with pneumatocele/bullae in right and left lower lobes respectively. After a two-week period, the right lung gradually enlarged and the drain was withdrawn. With no lingering complaint, the patient was discharged on room air.

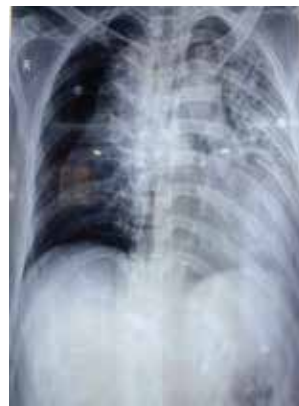

Figure 1-a. CXR showing bilateral lung infiltrates and right sided pneumothorax.

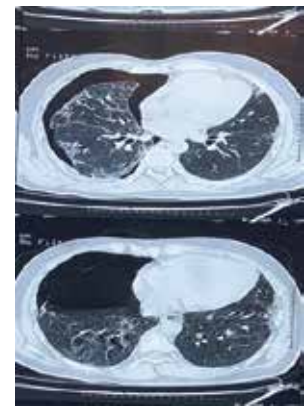


Figure 1-b. CT chest showing pneumothorax in right hemithorax

CASE 2

A 58-year-old woman with hypothyroidism who was taking medication arrived to the emergency room with a three-day history of fever, productive cough, shortness of breath, diarrhea, widespread exhaustion, and myalgia. Her temperature was 99.8°F when she was admitted, and her breathing rate was 30 breaths per minute. Her medical background was unremarkable, and she was a non-smoker.

She required 8 L of oxygen to maintain saturations of 94%. Her chest examination revealed bilateral crepitations. Investigation shows CRP of 43.6 mg/L, D-dimer 4.6 mg/L, WBC 3700 cells/mm³, LDH of 922 U/L and a Ferritin of 1883 μg/L. She tested RT-PCR positive for Covid-19. Her CXR (Figure 2-a) revealed bilateral lower zone non-homogenous infiltrates. She required 10 L of oxygen to maintain oxygen saturation and IV corticosteroids were added in treatment.

She improved gradually and was weaned off from oxygen over the next few days; however, on Day 7 she developed a right sided pleuritic pain and worsening shortness of breath with stable vital signs and oxygen saturations. A CT scan of

the chest revealed a significant right-sided pneumothorax, right basal segment consolidation, and multifocal bilateral ground glass opacities in both lungs (Figure 2-b).

Subsequently a chest drain on the right side was inserted, resulting in full resolution of the pneumothorax in 9 days when the drain was removed and the patient was discharged with advice for follow up.

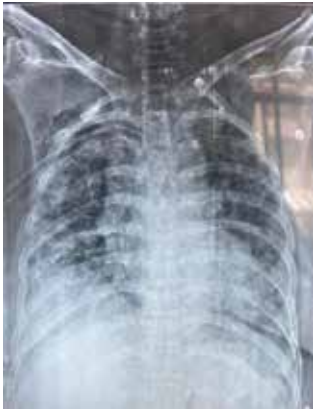

Figure 2-a. CXR showing bilateral lung infiltrates

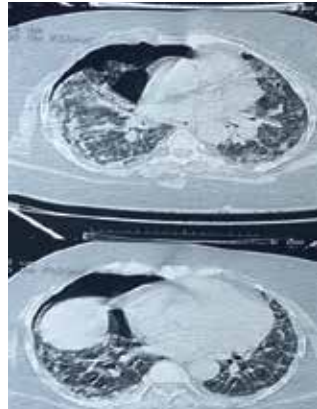


Figure 2-b. CT chest showing pneumothorax in right hemithorax with bilateral diffuse central and peripheral ground-glass, consolidative opacities

CASE 3

A 53-year-old man presented to the emergency department with a worsening cough and shortness of breath for the past five days, as well as an on-and-off temperature.

He was a rickshaw puller by trade and a smoker. His medical history was ordinary in the past.

On examination, he was tachypnoeic with a respiratory rate of 25 breaths/min, afebrile, blood pressure 130/90 mmHg and hypoxic with oxygen saturations of 87% on room air. The physical examination was uneventful in general.

Chest examination revealed bilateral basal crepitations with the chest radiograph showing bilateral lower zone infiltrates confirmed with a diagnosis of Covid-19 pneumonia with positive RT-PCR test. Lab investigations showed a WBC of 13,300 cells/mm³, D-dimer of 0.9 mg/L, CRP of 4.0 mg/L, LDH of 937 U/L and a Ferritin of 312.20 µg/L. To sustain his oxygen SpO₂ level, he needed 8L of oxygen. He complained of right-sided chest pain and shortness of breath three days after admission to COVID-ICU, requiring 15 L of oxygen to maintain 95 percent saturations.

An x-ray of the chest revealed a significant right-sided pneumothorax with mediastinal displacement to the left (Figure 3-a). A CT scan of the chest revealed pneumothorax (Figure 3-b). On the right side, an intercostal chest drain was implanted. Patient was admitted to the ICU with a chest tube in place and later transferred to the ward after testing negative for COVID and having the chest

tube withdrawn. The right lung gradually expanded, and after 10 days, the drain was removed. There was no residual complaint after the patient was discharged on room air.

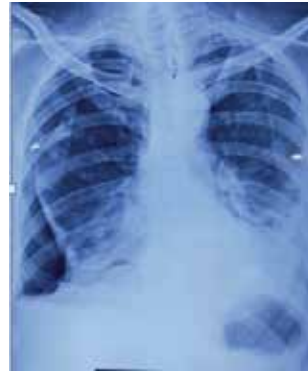

Figure 3-a. CXR showing bilateral lung infiltrates and right side pneumothorax

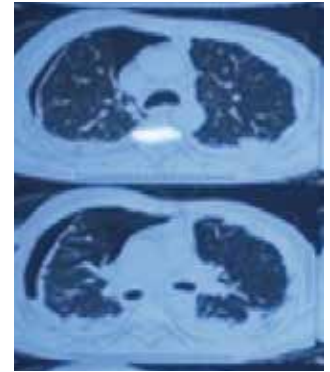


Figure 3-b. CT chest showing pneumothorax in right hemithorax with bilateral diffuse ground-glass opacities

CASE 4

A 43-year-old man with a 3-day history of productive cough, shortness of breath, headache, nonspecific fatigue, and myalgia presented to the emergency department.

His temperature was 99.8°F and his respiratory rate was 32 breaths per minute when he was admitted. His past medical was unremarkable and he never smoked.

He required 5 L of oxygen to maintain saturation initially. His chest examination revealed bilateral crepitations. Blood workup showed a CRP of 50.6 mg/L, D dimer 15.0 mg/L, WBC 9000 cells/mm³, LDH of 1600 U/L and a Ferritin of 2200 µg/L. He tested RT-PCR positive for Covid-19 and required 10 L of oxygen to maintain SpO₂.

He was first treated according to Covid-19 recommendations before receiving IV corticosteroids.

He improved gradually and was weaned off oxygen over the next few days; however, on Day 6, he developed a right sided pleuritic pain and worsening shortness of breath with stable vital signs and oxygen saturation. Chest X ray revealed right sided pneumothorax (Figure 4-a) and intercostal chest tube inserted. A CT chest revealed a right sided pneumothorax, consolidation of the right basal segments, and multifocal bilateral ground glass opacities in both lungs (Figure 4-b). A chest drain was placed for 12 days and was removed after full resolution of pneumothorax. The patient was then discharged home with a follow up.

CASE 5

A 38-year-old man went to the emergency room with fever and cough for four days and shortness of breath for two days. He was a farmer by trade and never smoked. His medical history was ordinary in the past.

On examination, he was tachypnoeic, breathing at a rate of 24 breaths per minute, with a temperature of 101°F, a blood pressure of 120/90 mmHg, and oxygen saturations of 80% on room air. The physical examination was uneventful in general.

The chest radiograph revealed bilateral lower zone infiltrates (Figure 5-a), and the chest examination revealed bilateral basal crepitations. With RT PCR positive for COVID 19, the patient was eventually diagnosed as having COVID-19.

Investigations showed a WBC of 9,200 cells/mm³, D-dimer of 3.7 mg/L, CRP of 284.5 mg/L, LDH of 1122 U/L and IL-6 of 19.70, serum urea 67 mg/dl, creatinine 1.4 mg/dl. There was no growth on sputum culture, and sputum for AFB was negative in all three samples.

He required 10 liters of oxygen to maintain oxygen saturation, as well as IV corticosteroids. After 8 days in the hospital, the patient tested negative for COVID and was transferred to a post-COVID care unit, where he received rehabilitative care and treatment. The patient was provided a

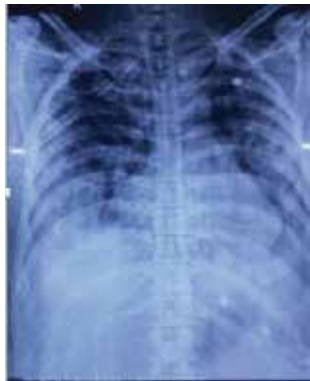

Figure 4-a. CXR showing bilateral middle and lower zone consolidation

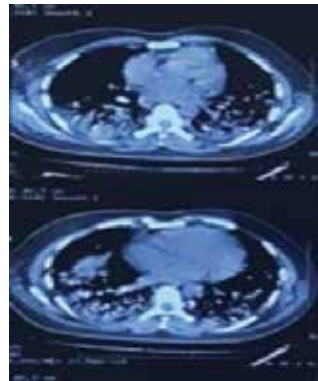


Figure 4-b. CT chest showing pneumothorax in right hemithorax with bilateral diffuse ground-glass opacities

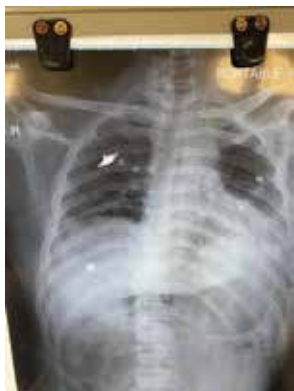

Figure 5-a. CXR showing left-sided pneumothorax

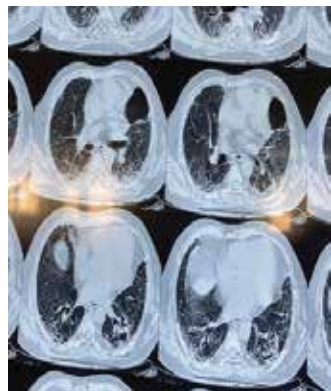


Figure 5-b. CT chest showing pneumothorax in left hemithorax with bilateral diffuse ground-glass opacities

variety of oxygen augmentation options. As the patient's condition improved, oxygen was reduced to nasal prongs, and he was transferred to a general medical unit.

He came in after a few days with chest pain on the left side of his chest, an x-ray chest revealed similar findings, the chest discomfort persisted, and he was later advised to get a CT scan (Figure 5-b). After 68th day of inpatient treatment, patient was discharged with advice of immediate follow up for acute onset chest pain and shortness of breath.

DISCUSSION

A series of five cases of spontaneous pneumothorax with covid-19 pneumonia was presented. All of the patients in our study had no prior lung illness and were not on positive pressure ventilation.

This case report aims to highlight the importance of urgent chest radiography and prompt clinical examination in patients with COVID-19 who develop a sudden increase in requirement of oxygen and become acutely tachypnoeic in order to rule out the possibility of pneumothorax and other acute complication. Spontaneous pneumothorax has also been reported as a late complication after the resolution of the infection.⁸ Pneumothorax can occur in patients receiving either noninvasive or invasive modalities of ventilation likely due to the fragility of the airways weakened by the virus and barotrauma induced by oxygen supplementation devices. Pneumothorax has been commonly associated with other causes of severe acute respiratory distress syndrome caused by pressure and volume induced alveolar rupture but its causation with covid-19 has not been established. Although the pathophysiology of pneumothorax in covid-19 pneumonia is unclear, the pre-existing pulmonary cysts or pneumatoceles can be a contributing factor in such patients, especially in those who need positive pressure ventilation.^{9,10}

By rupturing this cavity into the pleural space, pulmonary embolism with subsequent pulmonary infarction and cavity formation can also be a contributory cause.¹¹ Another possible factor is elevated intrathoracic pressure from the persistent Cough leading to rupture of peripheral inflamed alveoli into the pleural cavity leading to pneumothorax¹² Likewise, the presence of pneumothorax has been associated with the appearance of pneumatoceles and bullae related to pneumonia, which are usually not observed in the early stages of the disease.¹³ In a series of cases in china, the interval between dyspnea and pneumothorax ranged from 15 to 40 days, without any patient having chronic pulmonary comorbidities.¹⁴

CONCLUSION

When a patient with COVID-19 infection develops type 1 respiratory failure and develops acute hypoxia, a spontaneous pneumothorax should always be considered as a differential diagnosis. It can happen at any point during the disease's progression. Prompt diagnosis and immediate intervention can avert further deterioration of the patient.

REFERENCES

- Hameed M, Jamal W, Yousaf M, Thomas M, Haq IU, Ahmed S, Ahmad M, Khatib M. Pneumothorax in covid-19 pneumonia: a case series. *Respiratory Medicine Case Reports*. 2020 Jan 1;31:101265.
- Chung M, Bernheim A, Mei X, Zhang N, Huang M, Zeng X, Cui J, Xu W, Yang Y, Fayad ZA, Jacobi A. CT Imaging Features of 2019 Novel Coronavirus (2019-nCoV) *Radiology*. 2020 Apr; 295 (1): 202–207.
- Chen X, Zhang G, Tang Y, Peng Z, Pan H. The coronavirus diseases 2019 (COVID-19) pneumonia with spontaneous pneumothorax: a case report. *BMC Infectious Diseases*. 2020 Dec;20(1):1-5.
- Chopra A, Al-Tarbsheh AH, Shah NJ, Yaqoob H, Hu K, Feustel PJ, Ortiz-Pacheco R, Patel KM, Oweis J, Kozlova N, Zouridis S. Pneumothorax in critically ill patients with COVID-19 infection: incidence, clinical characteristics and outcomes in a case control multicenter study. *Respiratory medicine*. 2021 Aug 1;184:106464.
- Baumann MH, Strange C, Heffner JE, Light R, Kirby TJ, Klein J, Luketich JD, Panacek EA, Sahn SA. Management of spontaneous pneumothorax: an American College of Chest Physicians Delphi consensus statement. *Chest*. 2001 Feb 1;119(2):590-602.
- Lesur O, Delorme N, Polu JM, Fromaget JM, Bernadac P. Computed tomography in the etiologic assessment of idiopathic spontaneous pneumothorax. *Chest*. 1990 Aug 1;98(2):341-7.
- Liu J, Zheng X, Tong Q, Li W, Wang B, Sutter K, Trilling M, Lu M, Dittmer U, Yang D. Overlapping and discrete aspects of the pathology and pathogenesis of the emerging human pathogenic coronaviruses SARS-CoV, MERS-CoV, and 2019-nCoV. *Journal of medical virology*. 2020 May;92(5):491-4.
- Nunna K, Braun AB. Development of a large spontaneous pneumothorax after recovery from mild COVID-19 infection. *BMJ Case Reports CP*. 2021 Jan 1;14(1):e238863.
- Martinelli AW, Ingle T, Newman J, Nadeem I, Jackson K, Lane ND, Melhorn J, Davies HE, Rostron AJ, Adeni A, Conroy K. COVID-19 and pneumothorax: a multicentre retrospective case series. *European Respiratory Journal*. 2020 Nov 1;56(5).
- Zhou C, Gao C, Xie Y, Xu M. COVID-19 with spontaneous pneumomediastinum. *The Lancet Infectious Diseases*. 2020 Apr 1;20(4):510.
- Bompard F, Monnier H, Saab I, Tordjman M, Abdoul H, Fournier L, Sanchez O, Lorut C, Chassagnon G, Revel MP. Pulmonary embolism in patients with COVID-19 pneumonia. *European Respiratory Journal*. 2020 Jul 1;56(1).
- Joynt GM, Antonio GE, Lam P, Wong KT, Li T, Gomer-sall CD, Ahuja AT. Late-stage adult respiratory distress syndrome caused by severe acute respiratory syndrome: abnormal findings at thin-section CT. *Radiology*. 2004 Feb;230(2):339-46.
- Sun R, Liu H, Wang X. Mediastinal emphysema, giant bulla, and pneumothorax developed during the course of COVID-19 pneumonia. *Korean Journal of Radiology*. 2020 May;21(5):541.
- Wang XH, Duan J, Han X, Liu X, Zhou J, Wang X, Zhu L, Mou H, Guo S. High incidence and mortality of pneumothorax in critically ill patients with COVID-19. *Heart & Lung*. 2021 Jan 1;50(1):37-43.