

## VASCULAR INJURY AND ITS MANAGEMENT: EXPERIENCE AT UNIVERSAL COLLEGE OF MEDICAL SCIENCES, BHAIRAHAWA, NEPAL

Santosh Shah<sup>1</sup>, Rajesh Poudel<sup>2</sup>, Tika Ram Bhandari<sup>2</sup>, Damber Bikram Shah<sup>2</sup>, Ghanshyam Sigdel<sup>2</sup>, Kailash Chandra<sup>2</sup>

### ABSTRACT

#### INTRODUCTION:

Vascular trauma is a common life-threatening injury leading to serious consequences if not timely and efficiently managed. Although they represent less than 3% of all injuries, they deserve special attention because of their severe complications. The aim of this study was to analyze the causes of injury, presentations, surgical (recent) approaches, outcomes, and complications of vascular trauma.

#### MATERIALS & METHODS:

This was a retrospective analysis performed over 6 months. From December 2015 to May 2016, 12 patients were included in the study and were operated upon for peripheral vascular injuries. Diagnosis was made by physical examination as well as with hand Doppler alone or in combination with Doppler scan. Primary vascular repair was carried out whenever possible; however, if it was not possible, an interposition vein graft was placed.

#### RESULTS:

Of the total 12 patients who sustained major vascular injuries during this period, 9 sustained injuries to the upper limb vessels, 3 had injuries of the lower limb vessels. Trauma with sharp object was the cause in 4 cases, blunt trauma was the cause in 4 cases and rupture pseudoaneurysm was the cause in 2 cases and ruptured aneurysm was the cause in 2 cases. Of the 12 patients, 12 patients were successfully managed by vascular reconstruction without any residual disability. There were 8 male patients (66.67%) and 4 female patients (33.33%), and their ages ranged from 16–60 years (mean 35 years).

#### CONCLUSION:

Patients who suffer vascular injuries should be transferred to vascular surgery centers as soon as possible. Decisive management of peripheral vascular trauma will maximize patient survival and limb salvage. Priorities must be established in the management of associated injuries, and delay must be avoided when ischemic changes are present.

**KEYWORDS:** Management, Vascular trauma

1. Lecturer, Department of Surgery, Cardiothoracic & Vascular Surgery (CTVS), Universal College of Medical Sciences, Bhairahawa, Nepal
2. Department of Surgery, Universal College of Medical Sciences, Bhairahawa, Nepal

---

#### For correspondence:

Dr. Santosh Shah, M.Ch (CTVS)  
Lecturer,  
Cardiothoracic & Vascular Surgery (CTVS)  
Department of Surgery,  
Universal College of Medical Sciences,  
Bhairahawa, Nepal  
Email: santshah@hotmail.com

**INTRODUCTION:**

Trauma has become a public health problem in many parts of the world, with vascular trauma being an important component. A great majority of these injuries are due to penetrating traumas, such as stab and gunshot wounds and road traffic accidents and also ruptured aneurysm<sup>1</sup>. If not recognized and treated rapidly, injuries to major arteries, veins, and nerves may have disastrous consequences resulting in loss of life or the limb. Vascular injuries can be classified as: contusions, intimal disruptions, punctures, lateral disruptions, transactions, arteriovenous fistulae (A-Vfistulae), and pseudoaneurysm<sup>2</sup>. During the first and second world wars, important knowledge had been gained both in diagnosis and treatment of vascular injuries; however, vascular reconstructive methods were mainly introduced during the Korean and Vietnamese wars with tremendous progress<sup>3</sup>. Consequently, a dramatic decrease in the amputation rate was achieved. Although successful treatment of major arterial injuries may be life-saving and may allow limb salvage and restoration of function<sup>4</sup>, return of function is often related to the presence of concomitant injury to peripheral nerves<sup>5</sup>.

The lower extremities are involved in two-thirds of all patients with vascular injuries<sup>6</sup>. Trauma patients with penetrating firearm injuries may have multiple injuries, complicating routine approaches to vascular repair; therefore, endovascular intervention offers a new and less invasive technique for the treatment of acute traumatic vascular injuries<sup>7</sup>. Although the management of acute arterial injuries has been established, there is little interest in repairing acute venous injuries, and an effort to repair major venous injuries should be made<sup>8</sup>. In broad terms, a vascular injury takes priority because of the ongoing limb ischemia or hemorrhage. However, when there is an unstable fracture, for example, an open book fracture of the pelvis, it should be stabilized first.

A dislocated joint should also be reduced first before arterial injuries are assessed and managed. However, with all other stable orthopedic fractures without gross deformities, the vascular injury should be repaired first to minimize ischemic time. When limb viability is threatened and orthopedic stabilization is imperative, the use of temporary plastic or silastic shunts may be employed to reestablish perfusion to the distal extremity<sup>9</sup>. The present study aims to analyze the causes of injury, presentations, surgical (recent) approaches, outcomes, and complications of vascular trauma.

**MATERIALS & METHODS:**

The study was carried out at Universal College of Medical Sciences and teaching hospital between December 2015 and May 2016. All patients with vascular trauma were included. The protocol was revised for management of these patients. Initial resuscitation including management of shock, securing hemostasis by application of a tourniquet for few minutes or by application of vascular bulldog clamps, and management of other life threatening injuries was performed simultaneously. A detailed history was taken, and all patients were examined to exclude any associated injuries. The patients were subjected to ultrasound examinations, Doppler studies, and radiographs. All patients were monitored during the postoperative period for impending ischemia, hemorrhage, sepsis, and other possible complications. All patients were followed up for 30 days after discharge from the hospital.

**RESULTS:**

The patients in the present study consisted of 8 males (66.67%) and 4 females (33.33%), with a mean age of 35 years (range 16–60 years). The mechanisms of injuries sustained by them are shown in Table 1. Two patients (16.66%) presented with ischemia, Six patients had bleeding (50%), Two had presentations of vascular injuries with pseudoaneurysms (16.66%), and two patients had ruptured aneurysm (16.66%). The presentation of patient with injured vessels in these patients is shown in Table 2 and distribution of injured vessel is shown in diagram 1. End-to-end anastomosis after the resection of injured segment was the most frequently used single technique of arterial repair in 9 patients (66.66%). Other techniques used included excision and ligation for aneurysm and pseudo aneurysm. All patients with pseudo aneurysm and aneurysm, underwent excision of the pseudo aneurysm/aneurysm and repair of the vessel. The patients received analgesia and sedation before the procedure.

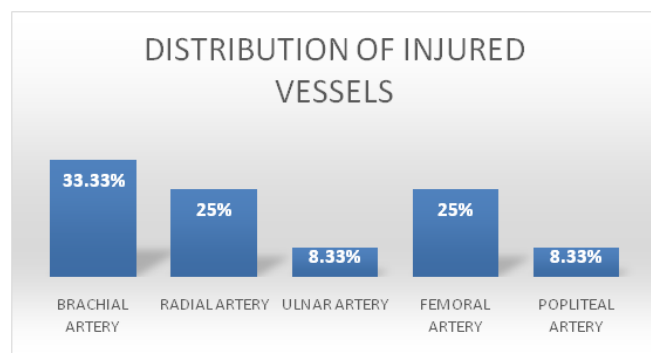
Table 1: Mode of Vascular Injury

S.N	Mode of vascular injury	No. of cases
1	Sharp injury	5
2	Blunt trauma	4
3	Aneurysm	2
4	Pseudo aneurysm	2

Table 2: Presentation of Patients of Vascular Injury

SN	Presentation	No. of cases	Percentage
1	Ischaemia	2	16.66%
2	Haemorrhage	6	50.00%
3	Pseudoaneurysm	2	16.66%
4	Aneurysm	2	16.66%

Diagram 1: Distribution of Injured Vessels



## DISCUSSION:

Injuries to peripheral vessels have a potential to cause morbidity and mortality if they are not recognized and treated promptly. Strict criteria need to be followed to make the diagnosis and hence help avoid the incidence of complications of limb amputation, contractures, and even death. The use of the classical six P's of ischemia and the 'Hard and Soft' signs<sup>10</sup> in the assessment of injuries to limbs will help to identify these injuries promptly to avoid complications. The high incidence of patients with vascular injuries who presented late with A-V fistulae, false aneurysms, and gangrene shows that there was failure of adherence to these protocols at diagnosis of these injuries by the first attending doctors. Most of the injuries seen were penetrating in nature and should therefore not have posed any diagnostic problems. The time lapse between injury and treatment is of critical importance for the outcome. In our study, we found that 6 h was the critical limit that determined the outcome. Patients reporting within 6 h of injury had better overall results as compared with those presenting after 6 h<sup>11</sup>. The complication rate in emergency revascularization has been reported in different studies to be between 10% and 18 percent. In our study, 10% of the patients developed various complications, which is compatible with international standards<sup>12, 13</sup>. Prompt vascular repair and

attention to associated injuries result in minimum morbidity and zero mortality. In our study, we dealt with vascular injuries and associated problems in one session, and these patients did very well at the follow-up. Vascular reconstruction is carried out by different means and in different ways depending upon the nature and extent of vascular injury, size and caliber of the injured vessel, its area of supply, nature of the concurrent trauma, general condition of the patient, and the available resources, including expert vascular services. In modern-day surgeries, 95% of limbs can successfully be salvaged by early surgical intervention and revascularization<sup>14</sup>; in our study, the salvage percentage was 90%

## CONCLUSION:

Investigations in stable patients and operative exploration in unstable or bleeding patients remain the accepted standards of care. The management plan and priorities in treatment for the patient must be decided and agreed upon in the presence of all the various teams involved. Every effort should be made to achieve revascularization within 6 hr. Open surgical techniques, endovascular intervention, or combined techniques can be used. Endovascular management of vascular injuries is expanding in use, whether alone or in combination with open surgery (hybrid technique). An endovascular approach to the treatment of vascular injuries has the advantages of being minimally invasive and being able to treat vessels that are difficult to access through conventional surgery. Patients presenting with late or crush injuries are usually treated by amputation.

## REFERENCES:

- 1 Mattox KL, Hirshberg A. Vascular trauma. In: Haimovici H, Ascer E, Hollier LH, Strandness DE, Towne JB, editors. *Haimovici's vascular surgery*. 4th ed. USA: Blackwell Science; 1996. pp. 480–496.
- 2 Creagh TA, Broe PJ, Grace PA, Bouchier-Hayes DJ. Blunt trauma induced upper extremity vascular injuries. *J R Coll Surg Edinb* 1991; 36:158–160.
- 3 Weaver FA, Hood DB, Yellin AE. Vascular injuries of the extremities. In: Rutherford RB, editor. *Vascular surgery*. 5th ed. (2000) W.B. Saunders Company; pp. 862–871.
- 4 Feliciano DV, Bitondo CG, Mattox KL, Burch JM, Jordan GL Jr, Beall AC Jr, DeBakey ME. Civilian trauma in the 1980s. A 1-year experience with 456 vascular and cardiac injuries. *Ann Surg* 1984; 199:717–724.

- 5 Razmadze A. Vascular injuries of the limbs: a fifteen-year Georgian experience. *Eur J Vasc Endovascular Surg* 1999; 18:235–239.
- 6 Andrikopoulos V, Antoniou I, Panoussis P. Arterial injuries associated with lower-extremity fractures. *Cardiovasc Surg* 1995; 3:15–18.
- 7 Rich NM, Leppäniemi A. Vascular trauma: a 40-year experience with extremity vascular emphasis. *Scand J Surg* 2002; 91:109–126.
- 8 Yelon JA, Scalea TM, Mullins RJ, Kerstein M, Shackford S, Hirsch E, et al. Venous injuries of the lower extremities and pelvis: repair versus ligation. *J Trauma* 1992; 33:532–538.
- 9 Elias K, Willy C, Engelhardt M. How much competence in emergency vascular surgery does a modern trauma surgeon need? Experiences regarding deployment as a military surgeon. *Unfallchirurg* 2010; 113:122–126.
- 10 Hunt CA, Kingsley JR, Maull KI. Vascular injuries of the upper extremity. *South Med J* 2000; 93:466–468.
- 11 Nassoura ZE, Ivatury RR, Simon RJ, Jabbour N, Vinzons A, Stahl W. A reassessment of Doppler pressure indices in the detection of arterial lesions in proximity penetrating injuries of extremities: a prospective study. *Am J Emerg Med* 1996; 14:151–156.
- 12 Cuschieri A, Steele RJC, Moossa AR. *Essential surgical practice*. 4th ed. (2000) Heinemann, Italy: Butterworth; 38–66.
- 13 Hood DB, Weaver FA, Yellin AE. Changing perspectives in the diagnosis of peripheral vascular trauma. *Semin Vasc Surg* 1998; 11:255–260.
- 14 Starnes BW, Bruce JM. Popliteal artery trauma in a forward deployed Mobile Army Surgical Hospital: lessons learned from the war in Kosovo. *J Trauma* 2000; 48:1144–1147.