

Case Report

Median Arcuate Ligament Syndrome: A Case Report

Akash Chitrakar, Nirajan Subedi, Ramesh Singh Bhandari

Department of Surgery, Maharajgunj Medical Campus, Tribhuvan University Teaching Hospital, Nepal

Correspondence: Akash Chitrakar, MS Resident, Department of Surgery, MMC, Tribhuvan University Teaching Hospital, Nepal

E-mail: akashfloyd@gmail.com

Abstract

Median arcuate ligament (MAL) syndrome results from extrinsic compression of the celiac axis and or celiac ganglion by the MAL and diaphragmatic crura. A seventy five years lady presented with post prandial epigastric pain for 6 months. She had undergone considerable investigations for other diagnoses before an abdominal computed tomography (CT) revealed median arcuate ligament impinging celiac artery at its origin. She successfully underwent laparotomy and release of median arcuate ligament.

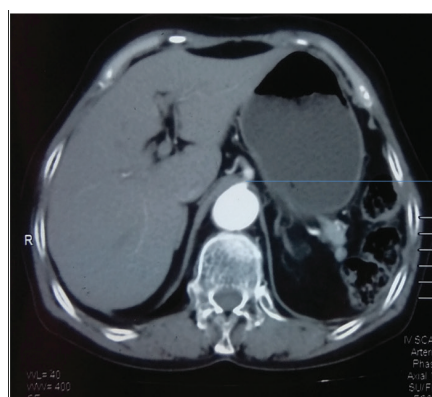Keywords: Celiac artery compression syndrome; Dunber syndrome; Median arcuate ligament (MAL) syndrome

Introduction

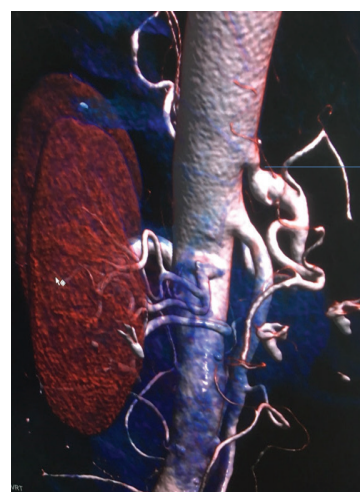
MAL syndrome is a rare vascular anomaly and has an incidence of about 2 per 100,000 in general population(1). MAL is a band of fibrous tissue that connects the diaphragmatic crura surrounding the aortic hiatus. It presents with constellation of symptoms including chronic post prandial epigastric pain, anorexia, weight loss and diarrhea. MAL syndrome is more prevalent in thin built women (4:1 female to male ratio) between age group of 30 to 50(1). It is commonly a diagnosis of exclusion with patients undergoing extensive evaluation for other diagnoses including upper endoscopy, abdominal ultrasound and abdominal CT. The management is aimed at relieving the compression on the celiac artery to restore adequate blood flow and neurolysis to address chronic pain.

Case Report

A 75 year old lady presented in our OPD with complaints of pain in the epigastric region for past 6 months which was aggravated by taking meals. She also gave history of weight loss and loss of appetite for past 3 months. Her physical examination was unremarkable. All the lab reports were within normal limits. She had been initially overlooked as a case of acid peptic disease. After her symptoms persisted she had undergone upper endoscopy and abdominal ultrasound, both of which were normal. Finally, a decision to perform a CECT abdomen and pelvis was made which revealed median arcuate ligament of the diaphragm impinging on celiac trunk immediately after its origin.



Abdominal CT scan showing compression at the level of origin of celiac artery



3D reconstruction image showing abrupt narrowing at the origin of celiac artery

Figure 1: CECT abdomen showing median arcuate ligament impinging the origin of celiac artery

The patient was planned for open approach and release of median arcuate ligament. Intraoperatively there were dense adhesions along the course of celiac artery with a fibrous band causing constriction at its origin. Common hepatic artery, left gastric artery and splenic artery were isolated and taken in contro and adhesions were separated. Median arcuate ligament was divided and released upto 4 cm in cephalad direction. The calibre of the celiac artery was increased immediately following the release.

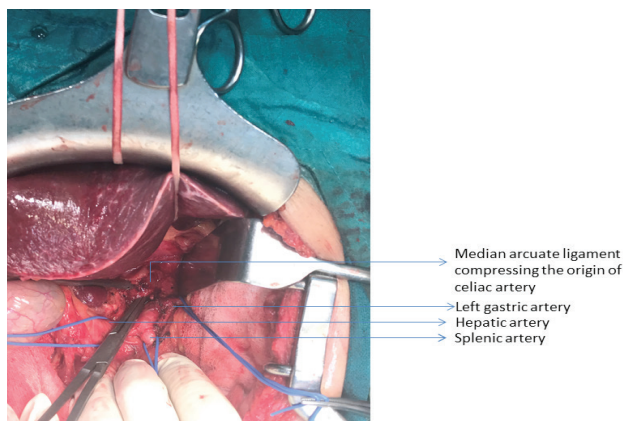


Figure 2: Intra-operative picture showing celiac artery with its branches and MAL

Post operative period was uneventful, her symptoms resolved following the surgery and was discharged on 5th Post operative day. On her follow up in 1 month, she is doing fine without any complaints of pain.

Discussion

MAL syndrome was first described anatomically by Lipshutz in 1917 in cadaveric dissections where celiac artery was sometimes overlapped by the diaphragmatic crura(2). In 1963, Harjola published reports on the clinical resolution of postprandial epigastric pain and epigastric bruit following operative decompression of the celiac artery from a fibrosed celiac ganglion(3). In 1965, Dunbar et al reported a case series involving surgical treatment of MAL syndrome(4).

Compressive symptoms of MAL syndrome arise from close relation of the celiac axis to MAL and diaphragmatic crura. The High origin of the celiac artery or lower insertion of the diaphragm predispose to compression of the celiac artery. It is proposed that in 10% to 24% of general population the MAL crosses the aorta at a lower level and subsequently compresses the celiac artery(5). However, it is clinically significant in only a small subset of patients, contributing to the controversy surrounding MAL syndrome as a pathologic entity.

The most difficult part in the management of MAL syndrome may not be the surgery but rather a proper patient selection

as numerous papers report celiac artery compression may be a normal variant in up to 24 % of general population(5).

The traditional approach to treatment is open decompression via upper midline laparotomy and incising the diaphragmatic fibers 3-5 cm cephalad exposing up to 4cm of aorta. Options for open decompression of the MAL include laparotomy with decompression alone, decompression with celiac dilatation or decompression with reconstruction.

A case series involving 51 patients was done by Reilly et al comparing late outcomes in patients who underwent open decompression alone, decompression with dilatation, or decompression with reconstruction. Regarding patient-reported symptom relief, MAL decompression alone was done in 16 patients, with symptom relief occurring in 9 (56%), and decompression and reconstruction or dilatation was performed in 35 patients, with symptom relief achieved in 27 (77%) with no statistical difference between two groups. Twenty-eight postoperative arteriograms were performed in 25 patients: 10 patients (40%) were symptomatic and 7 (70%) of those showed persistent celiac stenosis(6).

Laparoscopic decompression of celiac artery is being increasingly accepted as standard surgical option due to smaller incision, shorter recovery time and less post-operative pain. But it has its drawbacks due to difficulty in controlling potential hemorrhage, increased risk of injury to abdominal aorta and incomplete release of the MAL.

In our case, the patient had persistent pain not amenable to medical management. We did not have any past experience on open approach, so laparoscopy was not attempted to avoid injury to the major vessels during dissection.

1. Trinidad-Hernandez M KP, Habib I, White JV. Reversible gastroparesis: functional documentation of celiac axis compression syndrome and postoperative improvement. *Am Surg.* 2006;72(4):339-44.
2. Lipshutz B. A composite study of the coeliac axis artery. *Ann Surg.* 1917;65(2):159-69.
3. Harjola P. A rare obstruction of the celiac artery. *Ann Chir Gynaecol Fenn.* 1963;52:547-50.
4. Dunbar JD M, Beman FF, Marable SA. Compression of the celiac trunk and abdominal angina. *Am J Roentgenol Radium Ther Nucl Med.* 1965;95(3):731-44.
5. Horton KM TM, Fishman EK. Median arcuate ligament syndrome: evaluation with CT angiography. *Radiographics.* 2005;25(5):1177-82.
6. Reilly LM AA, Stoney RJ, Ehrenfeld WK. Late results following operative repair for celiac artery compression syndrome. *J Vasc Surg.* 1985; 2(1):79-91.