

Case Report

Annular pancreas presenting as gastric outlet obstruction in an adult: a case report

K.C R, Ghimire B, Singh YP

Institute of Medicine, Tribhuvan University Teaching hospital

Kathmandu, Nepal

Correspondence: Rabindra K C,

Email: rabindraKC01@hotmail.com

Abstract

Annular pancreas is a rare congenital abnormality which arises in the embryo by persistence of pancreatic tissue in the track which the ventral pancreatic bud follows in its rotation round the duodenum. A 21 years old male was admitted because of non bilious vomiting and epigastric fullness after intake of food. Diagnosis was confirmed with contrast enhanced CT scan of the abdomen. He successfully underwent laparoscopic gastrojejunostomy with uneventful postoperative recovery. Though rare, annular pancreas should be considered as differential diagnosis in patient presenting as gastric outlet obstruction after excluding common causes.

Key words: Annular pancreas; Gastrojejunostomy; Gastric outlet obstruction.

Introduction

Annular pancreas (AP) is an uncommon congenital abnormality. It consists of a flat band of pancreatic tissue encircling second portion of the duodenum or the extra hepatic bile duct.¹ It may manifest clinically in the neonate (52%) or remain asymptomatic until adulthood (48%).¹ In adults, symptoms of annular pancreas usually present at the age of 20-50 years as a duodenal obstruction.

Case report

A 21 year old male patient presented with vague upper abdominal discomfort for few months followed by burning retrosternal pain and multiple episodes of non-bilious vomiting for 10 days. The vomitus contained food particles that were taken few minutes back. He also complained of epigastric fullness after intake of food which was relieved after vomiting. He had lost 5 kg weight in last 15 days without loss of appetite. On examination, he was thin built with BMI of 17.61 kg/m². He was neither pale nor icteric. There was no axillary and supraclavicular lymphadenopathy. His abdomen was soft and no masses were present. His upper gastrointestinal endoscopy revealed reflux esophagitis with

gastroduodenitis with deformed pylorus. The food particles ingested were present and it was difficult to negotiate endoscope beyond pylorus. Ultrasonogram of abdomen was normal. Contrast enhanced CT scan of abdomen revealed abnormal pancreatic projections abutting anteromedial and posterior aspect of 2nd part of duodenum with duodenal luminal collapse. (Figure 1) These findings were highly suspicious of incomplete annular pancreases.

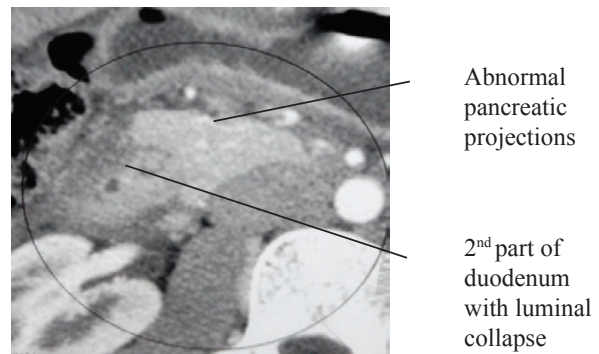


Figure 1: CECT of abdomen revealing incomplete annular pancreas

The patient underwent laparoscopic retrocolic gastrojejunostomy and was discharged uneventfully on 3rd post-operative day. The patient has gained weight and is doing well after a year follow up.

Discussion

AP is rare congenital abnormality. There are three theories concerning the formation of the annular pancreas: a) hypertrophy of both, the ventral and the dorsal pancreatic buds, resulting in a complete ring; b) adherence of the ventral duct to the duodenum before rotation (Lecco's theory) and c) hypertrophy or adherence of the left bud of a paired ventral primordium (Baldwin's theory).¹ Symptoms from AP can occur at any age. The age of onset depends on severity of duodenal constriction. Two third of children present during neonatal period with features of gastric outlet obstruction. Adults present with abdominal pain, epigastric fullness, vomiting, upper GI bleed (from peptic ulceration), acute or chronic pancreatitis and rarely jaundice.³⁻⁴ In a review of 17 years, there were seven adults diagnosed with annular pancreas and five of them required surgery.³

Although surgery is considered diagnostic gold standard, diagnosis is suggested by upper GI series, abdominal CT scan, ERCP, MRCP, endoscopic ultrasound. Symptomatic AP is treated with bypass surgery of annulus which can be achieved via duodenoduonostomy, gastrojejunostomy or duodenojejunostomy.

Conclusion

The prevalence of annular pancreas in Nepal is not known. In spite of such congenital anomaly being rare we should keep it in mind as a cause of gastric outlet obstruction after excluding other common causes.

References

1. Shirkhoda A. Anomalies and anatomic variants of pancreas. In Gore RM, Levine MS, editors. Textbook of gastrointestinal radiology. Philadelphia: WB Saunders; 2000. p. 1754-66.
2. Cunha J E M, Lima MS, Jukemura J, Penteadó S, Jureidini R, Patzina R A; Unusual presentation of annular pancreas in the adult. *Pancreatology* 2005;5:81-85
3. Urayama S, Kozarek R, Ball T, Brandabur J, Traverso L, Ryan J, Wechter D. Presentation and treatment of annular pancreas in adults; *American journal of gastroenterology* 1995 Jun;90(6):995-9.
4. Chen YC, Yeh CN, Tseng JH. Symptomatic adult annular pancreas. *J Clin Gastroenterol* 2003; 36:446-45