Available online at www.jsan.org.np

Journal of Society of Anesthesiologists of Nepal



Original Article

Comparison of ultrasound-guided abdominal nerve blocks and subarachnoid block as an anaesthetic technique for appendectomy: A retrospective study

Prajjwal Raj Bhattarai, Anuj Jung Rayamajhi, Rupesh Kumar Yadav, Subash Chandra Paudel, Anang Pangeni, Bikram Byanjankar, Rabin Pandit

Civil Service Hospital, Min Bhawan, Kathmandu 44600, Nepal

ARTICLE INFO

Article History

Received 26th December 2016

Accepted 4th March 2017

Published 28th June 2017

© Authors retain copyright and grant the journal right of first publication with the work simultaneously licensed under Creative Commons Attribution License CC - BY 4.0 that allows others to share the work with an acknowledgement of the work's authorship and initial publication in this journal.



Abstract

Background: Ultrasound guided abdominal nerve blocks are increasingly being used for anaesthesia and analgesia for surgeries like appendectomy, hernia repair in our centre. The aim of the study was to compare abdominal nerve blocks and subarachnoid block for appendectomy.

Method: Retrospective data of patients that underwent appendectomy either under subarachnoid block (Group-S) or abdominal nerve blocks (Group-A) for three months were collected from hospital records. The groups were compared for conversion to general anaesthesia as a primary end point of study and also for the time taken for the procedure, the first requirement of opioids, total opioid consumption and length of hospital stay.

Result: Out of 116 patients studied, 75 surgeries were performed under subarachnoid block and 41 under abdominal plane blocks. Two patients in Group-S and 1 patient in Group-A were converted to general anaesthesia due to inadequate blockade. The time taken to perform the block was around four minutes in Group-S and 12 minutes in Group-A. The mean pethidine consumption in 24 hours was 62.33±16.63 mg and 23.17±15.19 mg in Group-S and Group-A respectively. The time to the first dose of pethidine in Group-S groups was 224.66±43.56 minutes and 813.17±361.80 minutes in Group-A. The mean duration of hospital stay in Group-S was 5.14±0.72 days and Group-A was 2.24±0.58 days.

Conclusion: Appendectomy can be safely performed under subarachnoid block as well as the abdominal nerve blocks. The abdominal nerve block technique is found to be advantageous in terms of better postoperative analgesia, less opioid consumption and early hospital discharge.

Keywords: appendectomy; coeliac plexus block; rectus sheath block; spinal anaesthesia; transverses abdominis plane block; ultrasound.

How to cite this article: Bhattarai PR, Rayamajhi AJ, Yadav RK, Paudel SC, Pangeni A, Byanjankar B, Pandit R. Comparison of ultrasound-guided abdominal nerve blocks and subarachnoid block as an anaesthetic technique for appendectomy: a retrospective study. *Journal of Society of Anesthesiologists of Nepal (JSAN) 2017;4(1):16-22.* <https://doi.org/10.3126/jsan.v4i1.17384>

Corresponding Author:

Dr Prajjwal Raj Bhattarai, MD

Registrar Anaesthesiology, Department of Anaesthesia and Critical Care, Civil Service Hospital,

Min Bhawan, Kathmandu 44600, Nepal

Email: prajjwal.bhattarai@gmail.com

Orcid ID: <http://orcid.org/0000-0001-6895-6920>

Introduction

Appendectomy is one of the common surgeries performed worldwide.¹ Appendectomy is performed mostly under subarachnoid block (SAB) in our settings. Ultrasound guided Abdominal nerve block (ANB) with intravenous sedation has been adopted to perform appendectomy in our institute for last few years. Abdominal nerve block (ANB) comprises of TANB (Trans-Abdominal Nerve Block) and coeliac plexus block (CPB). Trans-abdominal nerve block has been grouped together for the ease of the study and comprises of Transversus abdominis plane (TAP) block in various levels to block individual nerve (T9-T12 level), rectus sheath block (RSB), ilioinguinal-iliohypogastric nerve block (ILIHNB), and Quadratus lumborum (QLB) block. Fentanyl, propofol and dexmedetomidine are used as a sedative adjunct to ANB and SAB during the anaesthetic and surgical procedures. We hypothesised that appendectomy can be performed successfully under the subarachnoid block and abdominal nerve blocks.

Methods

The research methodology was developed and approval from institutional review board was taken for this retrospective study. The data from chart review of patients admitted for an emergency appendectomy in Civil Service Hospital was collected since April to September 2016. Consecutive patients that underwent appendectomy under ANB (Group A) or SAB (Group S) were studied. American Society of Anesthesiologist physical status more than II, appendicular perforation, ultrasound finding of subhepatic and retrocecal appendix, age less than fifteen and more than seventy, weight less than forty and more than eighty, patient with inadequate nil per oral status, pregnant patient, patient with psychiatric illness or having history of allergic/hypersensitivity to local anesthetics were excluded from study. Patients, who did not undergo appendectomy under standard anaesthesia protocol (includes subarachnoid block and abdominal nerve blocks with sedation) of the hospital were also excluded from the study.

The two groups were compared for conversion to general anaesthesia and considered as the primary endpoint. Conversion to general anaesthesia was taken as block failure. The secondary endpoints included were intraoperative vitals, use of vasopressor, perioperative complications, and procedural duration, postoperative pain, opioids consumption and length of hospital stay.

In Group S, an intravenous line was secured and on arrival at operative room routine monitoring of heart rate, non-invasive blood pressure and pulse oximeter were attached and spinal anaesthesia was administered using 3-3.4ml of 0.5% hyperbaric bupivacaine. The modified Bromage scale was used for evaluating motor block level. (0 = no paralysis; 1 = unable to raise extended leg; 2 = unable to flex knee; 3 = unable to flex ankle). Painting and draping were allowed at Bromage scale 2. The target sensory level

was T4 and temperature sensation using spirit swab was used to check the adequacy of surgical anaesthesia. One to two mg of midazolam and fifty to hundred micrograms of fentanyl were used as intraoperative sedation.

In Group A, during pre-anaesthetic check-ups, proper procedural counselling for ultrasound guided nerve block was done. An intravenous line was secured and on arrival at operative room routine monitoring of heart rate, non-invasive blood pressure and pulse oximeter were attached. One to two-milligram midazolam and fifty to hundred micrograms of fentanyl were injected prior to performing ANB. Aseptic precaution was maintained and out of plane technique using 2–5 MHz frequency convex probe {Medison, My Sono 6} was used for coeliac plexus block.

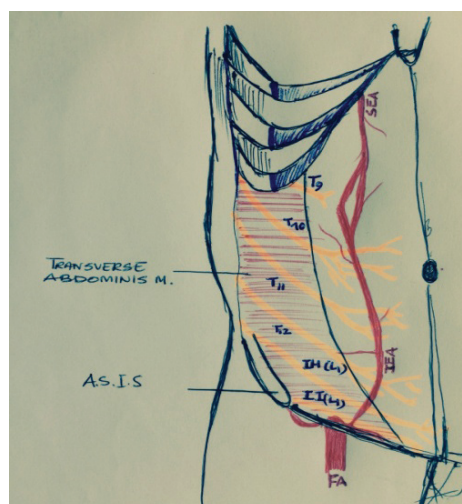


Figure 1: Schematic diagram showing abdominal nerves

ASIS: anterior superior iliac spine; SE.A: Superior epigastric artery; IE.A: Inferior epigastric artery

Coeliac plexus block was performed at T12 or L1 vertebral level as posterior approach patient in lateral decubitus position. Ten ml of 1% of lidocaine with adrenaline was injected via 26-gauge Quincke spinal needle. Likewise, 5-12 MHz frequency linear probe {Medison, My Sono 6} was used for discrete TAP block at various levels as shown in figure 1. {Figure 1: Schematic diagram showing abdominal nerves.}. Five ml mixtures of 1% lidocaine and adrenaline and 0.25% of ropivacaine was administered just below costal margins on visualisation of the nerve or the plane between internal oblique muscle and Transversus abdominis muscle as the first injection blocking T-9 nerve. Similarly, same volume and concentration of local anaesthetic were administered two cm behind and below the first injection to block T10 nerve. T-11 was also blocked at similar fashion. A 26-gauge Quincke spinal needle was utilised for both injection and normal saline was applied for hydro dissection during confirmation of the plane.

After the blocks in both group A and S, dexmedetomidine was started for sedation in all the patients at the rate of 0.5mcg/kg/min and titrated accordingly to maintain

Ramsay sedation Score 2, not exceeding 0.7mcg/kg/min throughout the procedure. A nasopharyngeal airway was inserted if signs of airway obstruction occurred and Oxygen at the rate of 5-6 litres/min was delivered via facemask after initiation of sedation. Assessing temperature sensation using spirit swab is used to check the adequacy of surgical anaesthesia. As adequate analgesia was confirmed; and surgery was allowed injecting 0.5mg/kg propofol one minute prior to surgical incision.

Ephedrine (5 mg) and atropine (0.3 mg) were used for intraoperative hypotension and bradycardia. Preparedness of general anaesthesia was kept ready. Injection paracetamol one gram and injection ketorolac 30 mg was given for all patients twice daily in the postoperative period till hospital discharge. Injection pethidine 25 mg was used intramuscularly as rescue analgesia if visual analogue scale (VAS) assessed by the ward nurse was more than four. Granisetron one mg given for intraoperative or postoperative nausea vomiting was noted. The rate of conversion to general anaesthesia, intraoperative vitals, the dose of vasopressors used, perioperative

complications, time taken for the procedure, postoperative pain, opioids and length of hospital stay were recorded as per institutional protocol.

The data were entered in Microsoft excel 2011 and analysed using SPSS software package version 23. The multiple imputation techniques were used to recover missing data. Independent T-test, Mann-Whitney U test and Chi-square test were used for analysis of parametric, nonparametric and categorical data respectively.

Results

Out of two thousand and two surgeries performed from April to September 2017, three hundred twenty-one cases were carried out on an emergency basis. Among these, one hundred thirty-two cases were posted for an appendectomy. In addition to nine patients who underwent surgery under general anaesthesia, other seven patients were excluded from the study for having one or more exclusion criteria. Of those 116 patients, who met inclusion criteria, 75 patients were undergone surgery under SAB and 41 patients under ANB (Figure 2 Flowchart).

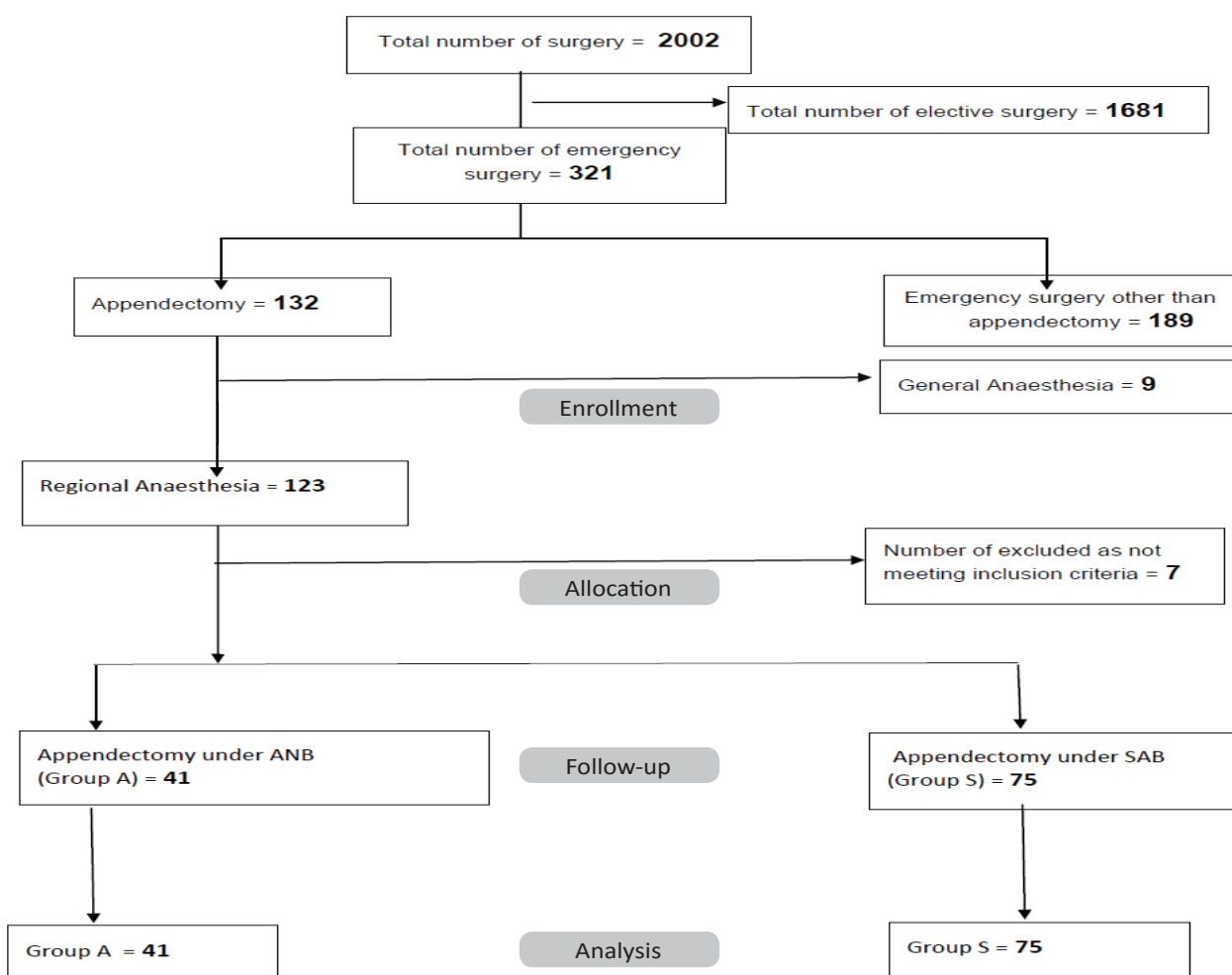


Figure 2: Flowchart of patients that underwent surgeries in the six-month study period

The demographic data are shown in Table 1.

Table 1: Comparison of Demographic data

Variables	Group S {n=75}	Group A {n=41}	P value
Age*	30.14 {13.63}	34.00 {14.28}	0.154
Weight*	63.58 {11.48}	66.87 {9.88}	0.124
Sex {M/F}#	38/37	21/20	0.955
ASA PS {I/II}#	65/10	34/7	0.825

*Data are expressed in Mean {SD}

#Data expressed in absolute numbers

ASA PS- American Society of Anesthesiologists physical status

Comparison of intraoperative mean heart rate (HR), mean arterial pressure (MAP) and postoperative visual analogue score (VAS) of 24 hours are illustrated in figure 3, figure 4 and figure 5 respectively.

Comparison of mean HR

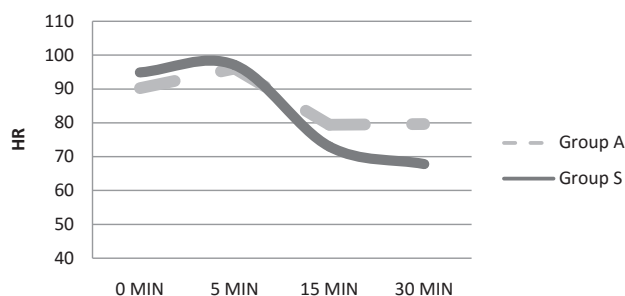


Figure 3: Comparison of mean heart rate

Heart rate in Group S vs. Group P respectively at 0, 5, 15 and 30 minutes: 94.88+16.82 vs 90.26+14.0 (p-value 0.171), 97.05+19.14 vs 96.00+14.43 (p-value 0.004), 72.96+14.28 vs 79.48+11.57 (p-value 0.010) and 67.77+11.81 vs 79.63+12.60 (p-value 0.646)

Comparison of mean MAP

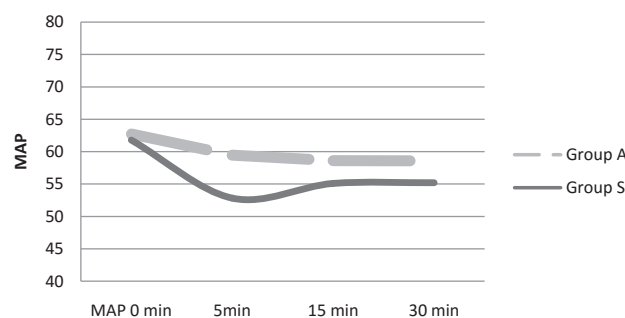


Figure 4: Comparison of mean of MAP

* mean+SD MAP in Group S vs. Group P at 0, 5, 15 and 30 minutes 61.69+14.18 vs. 62.71+10.29 (p-value 0.008), 52.82+13.88 vs. 59.47+10.37 (p-value 0.022), and 55.08+11.21 vs. 58.61+10.12. 0.379) and 55.19+11.39 vs. 58.75+10.63 (p-value 0.589)

Comparison of VAS

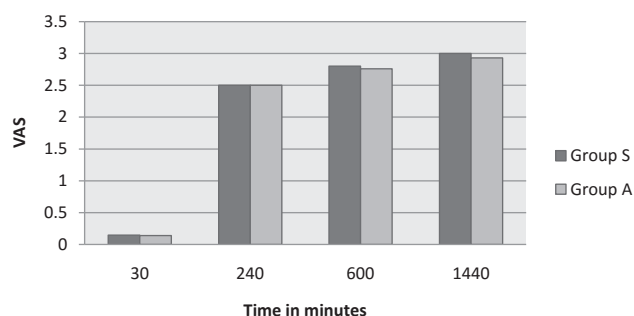


Figure 5: Comparison of VAS scores at different time intervals

mean + SD VAS in Group S vs. Group A at 30, 240, 600 and 1440 minutes 0.20+0.40 vs. 0.04+0. 21) (p-value<0.001), 2.68+1.56 vs. 2.17+0.86 (p-value<0.001), 2.56+1.23 vs. 3.24+1.11 (p-value 0.329) and 3.16+1.34 vs. 2.70+1.14 (p-value 0.139)

Among all, 77.46% of patients {55 out of 71} in SAB required intraoperative vasopressor whereas none of the patients in ANB groups required vasopressor. (P=0.001). Table 2 summarises mean time taken for performing the block, the onset of anaesthesia and duration of surgery.

Table 2: Time taken for performing block, onset of anesthesia and duration of surgery

Variables	Group S {n=75}	Group A {n=41}	P value
Time taken for performing block in minutes	289.47 {66.22}	881.95 {251.34}	0.001
Onset of anesthesia in seconds*	573.60 {59.92}**	779.26 {224.11}**	0.001
Duration of surgery* in minutes	21.14 {8.43}**	20.56 {6.51}**	0.703

Data are expressed in Mean {SD}

**Time period expressed in minutes

#Time period expressed in seconds

Twenty-four hours opioids consumption and time to first requirements of opioids are described in Table 3.

Table 3: Pethidine consumption in 24 hours and time to the first requirement of opioids

Variables	Group S	Group A	P value
Pethidine consumption* in mg in the first 24 hours	62.33 {16.63}	23.17 {15.19}	0.001
Time to the first requirement of opioids in minutes*	224.66 {43.56}	813.17 {361.80}	0.001

*Data are expressed in Mean {SD}

Intraoperative and postoperative complication Mean days of discharge are tabulated as follow. (Table 4)

Table 4: Frequency of conversion to general anaesthesia, Days to hospital discharge and complication

		Group S (n=75)	Group A (n=41)	p-value
Conversion to general anaesthesia		1 (1.33%)	2 (4.87%)	0.250
Duration of Hospital stay in days *		5.14±0.72	2.24±0.58	<0.001
Complications	Intra-operative			
	Hypotension	22 (29.33%)	2 (4.87%)	<0.001
	Bradycardia	2 (2.66%)	0	0.096
	Postoperative			
	Urinary retention	17 (22.66%)	1 (2.43%)	<0.001
	PONV	5 (6.66%)	3 (7.31%)	0.163

*Data are expressed in Mean {SD}; PONV- postoperative nausea vomiting

Discussion

Abdominal nerve block {ANB} is term developed for ease of this study and is not used previously elsewhere. Similarly, terms like ANB, TANB, and CPB were used to avoid imprecision in terminology. Abdominal Nerve Block {ANB} comprises trans-abdominal nerve block {TANB} and coeliac plexus block {CPB}. TANB incorporates TAP block, rectus sheath block (RSB), ilioinguinal-iliohypogastric {ILIH} nerve block or quadratus lumborum {Q-L} blocks. (Figure 6)

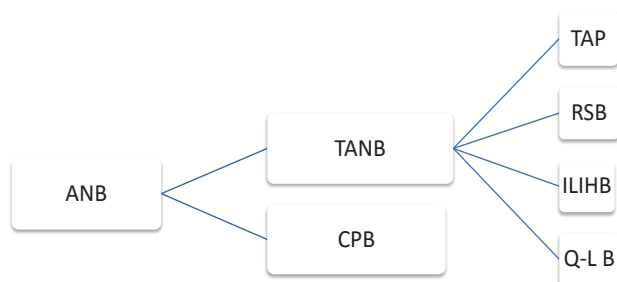


Figure 6: Proposed classification of abdominal nerve block for study purpose

ANB-Abdominal nerve block; TANB-Transabdominal nerve block; CPB-coeliac plexus block; TAP- Transversus Abdominis plane; RSB- Rectus sheath block; ILIH- Ilioinguinal iliohypogastric block; Q-L- Quadratus Lumborum block

Various abdominal planes blocks including ultrasound assisted coeliac plexus block is being practised in our hospital for last few years. Cases, performed under a similar pattern of anaesthesia for abdominal onco-surgeries, have been reported.² The possibility of safely performing appendectomy under abdominal nerve blocks was the primary concern of this study. Two patients from the ANB group had to be converted to general anaesthesia due to inadequate block and was comparable with SAB. There might be various reasons for the block failure. Proper patient counselling is essential to perform peripheral nerve block successfully.¹² During emergency

appendectomy chances of inadequate counselling prevail particularly in the resource-limited setting where the need for rapid turnover is high. Lack of sedation for apprehensive patients or inappropriate drug deposition could be the other causes. In contrary, in those cases where surgery was performed successfully under ANB have better results in terms of postoperative analgesia, less opioid consumption, decreased chances of complication and early discharge. However, the present study could not compare the role of sedation during ANB.

TAP block can be adeptly achieved in various approaches like subcostal lateral or posterior approach to facilitate lower abdominal surgery in combination with other abdominal plane blocks.³ During TAP block, the nerve can be identified at discrete level (e.g. T9-T11) and can be blocked using low volume {3-5ml} of local anaesthetics at each level (figure 7) as performed in this study. As TAP block alone is not sufficient to relieve visceral pain, celiac plexus block (CPB) was used.⁴

CPB is a type of sympathetic block, used to abate visceral pain that originates from intra-abdominal organs derived from embryonic midgut including ascending colon and proximal part of the transverse colon. In 1914 Kappis first used a percutaneous technique for CPB that can even be used for surgery.⁵ CPB is difficult to perform because of anatomical variations. Hence fluoroscopy, CT, EUS (end-sonographically) or USG guidance is essential for proper demonstration of coeliac plexus and appropriate deposition of local anaesthetics.⁶ These may be the reasons for CPB not being popular among anaesthesiologists as sole technique for surgical anaesthesia. Currently, the technique is mainly limited to palliative analgesic care for abdominal cancer pain and chronic pancreatitis.⁷

Numerous approaches like posterior {retro-crural}, anterior, trans-aortic, trans-crural and trans-intervertebral have been described for CPB.⁵ Role of ultrasound for CPB has been studied, though not well recognised. Matamala

et al used ultrasound for needle insertion in nine patients during CPB via an anterior approach.⁸ The ultrasound guided posterior approach was chosen because anatomy was more familiar to us as ultrasound guided truncal blocks like lumbar plexus block, quadratus lumborum block, paravertebral etc. are routinely practised in our settings. The anterior approach is assumed to be associated with fewer complications and more comfortable to patient.¹⁴ Arrangement of computed tomography (CT), commonly used for the CPB, is easier in this approach. However, we did not use CT scan for CPB. In present study posterior approach was selected and CPB was performed in lateral decubitus position. Ultrasound guided block can be performed in this position with judicious use of sedation. Moreover, complications can be decreased with appropriate technique and is not solely dependent on selection of either approach.¹¹

In the present study, one patient complained of urinary retention that may be attributed due to unopposed parasympathetic action. Use of pethidine can be the reason for PONV in four of the patients. We did not note any other major complications. Rather, time taken for performing ANB was significantly higher, showing ultrasound-guided blocks required a new set of skill. In addition to these skills, good hand-eye co-ordination has to be acquired for efficient blocks.⁹ The learning curve might be steep. Nevertheless, these skills are easy to learn, safe to perform with relatively fewer complications if user-friendly and reliable ultrasound machine is used with appropriate technique.¹⁰ Proper imaging of nerve, following needle tip during injection of local anaesthetic, close to the nerves avoiding damage of vital structures are the key success for efficient nerve block.¹¹

Likewise, the onset of ANB was delayed than SAB. Although the difference in the onset is statistically significant, the difference i.e. three to four minutes is clinically acceptable for the surgeries like the appendectomy. However, proper pre-procedural counselling and establishing separate block room in operation theatre, will not delay routine work on the day of surgery. Brook BS has shown pre-operative counselling, attending PAC clinics, patient education, and informed consent for regional anaesthesia reduced operative downstream delay.¹²

Twenty-four-hour opioids consumption is evocatively low in patients who received ANB. The mean dose of opioids used over 24 hours in Group A was almost one-third that of group S. This shows a prolonged postoperative analgesic effect of ANB. The interpretation of VAS between two groups should be done with caution from this retrospective study. Since the interval of observational points for VAS was fixed, as per hospital protocol i.e. thirty minutes, four hours, ten hours and twenty-four hours whereas opioids received in between the observation points would have affected the result in VAS. This may be the cause of inconsistency shown in comparison VAS scores.

Similarly mean duration for the first time to opioids i.e. thirteen and half hours showed the duration of analgesia of ANB, which is significantly longer than that of SAB. The prolonged analgesia leading to less consumption of opioids will attribute to reduce detrimental effects like respiratory depression, PONV, pruritus, prolonged hospital stay etc.¹³

Furthermore, in Group A, the frequency of intraoperative hypotension and thus uses of vasopressor and postoperative urinary retention are found to be less. An exaggerated physiological response like hypotension, bradycardia due to sympathetic block during CPB is less profound than during subarachnoid block. Likewise, as there will not motor blockade in ANB, in contrary to SAB, early ambulation is possible contributing to decreased days of hospital stay in ANB groups. {ANB Vs. SAB 2.24 vs. 5.14 days}

Small sample size and retrospective chart review are the primary limitations of the present study. Observation points were fixed, the monitoring intervals were long and the rescue analgesics were used as per institutional protocol. The future prospective study should address these issues and possibly use patient-controlled analgesia for better pain comparison, patient satisfaction and cost estimation.

In conclusion, present study demonstrated appendectomy can be performed under abdominal nerve blocks and the conversion rate to general anaesthesia is comparable to subarachnoid block. Appendectomy under ultrasound guided abdominal nerve block is advantageous in terms of better postoperative analgesia, less opioid consumption, decreased hospital stay and lessened perioperative complications. Thus the technique can be developed as an alternative anaesthetic tool. However, the procedural time for is longer and the onset of anaesthesia is delayed than the subarachnoid block.

Conflict of interests: The authors have filled the ICMJE conflict of interest form and declare no competing interests.

Acknowledgements: None

Sources of Funding: The study was supported by the Civil Service Hospital, Kathmandu Nepal.

Orcid IDs:

Prajwal Raj Bhattarai <http://orcid.org/0000-0001-6895-6920>

Anuj Jung Rayamajhi <http://orcid.org/0000-0002-0138-6502>

Rupesh Kumar Yadav <http://orcid.org/0000-0002-0607-6677>

Subash Chandra Paudel <http://orcid.org/0000-0001-9829-1843>

Anang Pangeni <http://orcid.org/0000-0002-1748-6479>

Bikram Byanjankar <http://orcid.org/0000-0003-0847-7586>

Rabin Pandit <http://orcid.org/0000-0001-5272-2089>

References

1. Antonio B, Carla DS, Francesco F, Angelo B, Marco V, Luigi P. Laparoscopic versus open appendectomy: a retrospective cohort study assessing outcomes and cost-effectiveness. *World J Emerg Surg* 2016;11(1):44. <https://doi.org/10.1186/s13017-016-0102-5> [PMid:27582784] [PMCID:PMC5006397]
2. Rayamajhi AJ, Bhattarai PR, Yadav RK, Paudel SC, Pandit R, Shakya VC. Ultrasound guided abdominal plane blocks as anaesthetic technique for laparotomy in cancer patients: a case series. *Journal of Society of Anesthesiologists of Nepal (JSAN)* 2016;3(2):90-2. <https://doi.org/10.3126/jsan.v3i2.15625>
3. Morimoto Y. Transversus abdominis plane block: a review of the technique and its efficacy. *Anaesth Pain & Intensive Care* 2015;19(3):357-360.
4. Yarwood J, Berrill A. Nerve blocks of the anterior abdominal wall. *Continuing Education in Anaesthesia, Critical Care & Pain* 2010;10(6):182-6. <https://doi.org/10.1093/bjaceaccp/mkq035>
5. Jain P, Dutta A, Sood J. Coeliac plexus blockade and neurolysis: an overview. *Indian J Anaesth* 2006;50(3):169-177.
6. Matamala AM, Vidal FJ, Sanchez AL, Bach LD. Percutaneous anterior approach to the coeliac plexus using ultrasound. *Br J Anaesth* 1989;62:637-40. <https://doi.org/10.1093/bja/62.6.637>
7. Carroll I. Celiac plexus block for visceral pain. *Curr Pain Headache Rep* 2006;10(1):20-5. <https://doi.org/10.1007/s11916-006-0005-3> [PMid:16499826]
8. Matamala AM, Lopez FV, Martinez LI. The percutaneous anterior approach to the celiac plexus using CT guidance. *Pain* 1988;34(3):285-8. [https://doi.org/10.1016/0304-3959\(88\)90124-8](https://doi.org/10.1016/0304-3959(88)90124-8)
9. Kim SC, Hauser S, Staniek A, Weber S. Learning curve of medical students in ultrasound-guided simulated nerve block. *J Anesth* 2014;28(1):76-80. <https://doi.org/10.1007/s00540-013-1680-y> [PMid:23893012]
10. Marhofer P, Harrop-Griffiths W, Kettner SC, Kirchmair L. Fifteen years of ultrasound guidance in regional anaesthesia. *Br J Anaesth* 2010;104:538-46. <https://doi.org/10.1093/bja/aeq069> [PMid:20364022]
11. Pablo EH, Diogo BC, Getúlio RO. Ultrasound guided nerve block. *Rev Bras Anesthesiol* 2007;57(1):106-23.
12. Brooks BS, Barman J, Ponce BA, Sides A, Vetter TR. An electronic surgical order, undertaking patient education, and obtaining informed consent for regional analgesia before the day of surgery reduce block-related delays. *Local Reg Anesth* 2016;9:59-64. <https://doi.org/10.2147/LRA.S115432> [PMid:27785096] [PMCID:PMC5063487]
13. Laura TP, Richard T, Kathleen F, Erin T, Wing C, Myoung K, Joseph C, Marc R, Eugene V. Pharmacotherapy Relationship Between Potential Opioid-Related Adverse Effects and Hospital Length of Stay in Patients Receiving Opioids After Orthopedic Surgery. *British journal of clinical pharmacology* 2012;32(6):502-514.
14. Ashley MN, Charles ER. Percutaneous Neurolytic Celiac Plexus Block. *Semin Intervent Radiol* 2013;30(3):318-21. <https://doi.org/10.1055/s-0033-1353485> [PMid:24436554] [PMCID:PMC3773031]