



Case Report

# Filariasis presenting as an upper arm swelling – an unusual presentation

Adhikari Purbesh<sup>1</sup>, Upadhyaya Paricha<sup>1</sup>, Dhakal Sushil<sup>1</sup>, Dahal Mona<sup>1</sup>,  
Bhattarai Soorya<sup>1</sup>

<sup>1</sup>Department of Pathology, B.P.Koirala Institute of Health Sciences, Dharan, Nepal.

## Keywords:

Filariasis;  
Microfilaria;  
Subcutaneous;  
Swelling;

## ABSTRACT

Filariasis is a chronic disabling parasitic disease causing a major public health problem in tropical areas of Southeast Asia. It is endemic in India, China, Nepal, Indonesia, parts of Asia and Africa. In Southeast Asia it is caused mainly by *W. bancrofti* and *Brugia* species. Microfilaria is known to be present in cytology smears prepared from swelling at various sites and also in different body fluids. However, upper arm swelling as a clinical presentation of filariasis is a very rare event. If cytology smears are screened with high index of suspicion in this group of otherwise asymptomatic patients, early institution of proper treatment can both prevent the complication of the disease as well as break the chain of transmission from healthy carriers.

## Correspondence:

Dr. Purbesh Adhikari, MBBS, MD

Senior Resident, Department of Pathology, BPKIHS

Email: [purbesh.adhikari@bпкиhs.edu](mailto:purbesh.adhikari@bпкиhs.edu)

Orcid ID: 0000-0001-6278-7855



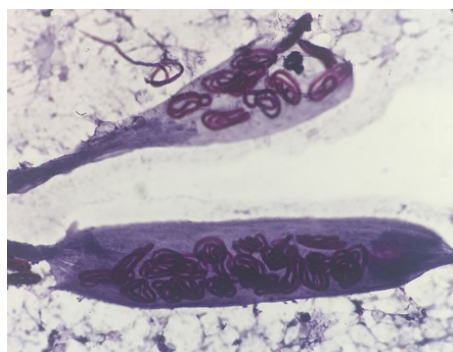
Received : December 14<sup>th</sup> 2017 ; Accepted : January 17<sup>th</sup> 2018; Published : March 30<sup>th</sup> 2018

**Citation:** Adhikari P, Upadhyaya P, Dhakal S, Dahal M, Bhattarai S. Filariasis presenting as an upper arm swelling – an unusual presentation. J Pathol Nep 2018;8:1317-9. doi: 10.3126/jpn.v8i1.19461

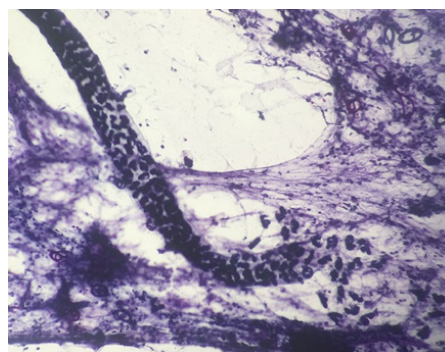
**Copyright:** This is an open-access article distributed under the terms of the Creative Commons Attribution 4.0 International License, which permits unrestricted use, distribution, and reproduction in any medium, provided the original author and source are credited.

## INTRODUCTION

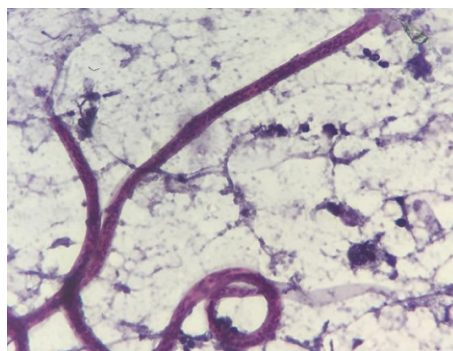
Filariasis is a chronic disabling parasitic disease causing a major public health problem in tropical areas of Southeast Asia. It is endemic in India, China, Nepal, Indonesia, other parts of Asia and Africa.<sup>1,2</sup> In Nepal sixty one districts of the country were mapped as endemic for lymphatic filariasis.<sup>3</sup> It is commonly caused by *Wuchereria bancrofti* and transmitted by mosquito vector, *Culex quinquefasciatus*. *W. bancrofti* causes 90% and *Brugia* species causes 10 % of the total number of infections worldwide.<sup>4</sup> In filariasis, man is the definitive host and mosquito is the intermediate host. Third stage larvae of developing *W. Bancrofti* and *B.malayi* are the infective form, which inoculates through skin during mosquito bites. The deposited larvae puncture or penetrate through the skin and invade to subcutaneous lymphatics to reach areas where they can grow. Species identification is often difficult in the adult worm, but it is possible on the basis



**Figure 1:** Fragment of adult female filarial worm containing numerous coiled microfilaria (Papanicolaou stain, X200).



**Figure 2:** Female adult filarial worm along with discharged numerous coiled form of larvae outside the adult worm (Papanicolaou stain, X100).



**Figure 3:** Photomicrograph showing microfilaria of *Wuchereria bancrofti* with characteristic cytomorphology of sheathed larvae with tail-tip free from nuclei. Mixed inflammatory infiltrate composed of eosinophils and neutrophils is seen in the background (Papanicolaou stain; X1000).

of microfilarial morphology. Main differentiating features include - length (large in *W. bancrofti*), secondary kinking (found in *B. malayi*) versus smooth curves (*W. bancrofti*), tale tip (free of nuclei in *W. bancrofti*, two discrete nuclei in *B. malayi*).<sup>2,5,6</sup>

The common manifestations of filariasis are elephantiasis, chronic lymphedema, epididymitis, funiculitis and lymphadenitis.<sup>7</sup> Filariasis in the form of subcutaneous swelling is a relatively uncommon event.<sup>2</sup> We report a case of subcutaneous upper extremity swelling caused by *W. bancrofti* which was diagnosed by demonstration of microfilaria in cytological smears.<sup>2</sup>

## CASE REPORT

A 29 years female presented to the routine clinical outpatient department of B.P. Koirala Institute of Health Sciences with a history of swelling in the medial aspect of her right upper arm for two weeks. The swelling was of size 2 x 2 cm<sup>2</sup>, soft, non-tender, mobile and the patient had no other complaints. Clinicians suspected it to be a case of lipoma. On Fine needle aspiration cytology (FNAC) from the swelling, pus

like yellowish aspirate was seen. Cytology showed large numbers of sheathed microfilariae of *W. bancrofti* with a clear space of nuclei at its caudal end. (fig.1 to 3) Complete blood count (CBC) and peripheral blood smear findings was found to be normal in the patient.

## DISCUSSION

In the South Asian subcontinent filariasis is mainly caused by two closely related nematode worms, *W. bancrofti* and *Brugia malayi*. Culex mosquito transmits the bancroftian filariasis whereas *Mansonia* species transmits the brugian infections.<sup>1,8</sup> There are two different types of microfilaria found in humans: sheathed and unsheathed. Microfilariae *bancrofti* and Microfilariae *malayi* are sheathed whereas Microfilariae *perstans* and Microfilariae *ozzardi* are unsheathed varieties.<sup>2</sup> Filariasis is commonly diagnosed either by detecting circulating filarial antigen or by demonstration of microfilaria in stained or unstained blood films and it may sometimes also be detected in histopathological sections.<sup>2,9</sup> Fluid cytology or fine needle aspiration is very rarely applied for the detection of filariasis.

Lymphatic blockage and lymphatic obstruction resulting in lymphedema and lymphadenitis are usual mode of presentation of filariasis however extranodal filariasis is rare and has been reported in uncommon sites including skin and soft tissue swelling, breast, thyroid nodule, salivary gland, cervicovaginal smear, ovarian cyst, effusion fluids, urine, bronchial, laryngeal and pharyngeal brushings.<sup>7,10,11</sup>

Extravasation may explain the presence of microfilariae in pericardial fluid, breast cyst fluid and bronchial aspirate. The parasites circulate in lymphatic and vascular compartments but the presence of filarial organism in tissue fluids and exfoliated surface material probably occurs owing to conditions causing lymphovascular obstruction resulting in extravasations of blood and release of microfilariae.<sup>1,12</sup> Rupture of vessels may have led to release of microfilariae into the subcutaneous tissue. Surrounding host tissue reaction probably led to the development of a well-defined

cystic swelling containing multiple microfilariae.<sup>1,2,9</sup>

It can be easy to diagnose a typical case of filariasis with classical clinical features if parasite can be demonstrated in the circulating blood which is usually not the case and unfortunately, in endemic areas, a majority of the affected individuals remain asymptomatic with continued disease transmission and microfilaremia is often absent and transient which further complicates disease detection.<sup>2,13</sup> Microfilaremia is often absent inspite of the high incidence of the parasite in the endemic zone and presence of microfilariae in cytological smears and body fluids is an incidental finding. We have experienced at least one case of filariasis detected in pericardial effusion along with this case, presenting as a subcutaneous swelling which is a very rare presentation.

Another peculiarity was that peripheral blood eosinophil count in our case was normal, and microfilaria was also not detected in blood which is similar to the observations reported in other case reports, in contrary to some other reported cases of filariasis found to be associated with peripheral blood eosinophilia. These observations suggest that there is no consistent relationship between filarial infection and blood eosinophilia which in turn reflects the host response to parasite may differ in filariasis from person to person.<sup>2,5,6</sup>

## CONCLUSION

Our case presented as a soft tissue swelling which was clinically suspected to be a case of lipoma, so this report of filariasis highlights the importance of role of fine needle aspiration cytology in the diagnosis of filariasis in clinically unanticipated scenario as these patients in endemic areas may be asymptomatic except for the presence of swelling with afebrile state in the blood and normal eosinophil counts. It also reminds the tropical pathologist to remain vigilant and maintain a high index of suspicion for filariasis in any soft tissue swelling since filariasis is known to be present in almost every organ of the body and may mimic any soft tissue tumour or malignancy.

## ACKNOWLEDGEMENT

We would like to thank Dr. Sunil Pokharel for providing his inputs in preparing this manuscript.

**Conflict of Interest:** None

## REFERENCES

1. Tandon N, Bansal C, Sharma R, Irfan S. Role of fine needle aspiration cytology in diagnosing filarial arm cysts. *BMJ Case Rep.* 2013;17. bcr2013009677. [Crossref](#)
2. Pandey P, Dixit A, Chandra S, Tanwar A. Cytological diagnosis of bancroftian filariasis presented as a subcutaneous swelling in the cubital fossa: an unusual presentation. *Oxford Med case reports.* 2015;4:251–3. [Crossref](#)
3. Department of Health services D. Annual Report: Department of Health Services 2071/72 (2014/2015). 2015;71:iii,iv. [Crossref](#)
4. Jain S, Sodhani P, Gupta S, Sakhuja P, Kumar N. Cytomorphology of Filariasis Revisited Expansion of the Morphologic Spectrum and Coexistence with Other Lesions. *Acta Cytol.* 2001;45:186–91. [Crossref](#)
5. Jha A, Shrestha R, Aryal G, Pant AD, Adhikari RC, Sayami G. Cytological diagnosis of bancroftian filariasis in lesions clinically anticipated as neoplastic. *Nepal Med Coll J.* 2008;10:108-14. [Crossref](#)
6. Pantola C, Kala S, Agarwal A, Khan L. Microfilaria in cytological smears at rare sites coexisting with unusual pathology: A series of seven cases. *Trop Parasitol.* 2012;2:61–3. [Crossref](#)
7. Sane KC, Bholay SU, Bari VB, Kulkarni MN. Microfilaria coexistent with fibroadenoma – an unusual association. *J Clin Diagnostic Res.* 2015;9:15-6. [Crossref](#)
8. Basu A, Sistla SC, Verma SK, Jagdish S. Lymphadenovariex in the axilla-an unusual presentation of filariasis. *Filaria J.* 2006;5:9. [Crossref](#)
9. Gupta K, Sehgal A, Puri MM, Sidhwa HK. Microfilariae in association with other diseases. A report of six cases. *Acta Cytol.* 2002;46:776–8. [Crossref](#)
10. Kp K, Anjum A, Subbannaiah P, Tm PK. Cytodiagnosis of filariasis from a swelling on upper arm – a rare presentation. *Sch J App Med Sci.* 2013;1:593–4.
11. Pal S, Bose K. Microfilaria in fine needle aspiration cytology of breast lump: An unusual finding. *J Heal Spec.* 2015;3:235. [Crossref](#)
12. Kaur R, Phillip KJ, Masih K, Kapoor R, Johnny C. Filariasis of the Breast Mimicking Inflammatory Carcinoma. *Lab Med.* 2009;40:683–5. [Crossref](#)