



Case Report

Intraosseous lipoma - A rare cause of 'cystic' lesion of calcaneum

Vijayan P¹, Babitha AM¹, Ilias LM¹, Ponniah A¹

¹Department of Pathology, MES Medical College, Perinthalmanna, Kerala, India

Keywords:

Cystic lesion;
Calcaneum;
Intraosseous;
Lipoma

ABSTRACT

Intraosseous lipoma is an uncommon benign bone neoplasm with most of them detected incidentally on multimodality imaging while being evaluated for an unrelated pathology. Long and cancellous bones are commonly involved. This lesion can present a diagnostic challenge to those uninitiated in its appearance because they can be often mistaken for other benign or malignant bone lesions such as enchondroma, fibrous dysplasia, osteoblastoma, bone infarct, bone cyst and chondrosarcoma. Here we report a case of symptomatic calcaneal lipoma in a 50 year old lady who presented with heel pain. Plain X-ray suggested cystic lesion of calcaneum. MRI revealed the presence of intralesional fat and histopathological examination confirmed the diagnosis. We present this report for its rarity and the clinching MRI features of this lesion, the excellent prognosis and near negligible recurrence rates, so that misdiagnosis leading to unnecessary workup, biopsy and treatment may be avoided, especially in asymptomatic patients.

INTRODUCTION

Intraosseous lipomas are considered to be among the rarest primary bone tumors, accounting for <0.1% of the cases. In the past, the relative absence of symptoms and radiographic similarity to a bone cyst has accounted for underdiagnosis of intraosseous lipoma. But with the advent of CT and MRI in the evaluation of bone lesions, an increasing incidence of this lesion has been reported because of their increased sensitivity in detecting intralesional fat as well as dystrophic calcification.¹

Correspondence:

Dr. Poornima Vijayan, MBBS, MD

Assistant Professor,

Department of Pathology, MES Medical College, Perinthalmanna, Kerala, India. Email: poornima_vij@yahoo.co.in

CASE REPORT

A 50 year old female presented with history of intermittent pain over the left heel for 1 year. On examination there was tenderness over the lateral tubercle of calcaneum. Plain radiograph suggested a 2x2 cm well circumscribed opacity below the calcaneum. On MRI, the lesion was described as geographic, rounded, without cortical interruption, with a peripheral rim of high signal intensity on T1 and T2-weighted images. Focal area of calcification was noted. It was reported as suggestive of calcaneal lipoma, Milgram stage II. The lesion was then curetted out and sent for histopathological examination. Histopathology revealed mature adipose tissue surrounding atrophic bone (fig.1). No cellular atypia or mitoses were encountered. Infraction bone (fig.2) and areas of calcification was noted. Marrow

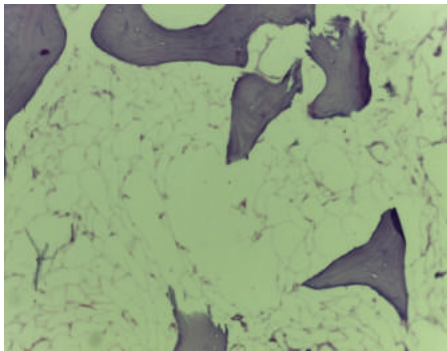


Figure 1: Lobules of mature adipose tissue in between bony trabeculae. Note the absence of normal hematopoietic elements (HE stain, X100).

hematopoietic elements were conspicuous by their absence. Diagnosis of intraosseous lipoma of the calcaneum was made.

DISCUSSION

Long and cancellous bones are the most locations that can be affected. Calcaneum is a typical site of occurrence for these tumors. Other long tubular bones like femur, tibia and fibula are also common sites. In the long bones, intraosseous lipomas are found in the metaphyseal and diaphyseal regions.² The sex predilection in their tumors is controversial. Some authors have reported an equal sex predilection while some others have reported a slight male preponderance.³ The age distribution reported is from youth to elderly with increased incidence in the fourth, fifth and sixth decades of life.^{4,5} Most cases are unifocal, though rarely multifocal lesions can occur. Most cases are detected while under evaluation for some unrelated pathology. Rarely, patients can present with lesional pain.¹

Intraosseous lipomas may undergo many changes including fat necrosis, dystrophic calcification, cystic degeneration, fibrosis and bone infarction. Diagnosis of an intraosseous lipoma with simple plain x-ray may be difficult, however the presence of intalesional calcification may aid in diagnosis.⁶ MRI is an excellent method for demonstrating fatty tissue, and its primary role in the identification of intraosseous lipomas is to visualize fat within the lesions. On T1- and T2-weighted sequences the matrix content of the lesion shows similar features of those of fat tissue like bone marrow fat and subcutaneous fat. On T2-weighted images, areas of necrosis and cystic structures present high signal.⁹

Milgram et al⁴ proposed three stages based on the histological appearances of intraosseous lipomas. Stage I lesions contain viable mature adipocytes interspersed with fine bony trabeculae. The fat is identical to subcutaneous fat. Stage II lesions develop areas of infarction due to expansion of fat cells within rigid trabeculae. The adipose tissue is partly necrotic with loss of nuclei, and foamy macrophages may be present. Extension of infarction to involve the

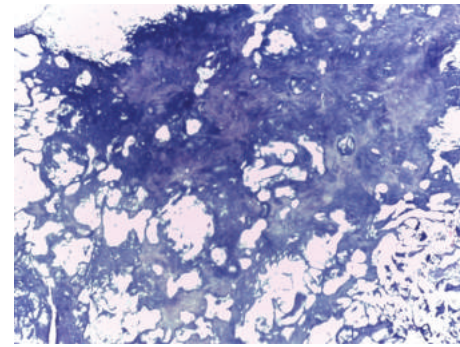


Figure 2: Adjacent foci of infarcted bone (HE stain, X100).

whole lesion leads to a stage III, with necrotic fat, calcified fat, cyst formation and reactive peripheral or central new bone formation, although these features may be seen to a lesser extent in the stage II lesions. The appearances of intraosseous lipomas on simple x-ray and MRI correspond to the pathological staging system. Milgram states that stage I lesions are purely radiolucent with resorption of pre-existing bone and expansion or remodelling in half of all cases. In stage II lesions, localized areas of calcification may be seen and are typically central, but may be peripheral. At stage III reactive ossification around the calcified fat in the outer rim of the lesion is prominent.⁴

The differential diagnoses include bone infarct, unicameral bone cyst, aneurysmal bone cyst, chondromyxoid fibroma, osteoblastoma, giant cell tumor⁴ and bone infarct¹⁰. Furthermore, a heterogeneous group of lesions termed liposclerosing myxofibrous tumours (LSMFT) have been described. These lesions show a variety of histological patterns, similar to conditions such as fibrous dysplasia, non-ossifying fibroma, intraosseous lipoma, simple cysts and bone infarcts.⁹ Therefore correlation with radiology is essential to determine whether a lipoma is actually present.

Most intraosseous lipoma can be managed conservatively. Goto et al⁵ suggested surgical indication of intraosseous lipoma only if the lesion was painful or in case of pathological fracture or necessity for histological diagnosis or need to decrease the risk of malignant transformation. These lesions generally have an excellent prognosis with almost negligible recurrence rates. However, few cases with malignant transformation have been documented.⁷

CONCLUSION

Calcaneal intraosseous lipoma is a benign lesion that may present a diagnostic challenge to those uninitiated in its appearance. But prompt evaluation of such lesions by MRI can prevent misdiagnosis considering its ability to demonstrate the presence of fat within the tumor and hence avoiding unnecessary workup, biopsy and treatment of asymptomatic patients.

REFERENCES

1. Duk Seop Shin, M.D., Eun Seok Kwak, M.D., Joon Hyuk Choi. J. of Korean Orthop. Assoc. 2003;38:526-30
2. Ramos A, Castello J, Sartoris DJ, et al. Osseous lipoma: CT appearance. Radiology. 1985;157:615-9. Crossref
3. Campbell RSD, Grainger AJ, Mangham DC, Begge I, The J and Davies AM: Intraosseous lipoma: report of 35 new cases and a review of the literature. Skeletal Radiol 2003.57:615-9.
4. Milgram JW: Intraosseous lipomas. A clinicopathologic study of 66 cases. Clin Orthop 1988;231:277-302. Crossref
5. Goto T, Kojima T, Ijima T et al: Intraosseous lipoma: a clinical study of 12 patients. J Orthop Sci 2002;7:274-80. Crossref
6. Propeck T, Bullard MA, Lin J, et al. Radiologicpathologic correlation of intraosseous lipomas. AJR Am J Roentgenol. 2000;175:673-8. Crossref
7. Milgram JW. Malignant transformation in bone.lipomas. Skeletal Radiol. 1990;19:347-52. Crossref
8. Barker GR, Sloan P: Intraosseous lipomas: clinical features of a mandibular case with possible etiology. Br J Oral Maxillofac Surg 1986;24:459-63. Crossref
9. Ragsdale BD: Polymorphic fibro-osseous lesions of bone: an almost site specific diagnostic problem of the proximal femur. Hum Pathol 1993;24:505-12. Crossref
10. Richardson AA, Erdmann BB, Beier-Hanratty S, et al: Magnetic resonance imagery of a calcaneal lipoma. J Am Podiatr Med Assoc 1995;85:493-6. Crossref