













ISSN: 2091-2749 (Print)  
2091-2757 (Online)

**Submitted on:** 23 Apr 2024

**Accepted on:** 28 May 2024

<https://doi.org/10.3126/jpahs.v11i1.66374>

## Osteomyelitis of Phalanx and Salvage using the Masquelet Technique

Piyush Giri<sup>1</sup>  , Sushma Kunwar<sup>2</sup>  , Karuna Khadka<sup>2</sup>  , Shrinkhala Pokhrel<sup>2</sup>  , Pratishta Pandey<sup>2</sup>  

<sup>1</sup>Asst. Prof., Dept. of Surgery, <sup>2</sup>MBBS, Intern, Pokhara Academy of Health Sciences, Pokhara, Kaski Nepal

### Abstract

A fingertip has precise functional roles of fine movement, touch, and sensory functions. Its injury majorly hampers not only the functional aspect but also carries great aesthetic significance. Osteomyelitis is a serious bone infection that presents a complex clinical challenge that demands a multidisciplinary approach. The integration of antimicrobial therapy, surgical intervention, and bone reconstruction is often considered the mainstay of treatment. We report a case of osteomyelitis of finger management and bony defect reconstruction using the Masquelet technique for good functional outcome and preservation of the finger.

**Keywords:** Arthrodesis; Finger joint; Osteomyelitis



#### How to Cite:

Giri P, Kunwar S, Khadka K, Pokhrel S, Pandey P. Osteomyelitis of phalanx and salvage using the Masquelet technique. Journal of Patan Academy of Health Sciences. 2024 Apr;11(1):52-55.

#### Correspondence:

Piyush Giri, Dept. of Surgery, Pokhara Academy of Health Sciences, Pokhara, Kaski Nepal Email: [dr.piyushgiri@gmail.com](mailto:dr.piyushgiri@gmail.com)

## Introduction

Osteomyelitis, a severe and often debilitating infection of the bone and can arise from various sources, including bacterial infections, trauma, or surgical interventions, it can be acute or chronic, *Staphylococcus aureus* is the most common organism involved. Treatment involves antibiotics and surgical debridement. Surgical debridement of bone can often result in defects on the bone with increased morbidity.<sup>1</sup>

Osteomyelitis of the phalanges presents a great challenge; it requires thorough treatment and has a high risk of finger function and amputation. An overall incidence of amputation was 39% while those with a history of trauma and wound contamination had a 54% chance of undergoing amputation.<sup>2</sup>

The induced membrane technique also referred to as the Masquelet technique was initially described by A.C. Masquelet in the year 2000 for the reconstruction of losses from the diaphysis of the long bones. It involves two stages, in first stage, segmental bone with infectious tissue is debrided and cement spacer is placed along with stable fixation. Later in the second stage, induced biological chamber is filled with cancellous bone graft.<sup>3</sup>

In spite of its prevalence in the lower limbs, reports and series on successful use of Masquelet therapy to treat bone loss secondary to trauma, osteomyelitis or nonunion are also reported in the upper extremities.<sup>4,5</sup>

We present a case of osteomyelitis of the left long finger of the middle and distal phalanx treated by the Masquelet technique.

## Case Report

A 35-year-old male presented to our center with a reported history of trauma to his left middle finger one and half months ago with pain and swelling at the same site and painful range of motion (ROM), diagnosis of osteomyelitis of middle phalanges of left long finger was made.

The patient underwent a thorough soft tissue debridement, removal of sequestrum, antibiotic spacer insertion, and internal fixation with Kirschner wire (K-wire) during the first stage of the procedure. It consists of a mixture of polymethylmethacrylate with ceftriaxone 500 mg and Gentamicin 160 mg. He underwent the second stage surgery at 14 weeks, with the removal of antibiotic spacer, placement of iliac crest cancellous bone graft, arthrodesis of the

Distal Interphalangeal (DIP) joint, and fixation with K-wire. Physiotherapy was started on the second postoperative day and the patient was discharged.

Full ROM of the Proximal Interphalangeal (PIP) joint of the middle finger was achieved at three months after surgery. The patient was pleased with the appearance of his finger, which was 3 mm longer than the other side and was aligned linearly to its neighboring digits. Intraoperative radiographic and alignment images of the finger and postoperative status are given below, Figure 1 to Figure 3.

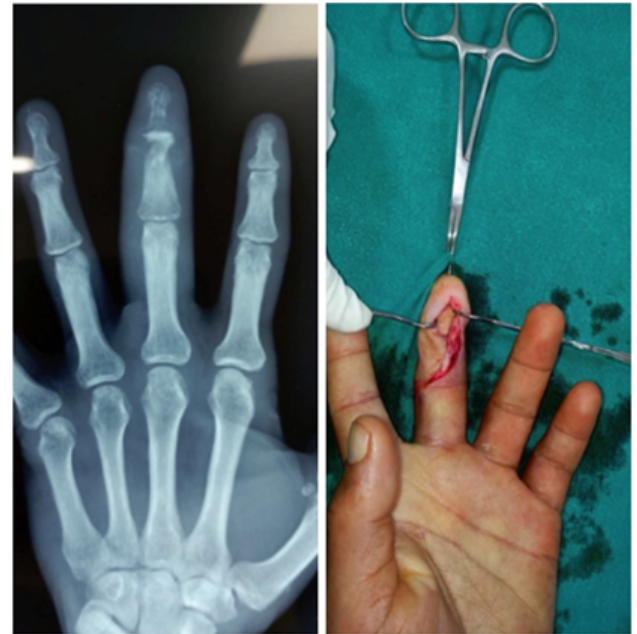

Figure 1. X-ray depicting osteomyelitis of middle phalanx and DIP joint of the left long finger, debridement and replacement of bone cement

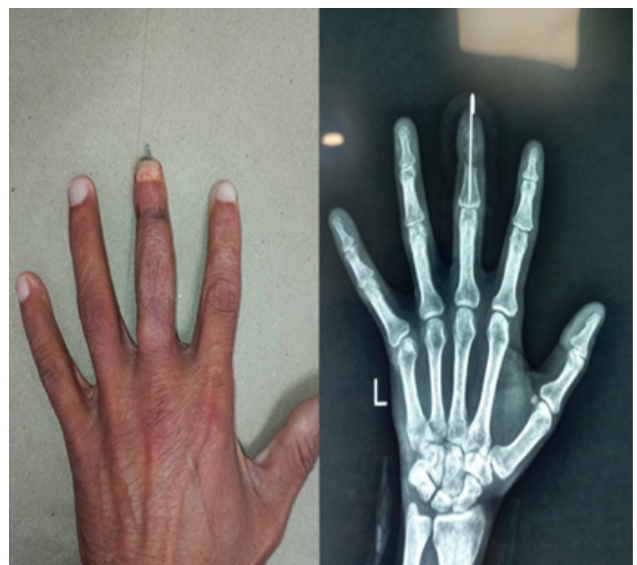
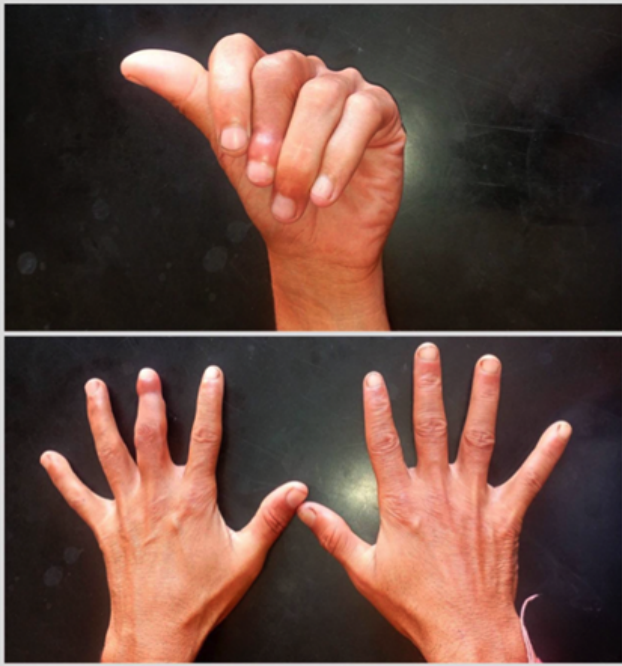
Figure 2. Bone graft and K-wire in situ at 3 months postoperative



**Figure 3. Functional status finger at 3 months post-operative period**

### Discussion

The finger is an essential appendage and pivotal part of the human body proficient in performing minute detailed activities, functional handwork jobs, as well as communication and aesthetic appearance. The Masquelet technique has an advantage of limb salvation over amputation preserving the length of the finger, enhancing the aesthetic appearance, and reducing the need for prolonged intravenous antibiotics for the management of osteomyelitis. In addition, the simplicity and reproducibility of the induced membrane technique, it is an alternate reconstruction procedure to other traditional graft or vascularized graft techniques.<sup>3</sup>

The primary principle of the Masquelet technique is inducing pseudo membrane by the physiological foreign-body reactions surrounding the polymethylmethacrylate (PMMA) spacer.<sup>6</sup> Pelissier et al have demonstrated the additional role of the induced membrane in the secretion of growth factors such as vascular endothelial growth factor (VEGF), transforming growth factor beta-1 (TGFB1) and osteo-induction factors such as bone morphogenic protein-2 (BMP2) involved in bone healing.<sup>7</sup>

In our case, we used an autograft harvested from iliac crest. The source of cortico-cancellous bone graft can be from iliac crest or medial tibia, femur, fibula or allograft or bone substitute such as beta-tricalcium phosphate.<sup>1,8</sup>

In seven patients, where a four-week interval between spacing and bone graft for early rehabilitation was used, Toyama et al used a membrane-induced cement technique to treat osteomyelitis of the phalanges. The optimal time to perform the second stage of surgery was 4 to 12 weeks in different literature.<sup>2,4,9,10</sup> However in our case, the second stage of bone grafting was performed 14 weeks after the first surgery due to delayed follow-up by the patient based on the evidence that osteogenic properties of the membrane are retained for up to 6 months.<sup>11</sup> In a similar case of segmental bone loss due to trauma, Moris et al reported a bone union of 89% in traumatic bone loss or nonunion followed by trauma of the phalanx treated with the Masquelet technique.<sup>12</sup> In a case series of 13 digits treated with single-stage antibiotic cement spacers for osteomyelitis requiring joint involvement and segmental bone removal to salvage the digit as Aimé et al reported the procedure was successful in treating ten and salvage all thirteen digits.<sup>13</sup>

The recurrence rate of infection after treatment of osteomyelitis is found to be as high as 10-15%.<sup>14</sup> Infection following the Masquelet technique is one of the complications and should be managed by initial tissue debridement coupled with antibiotic eluting spacer. The PMMA may lead to bone necrosis, and soft tissue damage due to exothermic reactions which limits its combination with heat-sensitive antibiotics as well as systemic allergic risk. In recent years, the possibility of single-staged surgery is being studied by using calcium sulfate over PMMA due to its biodegradability, biocompatibility, osteoconductivity and non-exothermic reactions.<sup>11,15</sup>

### Conclusion

Masquelet technique is a simple cost-effective method with a high rate of bone union and among different techniques for bone grafting, it can be safely used in the treatment of osteomyelitis in salvaging fingers.

### Acknowledgement

None

### Conflict of Interest

None

### Funding

None

### Author Contribution

Concept, design, planning: PG, SK, KK, SP, PP; Literature review: PG, SK, KK, SP, PP; Data collection: SK, KK; Data analysis: PS, SK, KK, SP, PP; Draft manuscript: PG, SK, KK; Revision of draft: PS, SK, KK, SP, PP; Final manuscript: PS, SK, KK, SP, PP; Accountability of the work: PS, SK, KK, SP, PP.

### References

1. Careri S, Vitiello R, Oliva MS, Ziranu A, Maccauro G, Perisano C. Masquelet technique and osteomyelitis : innovations and literature review. *Eur Rev Med Pharmacol Sci.* 2019;23(Suppl. 2):210-6. DOI
2. Pruzansky ME, Lee Y, Pruzansky J. Masquelet Technique for Phalangeal Reconstruction and Osteomyelitis. *Tech Hand Up Extrem Surg.* 2021 Mar;25(1):52-5. DOI
3. Tabib W, Haddad H. Management of second metacarpal chronic osteomyelitis by induced membrane technique. *Case Reports Plast Surg Hand Surg.* 2018;5(1):49-53. DOI
4. Brush PL, Toci GR, Semenza NC, Fletcher D, Beredjikian P, Aita D. Masquelet Technique and Arthrodesis for Digit Salvage of the Finger in Traumatic Bone Loss and Osteomyelitis: A Case Report. *Cureus.* 2022 Jul 12;14(7):e26773. DOI
5. Hara A, Yokoyama M, Ichihara S, Kudo T, Maruyama Y. Masquelet technique for the treatment of acute osteomyelitis of the PIP joint caused by clenched-fist human bite injury: A case report. *Int J Surg Case Rep.* 2018;51:282-7. DOI
6. Wang P, Wu Y, Rui Y, Wang J, Liu J, Ma Y. Masquelet technique for reconstructing bone defects in open lower limb fracture : Analysis of the relationship between bone defect and bone graft. *Injury.* 2021 Apr;52(4):988-95. DOI
7. Pelissier P, Bollecker V, Martin D, Baudet J. Foot reconstruction with the “bi-Masquelet” procedure. *Ann Chir Plast Esthétique.* 2002 Aug;47(4):304–7. DOI
8. Biau DJ, Pannier S, Masquelet AC, Glorion C. Case Report: Reconstruction of a 16-cm Diaphyseal Defect after Ewing’s Resection in a Child. *Clin Orthop Relat Res.* 2009 Feb;467(2):572-7. DOI
9. Toyama T, Hamada Y, Horii E, Kinoshita R, Saito T. Finger Rescue Using the Induced Membrane Technique for Osteomyelitis of the Hand. *J Hand Surg Asian Pac Vol.* 2021 Jun;26(2):235-9. DOI
10. Wong TM, Lau TW, Li X, Fang C, Yeung K, Leung F. Masquelet Technique for Treatment of Posttraumatic Bone Defects. *Sci World J.* 2014;2014:1-5. DOI
11. Ahmed H, Shakshak M, Trompeter A. A review of the Masquelet technique in the treatment of lower limb critical-size bone defects. *Ann R Coll Surg Engl.* 2023 Jun 27;1-8. DOI
12. Moris V, Loisel F, Cheval D, See LA, Tchurukdichian A, Pluvy I, et al. Functional and radiographic evaluation of the treatment of traumatic bone loss of the hand using the Masquelet technique. *Hand Surg Rehabil.* 2016 Apr;35(2):114-21. DOI
13. Aimé VL, Kidwell JT, Webb LH. Single-Stage Treatment of Osteomyelitis for Digital Salvage by Using an Antibiotic-Eluting, Methylmethacrylate Joint-Spanning Spacer. *J Hand Surg Am.* 2017 Jun;42(6):480.e1-480.e7. DOI
14. Wentao C, Xinlong Z, Shi Y, Zhao W. Reducing the recurrence of infection after the application of Masquelet technique for osteomyelitis. *Chinese J Tissue Eng Res.* 2022;26(28):4546–52. DOI
15. Jiang N, Qin CH, Ma YF, Wang L, Yu B. Possibility of one-stage surgery to reconstruct bone defects using the modified Masquelet technique with degradable calcium sulfate as a cement spacer: A case report and hypothesis. *Biomed Reports.* 2016 Mar;4(3):374-8. DOI