



ISSN: 2091-2749 (Print)
2091-2757 (Online)

Correspondence

Dr. Hou Guangjun
Children's Hospital, Zhengzhou
University, Zhengzhou, China
Email: hougj66608@163.com
drjaywufei@hotmail.com

Peer Reviewers

Prof. Dr. Nabees MS Pradhan
Patan Academy of Health
Sciences

Asst. Prof. Dr. Ashis Shrestha
Patan Academy of Health
Sciences

Submitted

11 Aug 2019

Accepted

22 Nov 2019

How to cite this article

Zhou Liang, Hou Guangjun,
Geng Xianjie, Zhang Xianwei,
Jay Shah. Laparoscopic surgery
for intestinal obstruction in
children due to water
absorbing gel beads. Journal of
Patan Academy of Health
Sciences. 2019Dec;6(2):12-7.

laparoscopic surgery for intestinal obstruction in children due to water absorbing gel beads

Zhou Liang¹, Hou Guangjun¹, Geng Xianjie¹, Zhang Xianwei¹, Jay Shah²
¹General Surgery, Children's Hospital Affiliated to Zhengzhou University, China
²Visiting Prof. of Surgery, Patan Hospital, Patan Academy of Health Sciences, Lalitpur, Nepal

Abstract

Introductions: Super absorbent polymer gel bead (SAPGB) is increasingly available as toys for children. When ingested it swells by absorbs water and leads to acute intestinal obstruction. Diagnosis and surgery is challenging as its radiolucent, fragile and slippery. We present outcome of our innovative technique of stabilization and removal SAPGBs by laparoscopy minimal invasive surgery (lap-MIS).

Methods: This retrospective analyse of outcome of lap-MIS in intestinal obstruction caused by ingestion of foreign body, the SAPGBs, in children who were managed at Children's Hospital Affiliated to Zhengzhou University, China. The outcome variables included removal of SAPGBs, length of hospital stay and postoperative occurrence of anastomotic leak, wound infection, wound dehiscence, re-surgery, or mortality.

Results: There were 15 children, male 9 (60%), average age 2 years, and duration of ingestion of SAPGBs 1.5 days (range 2-4 days), parents gave history of accidental ingestion in 6 (40%). All children had uneventful postoperative recovery after lap-MIS removal of foreign body with no wound infection, anastomotic leak, re-surgery or mortality. Average hospital stay was 4 days (range 3 to 5 days).

Conclusions: We had successful outcome lap-MIS with our innovative technique to stabilize and extract foreign bodies, the super water absorbent gel beads, ingested by children.

Keywords: children, foreign body, gastrointestinal obstruction, laparoscopy minimal invasive surgery, super absorbent polymer gel beads

Introductions

Ingestion of foreign body (FB) in preschool children below 6 years of age is common, and in majority of cases up to 90% passes spontaneously, and about 10% needs endoscopic removal, less than 1% who develop complications, for example, intestinal obstruction requires surgical intervention.¹

The 'super absorbent polymer gel bead' (SAPGB), can retain large quantity of water up to 100 times of their weight and expand in size up to 200 times, is used in agriculture, floral decoration, diapers, sanitary pads and recently as children's toys in attractive shape and colors. The gel beads become slippery and fragile when wet in water and usually reaches maximum size after 12 hours of submersion in water.² When swallowed, the slippery beads pass through gastrointestinal tract (GIT) until it absorbs water and gets enlarged rapidly causing acute intestinal obstruction, morbidity and occasionally mortality, especially in younger children below 2 years of age.²⁻⁷

The laparoscopic minimally invasive surgery (lap-MIS) surgery is challenging to locate and retrieve the fragile slippery gel beads. Here we summarize our innovative technique of successful lap-MIS as a feasible and safe alternative to open surgery in children for GIT obstruction due to SAPGBs.

Methods

This retrospective analysis of hospital electronic database includes children managed for acute GIT obstruction caused by ingestion of SAPGBS during five years period from February 2013 to March 2018, at Zheng Zhou Children Hospital, a tertiary care children hospital affiliated to Zheng Zhou University. The study was approved from the hospital authority. The study variables analyzed were history of ingestion (accidental, no clear history, denial), duration of ingestion, sign and symptoms (vomiting, abdomen distension, dehydration), radiological findings (abdominal X-ray, abdomen ultrasonography-USG),

provisional diagnosis, surgical treatments, postoperative complications, followup and outcome. Followup was done in outpatient department (OPD) at 7 days and 6 months. The outcome measurement included complete removal of SAPGBs, days of hospital stay and postoperative complications (anastomotic leak, wound infection, wound dehiscence, re-surgery), or mortality.

After routine preoperative workup and symptomatic management for intestinal obstruction, surgery was performed under general anesthesia endotracheal intubation. A 10-mm camera port was established through umbilicus, and two 5 mm working ports on both left and right iliac fossa. Our technique included five steps: 1) Foreign body localization: spherical foreign bodies located in small intestine, visible at the junction of intestinal dilatation proximally and collapsed distally, and further confirmed by palpation with grasper forceps; 2) Fixing foreign bodies, Figure 1: to stabilize the foreign body and prevent it from migration in the intestine, on both proximal and distal to the foreign body, intestinal lumen was occluded with loosely tied stay suture. A needled thick silk thread (USP 2) was passed on the mesenteric border just outside the intestinal wall and tied loosely to occlude the lumen to fix the FB, taking care not to injure the intestine (tying loosely) and vessels (while passing needle). The cut-end of suture were kept at least 10 cm long for later use; 3) FB removal: umbilical port incision enlarged, intestinal segment containing FB pulled out holding the stay sutures, longitudinal enterotomy incision on the antimesenteric border was made to remove FB; 4) Closer of enterotomy: enterotomy was closed transversely in single layer interrupted 5-0 polyglycolic acid (Vicryl®) absorbable sutures, and bowel returned in to the peritoneal cavity; 5) closer of abdomen port sites: with 2-0 absorbable suture

Post operatively children were managed as per hospital protocol of routine care with nasogastric decompression, IV fluid, antibiotic, and gradual oral feeding, followup at 7 days and 6 months.

Results

There were 15 children with acute GIT obstruction due to SAPGBs who were successfully managed with lap-MIS. Male were 9 (60%), female 6 (40%), average age 2 years

(range 6 to 36), and duration of FB ingestion of SAPGBs 1.5 days (range 2-4 days), Table 1.

Parents gave history of accidental ingestion in 6 (40%) children, 5 (33.3%) denied ingestion, and 4 (26.7%) were not sure of ingestion but

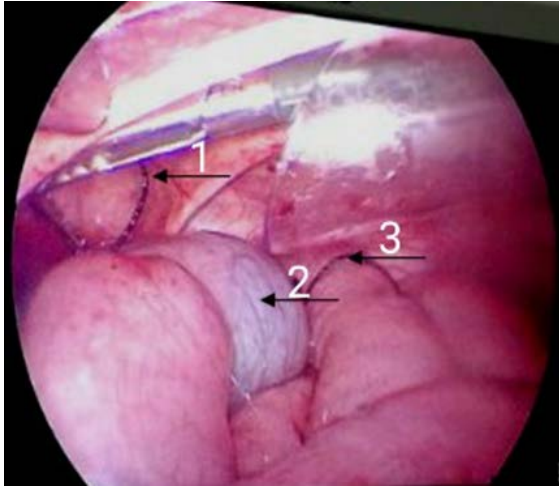


Figure 1. Arrows 1 and 3: loosely tied stay sutures on proximal and distal of FB (arrow 2) occluding small intestine lumen to prevent migration and facilitate removal of SAPGB

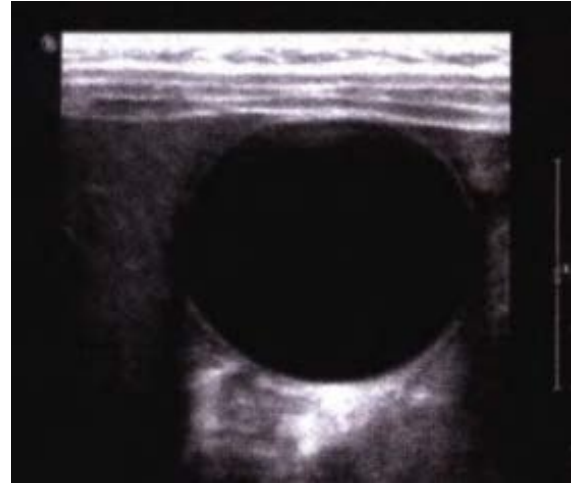


Figure 2. Color Doppler Ultrasound of abdomen, round cystic dark area represents SAPGB in small bowel



Figure 3. Water-absorbing gel beads look like candy so children may be tempted to swallow them.¹⁸

mentioned having SAPGBs at home. All the children presented with abdominal distension and vomiting and two had severe dehydration.

Abdominal plain film showed features of obstruction. The USG mentioned FB in 11 (73.3%) (Figure 2) and abdominal cysts in 2 (13.3). Color Doppler performed in 2 cases was diagnostic of SAPGBs. Before surgery, 9 cases were diagnosed of SAPGBs by USG, and 6 cases were confirmed during operation.

Postoperative recovery was uneventful. There was no anastomotic leak, re-surgery, wound infection, wound dehiscence; and no mortality. Average hospital stay was 4 days (range 3 to 5 days). There was no complain noted during followup in outpatient department at 7 days, and 6 months after surgery.

Discussions

Our findings shows lap-MIS with this innovative technique of stabilizing and removal of the FB, friable slippery SAPGBs, is technically easy with good outcome. In open laparotomy intestinal decompression is required before closing the abdomen which may increase the chance adhesive bowel obstruction.

In our study, all 15 children recovered well, and did not require re-laparotomy. There is report of intestinal obstruction by SAPGBs in a 15 months child required re-laparotomy during the same admission for other missing gel beads.⁷

Similar to our findings, plain abdomen X-ray helps show presence of intestinal obstruction but do not give information on SAPGBs because these FB are radiolucent.⁸ In contrast, USG is helpful to identify these FB showing cystic lesion with double wall sign, a crucial sign to avoid unnecessary additional imaging and harmful radiation in children.^{4,9}

All children in our study presented with features of GIT obstruction due to ingestion of

SAPGBs underwent Lap-MIS. However, asymptomatic stable children, with normal laboratory, X-ray, and ultrasound findings can be managed without surgery as reported in a retrospective chart analysis of 21 children during a 10-year period, 6 were hospitalized and 15 observed as outpatients. The average age 7.2 years (range 2-15), male 14 (67%), and presented with history of 7 h to 5d of ingestion of SAPGBs. All 21 children recovered without surgery or other procedures.¹⁰

There was no anastomotic leak or mortality in our series. One study reports a children died due to sepsis after surgery for intestinal obstruction due to SAPGBs^{4,6} A 6 months infant with intestinal obstruction of jejunum due to ingestion of decorative SAPGBs was re-operated for anastomotic disruption on 6th postoperative day, developed septicemia, and succumbed after 2 days of second operation.⁴ Complications are more common in younger children below 2 years of age¹¹ The ages of all children who required surgery due to small bowel obstruction were between 6 and 18 months.^{4,11-13}

The SAPGBs are nontoxic, biodegradable polymer beads available in different shapes sizes and colors with reported case of poisoning.¹⁰ However, its use is increasingly becoming a serious problem due to intestinal obstruction requiring surgery, occurrence of various morbidities and rarely mortality due to complications.^{5,10,14}

There is lack of official mandate in China for the access, sell and use of these colorful gel beads to children. In several countries, the sale of some or all brands of SAPGBs are restricted or prohibited for sell to children in grocery and stationery stores.^{5,11,14} The colorful water absorbing polymer balls originally designed for the florist industry were found to be purchased and sold as a tactile toy which may look like attractive lollies to children causing intestinal obstruction when swallowed. For safety fears, the Australian government ordered recall of these SAPGBs.¹⁵ Several countries, like Italy and Malaysia, Turkey have banned these super-absorbent polymer balls.^{10,16} The

children like to play with the water absorbing beads which are colorful, attractive, and magically grow in size when placed in water, giving tactile feel of gel-like balls and candies endangering the child when swallowed or put in body orifices.¹⁷

The non-toxic tiny hard plastic beads have several names like 'water balls, jelly beads, water orbs, hydro orbs, polymer beads and gel beads' and can grow more than 200 times in size by absorbing water (Figure 3) to cause obstruction when swallowed, making child refuse to eat, drool, vomit with abdominal pain and swelling prompting. The U.S. Consumer Product Safety Commission (CPSC) issued a voluntary recall of several types of water-absorbing balls, beads and toys shaped like fruit and animals sold in several colors of 'blue, green, orange, purple, red, yellow or clear colors', even though the packaging contained warning 'not to use without adult supervision'.¹⁸⁻²⁰

Conclusions

Our study shows the laparoscopic minimal invasive surgery with the innovative technique to stabilize and retrieve the ingested slippery fragile super absorbent polymer gel beads had successful outcome without conventional laparotomy for the intestinal obstruction in children. The increasing occurrence of intestinal obstruction due to water absorbing gel beads in children requires attention by all stakeholders, especially government legislation for its marketing and access to children.

Conflict of interests

None

Fundings

None

References

1. Birk M, Bauerfeind P, Deprez PH, Häfner M, Hartmann D, Hassan C, Hucl T, Lesur G, Aabakken L, Meining A. Removal of foreign bodies in the upper gastrointestinal tract in adults; European Society of Gastrointestinal Endoscopy (ESGE) Clinical Guideline. *Endoscopy*. 2016;48(5):489-96. DOI PubMed GoogleScholar
2. Fuger M, Desmoulins C, Dunlop NK, Gobbo F, Blakime P, Chéron G. Bowel obstruction due to ingestion of a water-absorbing bead. *Arch Pediatr*. 2018;25(2):136-8. DOI PubMed GoogleScholar
3. Kramer RE, Lerner DG, Lin T, Manfredi M, Shah M, Stephen TC, Gibbons TE, Pall H, Sahn B, McOmber M, Zacur G, Friedlander J, Quiros AJ, Fishman DS, Mamula P; North American Society for Pediatric Gastroenterology, Hepatology, and Nutrition Endoscopy Committee. Management of ingested foreign bodies in children: a clinical report of the NASPGHAN Endoscopy Committee. *J Pediatr Gastroenterol Nutr*. 2015;60(4):562-74. DOI PubMed GoogleScholar
4. Mirza B, Sheikh A. Mortality in a case of crystal gel ball ingestion: an alert for parents. *APSP J Case Rep*. 2012;3:6. PubMed GoogleScholar Weblink
5. Cairns R, Brown JA, Buckley NA. Dangerous toys: the expanding problem of water-absorbing beads. *Med J Aust*. 2016;205(11):528. DOI PubMed GoogleScholar Weblink
6. Lip HT, Huei TJ, Vellusamy VM. Morbidity in an Infant by superabsorbent polymer ingestion. *APSP J Case Rep*. 2017;8(5):33. DOI GoogleScholar Weblink
7. Mohamed A, Qoura H, Alshuili I, Karim M, Abushosha A, Abdulsattara M, Hassan M. J. Bowel obstruction by ingestion of superabsorbent polymer balls. *Journal of Pediatric Surgery Case Reports*. *Pediatr Surg Case Rep*. 2019;41:27-9. DOI GoogleScholar
8. Jackson J, Randell KA, Knapp JF. Two year old with water bead ingestion. *Pediatr Emerg Care*. 2015;31(8):605-7. DOI PubMed GoogleScholar
9. Faizah MZ, Soon YY, Che Zubaidah CD, Mohd Yusuf A, Dayang AA. Ultrasound diagnosis of crystal jelly ball ingestion causing intestinal obstruction. *Austin J Radiol*. 2016;3(2):1046. DOI GoogleScholar Weblink

10. Mehmetoğlu F. A retrospective 10-year analysis of water absorbent bead Ingestion in children. *Emerg Med Int.* 2018;2018:5910527. DOI PubMed GoogleScholar
11. Muthukumar J, Vivek S, Intestinal obstruction due to accidental ingestion of hygroscopic foreign body, *Indian Pediatr.* 2014;51(12):1022-3. PubMed GoogleScholar Weblink
12. Pham HD, Taylor LA. Small bowel obstruction due to ingested superabsorbent beads. *J Ped Surg Case Reports.* 2015;3(5):190-1. DOI GoogleScholar Weblink
13. Mirza B, Ijaz L, Sheikh A. Decorative crystal balls causing intestinal perforation. *J Indian Assoc Pediatr Surg.* 2011;16(3):106-7. DOI PubMed GoogleScholar
14. Darracq MA, Cullen J, Rentmeester L, Cantrell FL, Ly BT. Orbeez: the magic water absorbing bead – risk of pediatric bowel obstruction? *Pediatr Emerg Care.* 2015;31(6):416-8. DOI PubMed GoogleScholar
15. ABC News. Expandable polymer water balls being sold as toys in WA recalled over child safety fears. ABC News [internet]. 2018 Nov 9; News. Weblink
16. NBC Miami. Consumer reports: super absorbent toy ball caution. NBC Miami [internet]. 2013 Apr 22; News. Weblink
17. Guinto-Ocampo H. The dangers of water absorbing beads. *The Philadelphia Inquirer* [internet]. 2016 Nov 3; inquirer.com. Weblink.
18. Koriath T. Parent plus: water-absorbing beads can be harmful if swallowed, put in ear. *AAP News & Journals Gateway* [internet]. 2016 Mar 22; AAP News. Weblink
19. Cpsc.gov. United States Consumer Product Safety Commission. Be amazing! Toys recalls monster science and super star science colossal water balls due to serious ingestion hazard [internet]. 2013; Recalls. Weblink
20. Maas R. U.S. CPSC recalls more water expanding toys due to ingestion risk. *Aboutlawsuits.com* [internet]. 2013 Dec 13. Weblink